

Available online at www.sciencedirect.com

ScienceDirect

journal homepage: <http://Elsevier.com/locate/radcr>

Head and Neck

Large intramuscular lipoma of the tongue

Kara Fitzgerald^a, Paul J. Sanchirico MD^b, David C. Pfeiffer PhD^{c,*}

^a WWAMI Medical Education Program, University of Washington School of Medicine, 1959 NE Pacific St, Seattle, WA 98195, USA

^b St Joseph Regional Medical Center, 415 6th St, Lewiston, ID 83501, USA

^c WWAMI Medical Education Program and Department of Biological Sciences, University of Idaho, 875 Perimeter Dr, Moscow, ID 83844-3051, USA

ARTICLE INFO

Article history:

Received 2 December 2017

Accepted 4 January 2018

Available online 3 February 2018

Keywords:

Oral lipoma

Tongue

Intramuscular lipoma

Infiltrating lipoma

ABSTRACT

We describe a case of a 57-year-old man referred to an oral maxillofacial surgeon for a nontender, large intramuscular tongue mass. A computed tomography scan with contrast showed a homogenous right tongue intramuscular fatty mass measuring 3.8 cm × 2.8 cm in the axial dimension and 2.2 cm in the craniocaudal dimension. Histologic examination revealed multiple lobulated sections of mature adipocytes and occasional entrapped skeletal muscle fibers. The final pathologic diagnosis was intramuscular lipoma. Although lipomas account for approximately 50% of all soft tissue neoplasms, intramuscular (infiltrating) lipoma of the tongue is exceedingly rare.

© 2018 the Authors. Published by Elsevier Inc. under copyright license from the University of Washington. This is an open access article under the CC BY-NC-ND license (<http://creativecommons.org/licenses/by-nc-nd/4.0/>).

Introduction

Lipoma is a common benign mesenchymal tumor, accounting for 50% of all soft tissue neoplasms [1,2]. It exhibits lobular growth of mature adipocytes with demarcated borders and is often enclosed within a fibrous capsule [2]. Conventional lipoma arises most commonly in subcutaneous tissue; however, a deep-seated subtype may develop within skeletal muscle, where it is termed an intramuscular (infiltrating) lipoma. The latter subtype is relatively uncommon, accounting for less than 1% of all lipomas [3]. Histologically, intramuscular lipoma displays mature adipocytes that often

irregularly infiltrate and entrap muscle fibers. The muscle fibers may show evidence of atrophy and in many places the adipocytes completely exclude muscle fibers [1,4]. Tumor vasculature consists mainly of capillaries and is often inconspicuous because of compression by surrounding adipocytes [4–6].

Oral lipomas in general are uncommon, representing approximately 1%–5% of all benign neoplasms of the oral cavity [7–12]. Intramuscular lipoma accounts for just 3%–7% of these cases, making intramuscular lipoma in this region exceedingly rare [12,13]. Here, we describe an intramuscular lipoma of the tongue, initially identified and defined through computed tomography (CT) scan.

Competing Interests: The authors have declared that no competing interests exist.

* Corresponding author.

E-mail address: dpfeiffer@uidaho.edu (D.C. Pfeiffer).

<https://doi.org/10.1016/j.radcr.2018.01.014>

1930-0433/© 2018 the Authors. Published by Elsevier Inc. under copyright license from the University of Washington. This is an open access article under the CC BY-NC-ND license (<http://creativecommons.org/licenses/by-nc-nd/4.0/>).

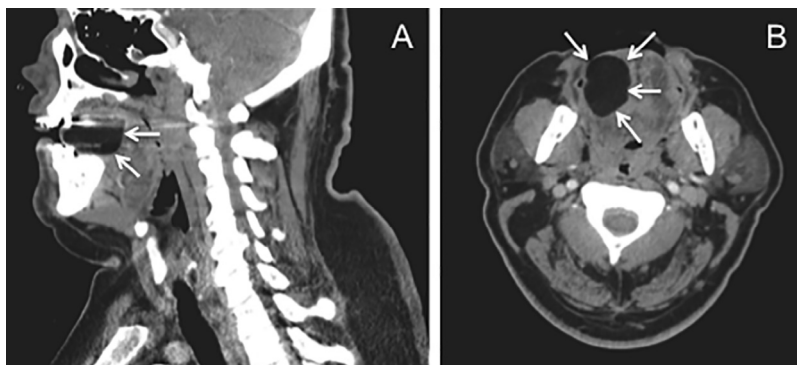


Fig. 1 – CT images of a 57-year-old male. (A) Sagittal and (B) axial scans demonstrating the large, low attenuation lipomatous mass (arrows) within the tongue. CT, computed tomography.

Case report

A 57-year-old Caucasian male was referred to an oral maxillofacial surgeon by his primary care physician because of a nontender mass in the right lateral side of his tongue. The patient had not previously noticed the mass and did not complain of any functional impairment. Physical examination by the oral surgeon revealed tongue swelling, but other aspects of the examination were unremarkable. The patient's personal and family history were also unremarkable. The preliminary differential diagnosis was determined to be angioedema of the tongue, glandular cell tumor, or dermoid cyst. The surgeon ordered a CT scan with contrast of the tongue, head, and mandible, which was performed at a local hospital, where we encountered the patient in the radiology department.

A CT scan showed a homogeneous right tongue intramuscular fatty mass, measuring 3.8 cm × 2.8 cm in the axial dimension and 2.2 cm in the craniocaudal dimension (Fig 1). The average density of the mass was -100 Hounsfield units (HU). The impression of the CT was an intramuscular lipoma of the tongue.

The patient had the mass surgically resected and tissue was sent for pathology analysis. The resected ovoid fatty tissue fragment was serially sectioned; it revealed pale yellow, homogeneous, smooth surface sections. Measurements were 4.4 cm × 3.2 cm × 2.2 cm. There was no hemorrhage or areas of necrosis. Microscopic examination revealed multiple lobulated sections of mature, univacuated adipocytes of relatively uniform size and shape with occasional entrapped skeletal muscle fibers. There was no evidence of hyperchromasia, pleomorphism, or multinucleation of adipocytes and no evidence of lipoblasts (Fig 2). The histopathology was consistent with the final diagnosis of intramuscular lipoma.

The postoperative period was uneventful. Verbal follow-up was conducted at 10 months and the patient reported no signs or symptoms of recurrence. The patient's tongue function and appearance are normal. Although there was no overt evidence of lipoblastic atypia at the time of the surgical resection, this lesion may locally recur.

Discussion

The patient presented in this report is a 57-year-old male who was diagnosed with an intramuscular lipoma in the tongue. Intramuscular lipoma is an uncommon subtype of lipoma that typically occurs in the large muscles of the trunk and extremities [1,14,15]. Intramuscular lipoma in the tongue is particularly rare [16-18], making this case noteworthy.

The etiology of intramuscular lipoma remains unclear. McTighe and Chernev [4] point to similarities with other lipoma subtypes and suggest intramuscular lipoma likely represents a true neoplasm directly originating from multipotent mesenchymal cells. Others have suggested trauma, chronic

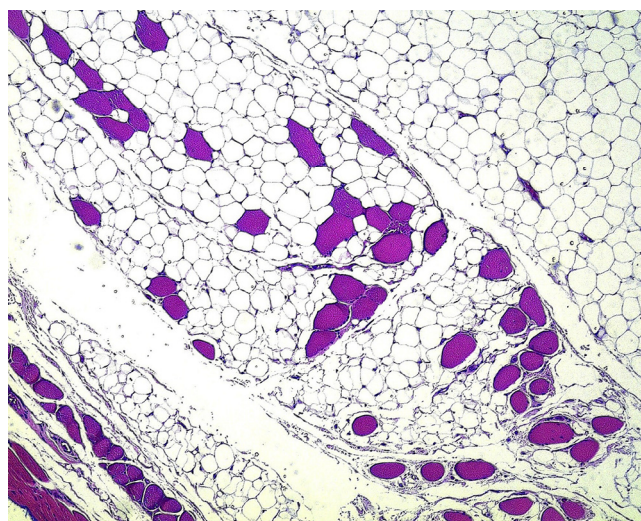


Fig. 2 – Histopathology of the intramuscular lipoma (hematoxylin-eosin). Adipocytes are seen infiltrating the skeletal muscle of the tongue and entrapping muscle fibers. The tumor displays mature, univacuated adipocytes of fairly uniform size and shape. No lipoblasts are seen. Original magnification 100×.

Download English Version:

<https://daneshyari.com/en/article/8825097>

Download Persian Version:

<https://daneshyari.com/article/8825097>

[Daneshyari.com](https://daneshyari.com)