ARTICLE IN PRESS

Radiology Case Reports ■■ (2017) ■■–■■

Available online at www.sciencedirect.com

ScienceDirect

journal homepage: http://Elsevier.com/locate/radcr

Interventional Radiology

Successful sclerotherapy of a recurrent, benign parotid cyst

William Wong MS IV, Mohammed F. Loya MD, Alexander Martynov MD, Salman S. Shah MD, Dean Berman DO*

Department of Vascular and Interventional Radiology and Department of Head and Neck Surgery, NuHealth-Nassau University Medical Center, 2201 Hempstead Turnpike, East Meadow, NY 11554 USA

ARTICLE INFO

Article history:
Received 13 May 2017
Received in revised form 26 August 2017
Accepted 5 September 2017
Available online

Keywords:
Parotid cyst
Interventional radiology
Sclerotherapy
Ultrasound
ENT

ABSTRACT

Benign parotid lesions can grow to be a cosmetic deformation with psychological sequelae for a patient. Although surgical resection is the treatment of choice, cyst aspiration has also been attempted. This, however, has been shown to recur, requiring repeat intervention. An alternative therapeutic method not as widely recognized, but which has been reported to be both effective and less invasive than surgery for treating parotid cyst lesions, is sclerotherapy. Here we describe a report of a patient with a benign, localized, cystic neck mass refractory to 2 trials of fine needle aspiration. After the patient refused surgical resection, a trial of sterile ethanol sclerotherapy was performed. Our patient tolerated the procedure well with a significant reduction in the size of the lesion.

© 2017 the Authors. Published by Elsevier Inc. under copyright license from the University of Washington. This is an open access article under the CC BY-NC-ND license (http://creativecommons.org/licenses/by-nc-nd/4.0/).

Case report

A 78-year-old man with a medical history of adenosquamous carcinoma of the lung (status post left upper lobectomy), prostate cancer (on hormone therapy), hypertension, and renal insufficiency presented with a localized left neck mass in the parotid region. Upon palpation, the mass was nontender, firm, and multilobulated. As per family, the mass had been present for 5 years, and the patient had refused surgical resection of the mass due to the risk of nerve damage. Three years ago, a fine needle aspiration was performed at an outside institution, reducing the size of the mass. At the time, pathology and infectious disease did not identify malignant features and infectious processes, respectively. The patient then presented to our ear, nose, and throat clinic with the complaint that the size of the mass has been increasing over the past few weeks. The patient denied pain, constitutional symptoms, or any recent illness. Patient again refused surgical intervention and requested a reaspiration of the mass. An unenhanced computed tomography scan demonstrated an $8.0 \times 5.2 \times 6.5$ cm multilobulated, cystic mass involving the superficial lobe of the left parotid gland (Fig. 1A and B). Four days after the initial visit, 60 mL yellowish, serosanguinous fluid was aspirated by the ear, nose, and throat surgeon. Within a week, the patient stated he noticed the mass slowly enlarging. The parotid mass was measured to be approximately 12×10 cm (Fig. 2). The patient continued to refuse complete excision of the mass,

Competing Interests: The authors have declared that no competing interests exist.
Consent: Written informed consent was obtained from all of the patients for publication of this case and any accompanying images.

* *Corresponding author.*
E-mail address: wwong05@nyit.edu (W. Wong).

https://doi.org/10.1016/j.radcr.2017.09.001

1930-0433/© 2017 the Authors. Published by Elsevier Inc. under copyright license from the University of Washington. This is an open access article under the CC BY-NC-ND license (http://creativecommons.org/licenses/by-nc-nd/4.0/).

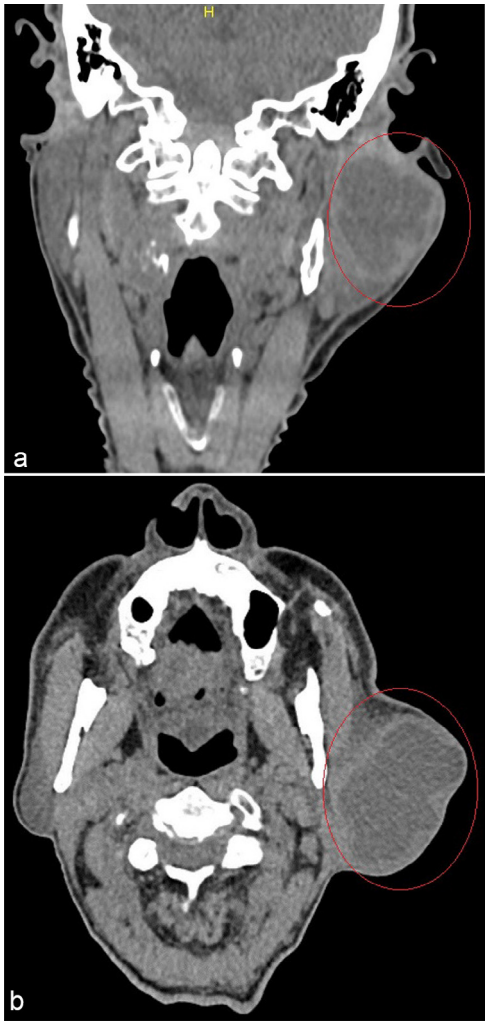

Fig. 1 – Noncontrast coronal (A) and axial (B) computed tomography demonstrated a cystic mass (red circle) in the left parotid region with no surrounding fat stranding, lymphadenopathy, or bony erosion. No malignant features were demonstrated. The mass measured 8.0 × 5.2 × 6.5 cm.

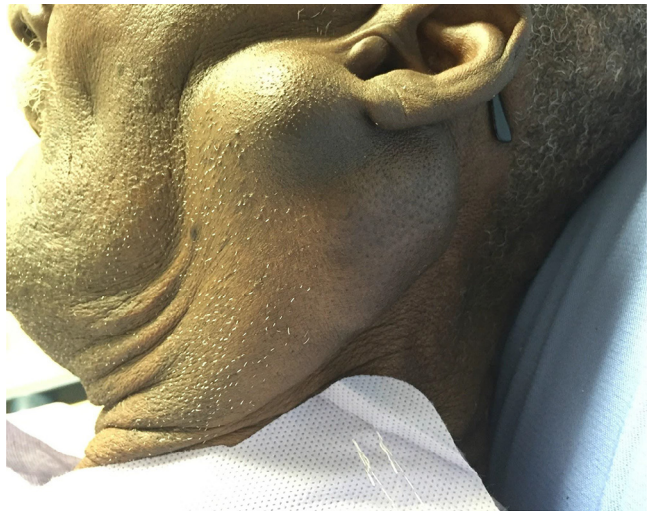

Fig. 2 – A 78-year-old man with a 10 × 12 cm parotid left neck mass during the day of sclerotherapy. Two simple fine needle aspirations were attempted before this procedure.

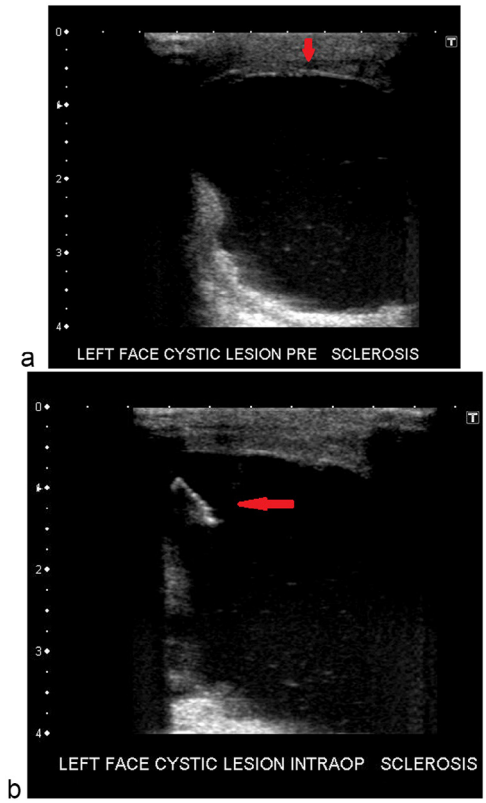

Fig. 3 – Sagittal ultrasound image of the cystic mass with internal echoes (red arrow), likely representing debris in the left parotid region (A). The 21-gauge micro puncture needle (red arrow) was shown to be within the cystic mass, in which the fluid was aspirated and sent for appropriate testing (B).

and at this time, the interventional radiology service was consulted to discuss any additional options for treating the recurrent neck mass. Several case reports demonstrated success utilizing sclerotherapy with a dehydrated alcohol (98% ethanol) solution. The patient agreed to this procedure. After placing the patient under general anesthesia in the operation room, a 21-gauge micropuncture needle was placed into the parotid mass under ultrasound guidance (Fig. 3A and B). Approximately 65 mL of serosanguineous fluid was aspirated and sent for culture and histopathologic testing. Ten milliliters of the sclerosing agent, 98% ethanol, was injected into the cystic mass. The cyst was gently massaged, and, after 10 minutes, its contents were aspirated (Figs. 4 and 5). On postoperative day 7, the patient presented with a recurrently enlarged mass approximately 60% of its preoperative size (Fig. 6). On postoperative day 35, the patient presented with a parotid mass of approximately 8 × 7 cm (Fig. 7), noticeably smaller than that in the first follow-up. One month after that, as per family, the patient's mass had continued to appear smaller. On postoperative month 4, the mass was noted to be reduced to 5 × 4 cm. As per family, the mass was the "smallest it has ever been." Cytopathology and microbiology analysis of the samples taken at the time

Download English Version:

https://daneshyari.com/en/article/8825195

Download Persian Version:

https://daneshyari.com/article/8825195

Daneshyari.com