



## Original Research

## New onset squamous cell carcinoma in previous split-thickness skin graft donor site

Vincent J. Noori<sup>a,b</sup>, Kanika Trehan<sup>a,b</sup>, Alisa Savetamal<sup>a,b</sup>, Damien W. Carter<sup>a,b,\*</sup><sup>a</sup> Department of Surgery, Maine Medical Center, Portland, ME 04102, United States<sup>b</sup> Department of Surgery, Bridgeport Medical Center, Bridgeport, CT 06610, United States

## ARTICLE INFO

## Keywords:

Marjolin's ulcer  
Squamous cell carcinoma  
Donor site  
Split thickness autograft

## ABSTRACT

**Introduction:** Marjolin's ulcer, an aggressive ulcerating squamous cell carcinoma, is a well-known phenomenon that occurs in chronically inflamed or scarred tissue; however, squamous cell carcinoma arising in the acute setting after tissue trauma - specifically autograft donor harvest sites for burns - is a rare, but notable event.

**Methods:** This case series describes three instances of squamous cell carcinoma diagnosed in split-thickness skin graft donor sites in the immediate post-operative period. Charts were reviewed in detail after at least 9 months follow-up from identification of the tumor. Detailed descriptions of each case are included. A discussion of the literature on this rare entity is included as well.

**Results:** In the three cases discussed, all were characterized clinically as painful masses arising in a recently healed donor site. Two were managed surgically with adherence to oncologic principals. One lesion regressed or fell off spontaneously. With at least 9 months follow-up, there was no evidence of recurrence.

**Conclusions:** Very few cases of acute neoplasm in donor sites have been described in the literature. Presently, there is no dominant theory as to how these lesions arise; however, this is an entity that burn care providers, world wide should be aware of, with a low threshold for oncologic evaluation if suspected.

## 1. Introduction

Marjolin's ulcer was first described by Dr. Jean-Nicolas Marjolin in 1828. This entity is well described in the literature as a squamous cell carcinoma (SCC) that develops within a pre-existent cutaneous scar or chronic non-healing wound.[1] While burn scars are known to develop marjolin's ulcers, there are very few articles describing its presentation in split-thickness skin graft (STSG) donor sites. Furthermore, acute squamous cell carcinomas developing in patients with no history of previous SCC is exceedingly rare. This article will describe three cases in which a donor STSG site developed SCC within weeks of donor site harvesting.

## 2. Methods

This case series describes three instances of squamous cell carcinoma diagnosed in split-thickness skin graft donor sites in the immediate post-operative period. Charts were reviewed retrospectively and in detail after at least 9 months follow-up from identification of the tumor. Detailed descriptions of each case are included.

The work has been reported in line with the PROCESS criteria [15].

## 2.1. Case presentations

## 2.1.1. Case 1

A 68-year-old male presented to the emergency department after sustaining a 2% total body surface area, full-thickness burn after spilling hot tar on the anterior aspects of both his ankles. The burns were across distal portions of the tibia just superior to the ankle (approximately 8 cm × 2.5 cm) with evident full thickness injury. The burns were cleansed and dressed with silver sulfadiazine 1% applied topically and he was sent home with follow-up plans for excision and grafting as an outpatient. He returned to the hospital four days post-injury for the operation. He received 3 g of Cefazolin intra-operatively. His anterior left thigh donor site was lubricated with mineral oil and STSG was harvested using the Zimmer dermatome set at a thickness of 0.012 inches. The harvested grafts were meshed with a standard card mesher device to a 1.5:1 ratio. The donor sites were then covered with thrombin-epinephrine soaked laparotomy pads. The donor site was dressed with Xeroform and gauze. The patient returned to the clinic one month after excision and grafting after noticing a firm mass that had grown over the previous 2 weeks on his anterior left thigh donor site. The patient's chief complaint was severe pain at the lesion. The pain

\* Corresponding author. Department of Surgery, Maine Medical Center, Portland, ME 04102, United States.  
E-mail address: [dcarter@mmc.org](mailto:dcarter@mmc.org) (D.W. Carter).

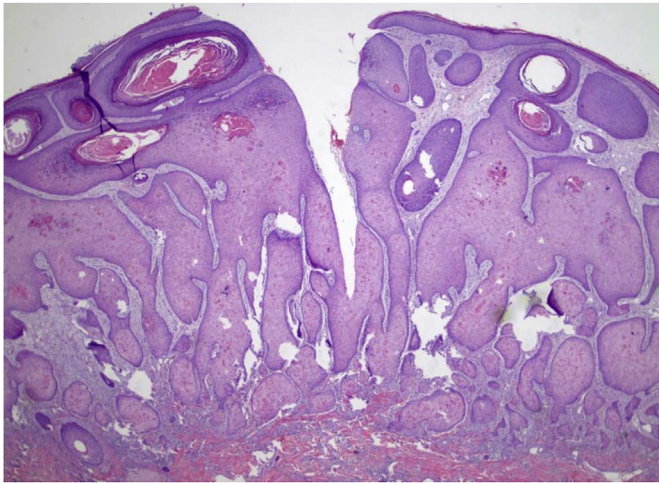


Fig. 1. Pathology demonstrating invasive squamous cell carcinoma arising from the epidermis and invading into the dermis.

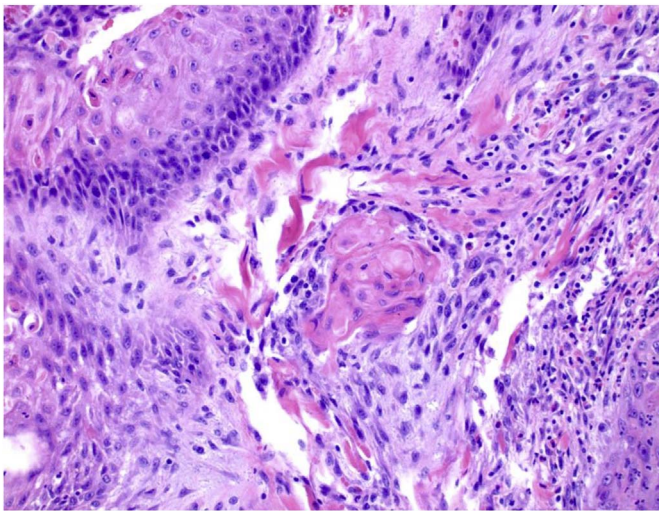


Fig. 2. Pathology demonstrating an invasive nest lacking basal layer, signifying invasion.

was exacerbated by palpation. There was no visible erythema or signs of infection present. The remainder of the donor site was asymptomatic. The mass was noted to be a circular cutaneous nodule approximately 1 cm in diameter. He underwent excisional biopsy of the mass with a 2 mm margin circumferentially using a #15 blade scalpel. The full-thickness dermis including the mass was excised down to subcutaneous tissue. The skin edges were brought together with interrupted 4–0 nylon sutures. The lesion was sent for pathology and a Xeroform dressing was applied to the biopsy site. He returned to clinic 2 weeks later for suture removal as well as to review the pathology results, which were positive for invasive SCC (Figs. 1 and 2). It was decided to excise the biopsy site with larger margins – adhering to oncologic principles - in the operating room. The patient returned to the operating room several days later. An elliptical incision was made measuring  $3 \times 10$  cm to achieve 1.3 cm margins of grossly uninvolved skin distant from the scar. Using a #15 blade, the incision was carried into subcutaneous fat and the lesion was completely removed. 3-0 Vicryl buried interrupted deep dermal sutures were used for subcutaneous layer and 4.0 Monocryl running subcuticular was used for the skin. Final pathology noted no additional lesions. The patient recovered without incident. Follow-up at 18 months post excision of the tumor noted no evidence of recurrent lesions in either the graft sites or the donor site.

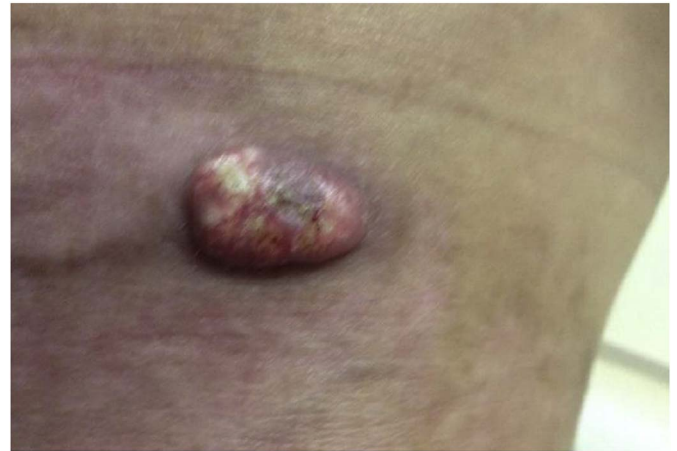

Fig. 3. Left hip lesion in the location of a previous donor site measuring 1 cm  $\times$  2 cm  $\times$  2 cm.

#### 2.1.2. Case 2

A 49 year-old male smoker presented after spilling hot oil on himself from a turkey fryer. He sustained multiple deep partial and full thickness burns to the right arm circumferentially, right flank, right thigh, and bilateral buttocks, comprising 20% TBSA. He was admitted on the day of the injury and between hospital days 0–21 underwent serial debridements with allograft, xenograft and autografting of the burns. Split thickness autografts of 0.012 inch thickness were taken from the left thigh, leg, back, and chest. His hospital course was complicated by a burn wound infection with MRSA that resolved with IV vancomycin. On day 26 he was discharged to home with home care with daily bacitracin and xeroform dressing changes.

At his one week follow up, his right upper extremity grafts were found to be healing. During the ensuing weeks, he developed painful, exudative, pustules on the dorsal right hand. These were found to be MRSA and responded to treatment with mupirocin cream and a 14-day course of sulfamethoxazole/trimethoprim. The patient also had two raised lesions, one on the left hip (Fig. 3) and one on the right lower leg within a previous skin graft donor site, both measuring roughly 1 cm  $\times$  2 cm  $\times$  2 cm. This donor site was harvested 23 days previous to identification of the lesion during outpatient follow-up visit. The left hip lesion resolved without intervention, but at 5 months after the initial burn the right lower leg lesion was still present. There is no record of whether or not this lesion was painful to palpation. The lesion was otherwise asymptomatic. At surgery for contracture release on his upper extremity, the leg lesion was excised as well. The final pathology was found to be invasive well-differentiated keratinizing squamous cell carcinoma with positive margins posteriorly. The specimen also grew staphylococcus epidermidis. He subsequently underwent re-excision of the right leg site with primary closure and with negative margins. Follow-up at 1 year noted no evidence of recurrence.

#### 2.1.3. Case 3

A 47 year-old male smoker presented with 50% TBSA 3rd and 4th degree electrical and flame burns to the torso, right upper extremity and bilateral thighs from an industrial accident while working with power transformer lines. Severe bilateral thigh compartment injury necessitated early bilateral thigh fasciotomies. He was initially managed at another facility where he underwent multiple operative procedures including debridement, allografting, and autografting during a 64-day hospitalization. His course also included burn wound sepsis that resolved with IV antibiotics. When the patient was discharged, most of his wounds were well-healed, and he required minimal dressings. He presented to our outpatient office 4 months after the initial burn injury for local follow up. The patient had hypertrophic scarring throughout his grafted sites, as well as several areas of hyper-granulation on the

Download English Version:

<https://daneshyari.com/en/article/8831894>

Download Persian Version:

<https://daneshyari.com/article/8831894>

[Daneshyari.com](https://daneshyari.com)