



Contents lists available at ScienceDirect

## International Journal of Surgery Case Reports

journal homepage: [www.casereports.com](http://www.casereports.com)

# Dislocation of a cerebral protection device component during carotid stenting: A case report of favorable outcome from conservative management after failure of retrieval

Iliaria Tocco-Tussardi<sup>a,b,\*</sup>, Caterina Kulyk<sup>c</sup>, Vincenzo Vindigni<sup>b</sup>, Giampiero Avruscio<sup>a</sup>

<sup>a</sup> Angiology Unit, Department of Cardiac, Thoracic and Vascular Sciences, University Hospital of Padova, Padova, Italy

<sup>b</sup> Clinic of Plastic and Reconstructive Surgery, Department of Neurosciences, University of Padova, Padova, Italy

<sup>c</sup> Clinic of Neurology, Department of Neurosciences, University Hospital of Padova, Padova, Italy

## ARTICLE INFO

### Article history:

Received 16 October 2017

Accepted 14 December 2017

Available online 28 December 2017

### Keywords:

Angioplasty

Carotid artery stenting

Cerebral protection device

Iatrogenic disease

Mechanical complication

Stroke

## ABSTRACT

**INTRODUCTION:** Cerebral-protection devices (CPDs) are a well-established system for reduction of embolic risk in carotid artery angioplasty and stenting (CAS). Although rare, adverse events with CPDs are unpredictable and can be associated with serious outcomes and iatrogenic sequelae.

**PRESENTATION OF CASE:** We describe the unique case of dislocation of a FilterWire EX™ filter loop during right CAS. On trying to recapture the CPD filter at the end of the procedure, the filter loop suddenly detached from the guidewire and dislocated to the proximal middle cerebral artery. Attempted retrieval of the loop failed and the patient developed a transient neurological deficit caused by an acute ischemic infarction in the lenticular nucleus. No further retrieval attempt was pursued. No further dislocation of the loop or clinical event have been reported during the 16-year follow up.

**DISCUSSION:** This case reported a favorable outcome of conservative management for entrapped material from a CPD after iatrogenic damage from failed retrieval. No similar reports are available in the literature, and conservative management is generally not a recommended approach because of the potential complications. However, rescue retrieval attempts are as well a potential source of serious events, and no clear guidelines exist on the management of mechanical complications from CPD.

**CONCLUSION:** Entrapment of CPD components constitutes an adverse event with no unique solution for risk-free management. The potential risks associated with the use of protection devices are still to be fully explored, and improving the standard of care and patient safety needs to be a top priority.

© 2018 The Authors. Published by Elsevier Ltd on behalf of IJS Publishing Group Ltd. This is an open access article under the CC BY-NC-ND license (<http://creativecommons.org/licenses/by-nc-nd/4.0/>).

## 1. Introduction

Cerebral-protection devices (CPDs) are an effective tool for reducing the risk of embolic complications during carotid artery angioplasty and stenting (CAS) [1,2]. However, the CPD itself may cause complications that may result in serious outcomes requiring rescue maneuvers and/or surgical removal of the device with iatrogenic sequelae [3–7].

The self-expanding, CPD FilterWire EX™ (Boston Scientific, Natick, MA, USA) has been approved for use in CAS [8] and a procedural success of 98% among patient stented under FilterWire EX protection has been reported [9]. The device consists of a 0.014" steerable guidewire mounting a polyurethane filter with 110 mm diameter pores attached to a 3.5–5.5-mm self-expanding nitinol loop. The filter is deployed distal to the lesion by retraction of a 3.9 Fr

delivery sheath and is supposed to be closed and retracted using a retrieval sheath after trapping embolic debris. We report the unique case of dislocation of the nitinol loop with unsuccessful attempted retrieval of the device and subsequent ischemic infarction in the lenticular nucleus. The patient was managed in a public setting.

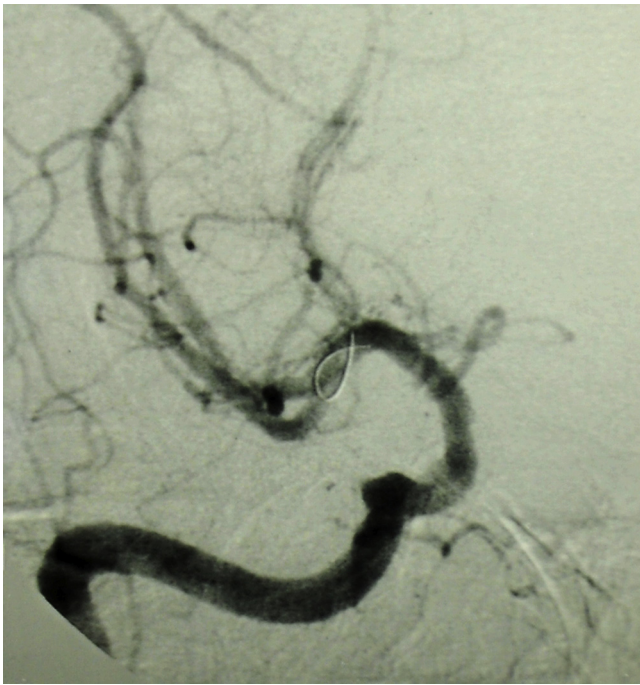
### 1.1. Presentation of case

A 55-year-old male with documented systemic atherosclerotic disease, hypertension, diabetes mellitus and a smoking history was referred by the family physician to the service of Interventional Neuroradiology for a severe (>70%) restenosis in the right internal carotid artery (ICA) 4 years after endarterectomy. He was scheduled for CAS with cerebral protection. Daily medicine included ticlopidine 250 mg, enalapril 20 mg, amiloride-hydrochlorothiazide 5 + 50 mg, ranitidine 150 mg, rapid-acting insulin 8 + 12 + 12 I.U., and long-acting insulin 8 I.U. (qd).

An 8-Fr introducer (Flexor Shuttle, Cook, Bloomington, IN, USA) was placed into the right CCA via the transfemoral approach. A FilterWire EX distal protection device was guided past the stenosis

\* Corresponding author at: University Hospital of Padova, Via Giustiniani 2, 35128 Padova, Italy.

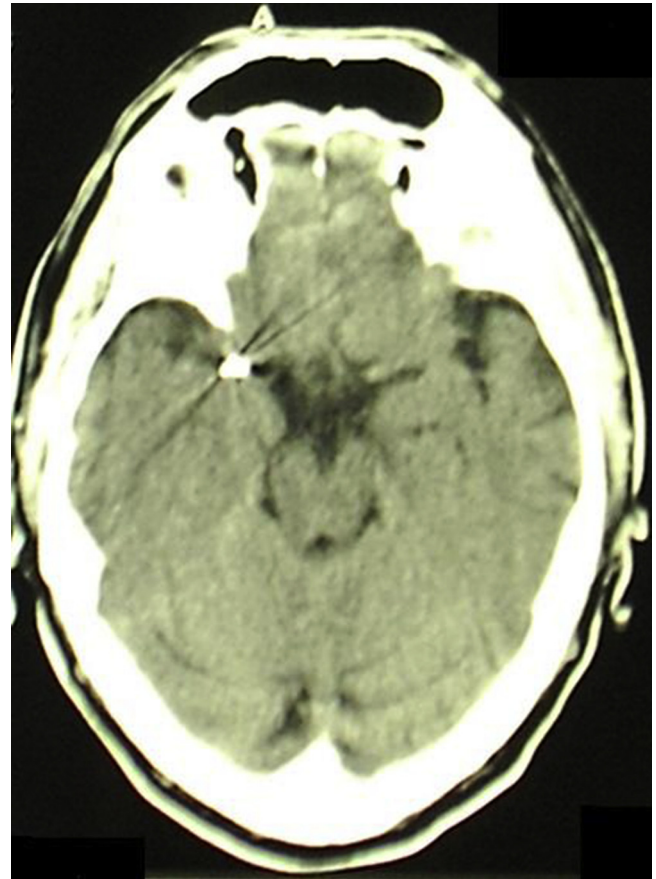
E-mail address: [iliana.toccotussardi@gmail.com](mailto:iliana.toccotussardi@gmail.com) (I. Tocco-Tussardi).



**Fig. 1.** Dislocation of the nitinol loop in the proximal branch of the right middle cerebral artery.

at the distal tract of the extracranial ICA and easily deployed. A  $3 \times 20$  mm balloon was placed across the stenosis and was inflated to its nominal value. A Precise RX nitinol  $8 \times 21$  mm stent (Cordis, Miami Lakes, FL, USA) was placed across the stenosis and the angiographic control showed a complete revascularization.

On trying to recapture the filter, when the operator moved the retrieval sheath forward on the catheter close to the device a significant resistance was encountered. During each attempt, the distal portion of the retrieval sheath would easily pass through the deployed stent but would not progress further to the loop, preventing retrieval of the distal protection device. After several failed attempts, the nitinol loop suddenly detached from the FilterWire EX guidewire and dislocated to the proximal middle cerebral artery (MCA) (Fig. 1). The operator attempted recollection of the device with a dedicated retriever passed over the FilterWire EX guidewire, that also proved unsuccessful. The operator then tried to mobilize the device by expanding a catheter guided balloon (Sentry, Target, Fremont, CA, USA) at the level of the FilterWire EX; during this maneuver the patient suddenly manifested a left faciobrachio-crural motor hemisyndrome (National Institutes of Health Stroke Scale – NIHSS 5) so it was decided to immediately interrupt the retrieval attempt. Immediate intracranial angiographic control was performed, showing reduction of caliber and delayed flow in the temporal inferior branch of the MCA. A cerebral CT scan performed immediately after the procedure showed no focal lesion; a control CT scan at 48 h revealed an acute ischemic infarct in the right anterior lenticular nucleus and small ischemic areas in the right insular-temporal cortex (Figs. 2 and 3). The patient was transferred to the Intensive Care Unit and then underwent intensive physical therapy, showing progressive improvement. He was discharged a month after the procedure on single antiplatelet therapy; the neurologic examination was negative (NIHSS 0). During the 16-year follow-up the patient remained stable and no new acute events were documented both on clinical and neuroradiological follow-up. The work has been reported in line with the SCARE criteria [10].



**Fig. 2.** Hyperdense signal in the middle cerebral artery showing the nitinol loop displacement.

## 2. Discussion

CAS has become the gold standard treatment of the extracranial carotid disease for stroke prevention, providing a viable alternative to carotid endarterectomy [1,9,11]: the technique is safe, minimally invasive, and it offers specific advantages compared to endarterectomy, especially in terms of cardiovascular complications (like myocardial infarction) and patients' comfort. A recently published randomized trial involving asymptomatic patients with severe carotid stenosis proved CAS guarantees equal performance of stroke-free survival up to 5 years compared to endarterectomy [11]. Nonetheless, the risk of stroke within the 30-day peri-procedural period stands higher with CAS, especially for patients aged  $>70$  years.

In order to limit the incidence of adverse events during the procedure, nowadays it is generally advised to perform CAS under protection using one of the three different types of protection devices that are commercially available: distal occlusion devices, distal filter devices, and proximal occlusion devices. Even though the efficacy of these devices has not been proven by any large randomized trial so far, unprotected CAS is considered improper by large part of the interventional community [3,12–15]. However, the use of a CPD is not always safe. Mechanical complications related to the use of CPDs during CAS include: locking between the stent-delivering catheter and the CPD; separation of the membranous component from the CPD; inability to pass the accessory retrieval sheath through the proximal/distal terminus of the stent/the stent lumen; retained CPD; and fractured guidewire. All cases reported so far were successfully resolved, either non-invasively (by manual carotid compression technique/endovascular rescue) [4–6,16]

Download English Version:

<https://daneshyari.com/en/article/8832987>

Download Persian Version:

<https://daneshyari.com/article/8832987>

[Daneshyari.com](https://daneshyari.com)