HOMO - Journal of Comparative Human Biology 67 (2016) 150–162

Contents lists available at ScienceDirect

HOMO - Journal of Comparative Human Biology

journal homepage: www.elsevier.com/locate/jchb

The coracoclavicular joint. A systematic review and meta-analysis

K. Yammine[a,*], C. Assi[b]

[a] Center for Evidence-based Anatomy, Sports and Orthopedics, The Foot & Hand Clinic, Emirates Hospital, Dubai, United Arab Emirates

[b] Orthopedic Department, Lebanese American University Medical Center – Rizk Hospital, Beirut, Lebanon

ARTICLE INFO

Article history:
Received 18 January 2015
Accepted 24 August 2015

ABSTRACT

The coracoclavicular joint (CCJ) is considered as a rare articulation in humans. Though rarely it could be symptomatic, its presence should be acknowledged by physicians. The aim of this systematic review is to conduct an evidence synthesis on the prevalence of this condition in different ethnic populations. Thirty nine studies including 51 sub-studies met the inclusion criteria. The meta-analytical results showed true prevalence values of ≃5%, ≃7% and ≃2.7% from skeletal, cadaveric and radiological studies, respectively. The bilateral occurrence of CCJ was found to be approximately the half of the crude prevalence and that in all study types. European populations showed the least frequency whereas the Eastern Asian and Native American populations showed the highest values in skeletal/cadaveric studies. European, modern American, Native American and modern South American populations showed the least CCJ occurrence rates in radiological studies. The Chinese population stood out from all other ancestries with a prevalence of 21%, followed by the Southeast Asians with a frequency of 6%. No association was found with variables such as sex or side. This evidence-based anatomical and anthropological review shed the light on the rare and poorly investigated CCJ. It yielded more accurate overall and ancestry-based frequencies from skeletal, cadaveric and radiological studies.

* Corresponding author.
E-mail address: kayseryam@yahoo.com (K. Yammine).

http://dx.doi.org/10.1016/j.jchb.2015.12.003
0018-442X/

Introduction

The coracoclavicular joint (CCJ) is a diarthrotic synovial joint (Fig. 1) between the superior surface of the horizontal part of the coracoid process of the scapula and the conoid tubercle of the clavicle (Cho and Kang, 1998; Gowland, 1915; Gumina et al., 2002; Nalla and Asvat, 1995; Poirier, 1890). While both facets are considered in cadaveric and radiological studies, its presence in skeletal/osteological studies is indicated by the existence of usually just one facet (Cho and Kang, 1998; del Sol et al., 2014), mainly on a conoid process of more than 2 mm whether faceted or not. The CCJ is known to be an anomalous roundish joint, easily observable in primates (Haramati et al., 1994). Gruber was the first to describe this articulation in 1861 in humans and since then its occasional presence was noted by many authors. According to Mann and Hunt (2005), the incidence of this anatomical variation is 1.0–1.2%. However, some early investigations stated that this joint is not that uncommon, existing in three out of ten cases (Poirier, 1890: p. 99, 101), and should be considered not an infrequent finding (Testut, 1904). More recently, Cockshott (1992) carried out a geographic analysis of the occurrence of the CCJ and found frequencies as high as 40% in the Chinese population with diminishing rates in other parts of the world as the distance from China increases. Jelbert (1970) did not mention this condition in 4897 chest films in African Rhodesians. On the other hand, Cho and Kang (1998) stated that this condition is more prevalent with age while others suggested a congenital abnormality (Faraj, 2003). Embryologically, the abnormal part of the clavicle at the level of the coracoclavicular joint is where the lateral and the medial ossification centers bridge (Rockwood et al., 1998). Nalla and Asvat (1995) reported some anthropological aspects significantly associated with the presence of a CCJ such as longer first ribs, longer scapula border lengths, longer paracostal lengths and greater scapula superior angles.

Coracoclavicular joints are rarely symptomatic. A comprehensive literature search conducted by Singh et al. (2011) yielded just 17 cases between 1915 and 2009. Shoulder pain was the main presenting symptom in 70.6%, followed by limited range of motion in 29.4%. Paresthesia and brachialgia were also described as associated symptoms. In addition, swelling and tenderness at the site of the coracoclavicular joint occurred in only 1 patient each (5.9%). The average age at presentation, when it was recorded, was 39.1 years. High prevalence of coracoclavicular joints also has been reported in patients with Holt–Oram syndrome (Poznanski et al., 1970). Caffey (1985) described “bony spurs” of the inferior clavicular surface in children with long-standing rheumatoid arthritis, which might be interpreted as CCJs.

Methods

A modified checklist of the MOOSE Guidelines for Meta-Analyses and Systematic Reviews of Observational Studies (Stroup et al., 2000), the Checklist for Anatomical Reviews and Meta-Analysis (CARMA), served as the framework for this review (Yammine, 2014).

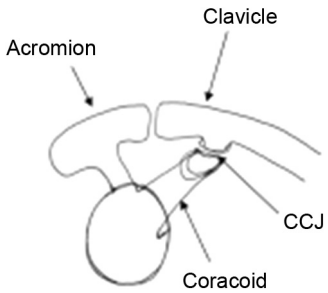

Fig. 1. Drawing of the coracoclavicular joint.