



## Case report

## Development of mediastinal adenitis six weeks after endobronchial ultrasound-guided transbronchial needle aspiration



Sho Shimada<sup>a,b,\*</sup>, Haruhiko Furusawa<sup>b</sup>, Toshihisa Ishikawa<sup>a</sup>, Eisaku Kamakura<sup>a</sup>, Takafumi Suzuki<sup>b</sup>, Yuta Watanabe<sup>a</sup>, Takasato Fujiwara<sup>a</sup>, Shinichiro Tominaga<sup>a</sup>, Keiko Mitaka Komatsuzaki<sup>a</sup>, Ichiro Natsume<sup>a</sup>

<sup>a</sup> Department of Respiratory Internal Medicine, Yokosuka Kyosai Hospital, 1–16 Yonegahama dori, Yokosuka, Kanagawa, 238-8558, Japan

<sup>b</sup> Department of Integrated Pulmonology, Tokyo Medical and Dental University, 1-5-45 Yushima, Bunkyo-ku, Tokyo, 113-8510, Japan

## ARTICLE INFO

## Keywords:

Mediastinal adenitis  
Endobronchial ultrasound-guided  
transbronchial needle aspiration  
Infectious complication  
Sarcoidosis

## ABSTRACT

A 60-year-old man visited our hospital for further examination of an abnormal chest radiograph. Computed tomography (CT) images revealed enlarged mediastinal lymph nodes and multiple pulmonary nodules.

Further evaluation by endobronchial ultrasound-guided transbronchial needle aspiration (EBUS-TBNA) was performed and he was diagnosed with sarcoidosis. Six weeks after EBUS-TBNA, he presented to the emergency department with a high-grade fever. CT scan revealed an enlarged mediastinal lymph node. He was diagnosed with mediastinal adenitis and treated successfully with antibiotics. EBUS-TBNA is a highly accurate diagnostic tool, but clinicians should be aware of mediastinal infectious complication that could be asymptomatic for long period of time.

## 1. Introduction

Due to its high-level of diagnostic accuracy and safety, endobronchial ultrasound-guided transbronchial needle aspiration (EBUS-TBNA) has become the standard method for diagnosing mediastinal lesions. However, critical mediastinal infectious complication has been reported. Previously, infectious complication has been reported to occur within a few weeks after the procedure and was suspected from symptoms such as fever, cough, or chest pain. We report a case of mediastinal adenitis that developed 6 weeks after EBUS-TBNA.

## 2. Case report

A 60-year-old man visited our hospital for further evaluation of an abnormal chest radiograph obtained on a health examination. He had a history of foot drop due to cervical spine injury and prostatic hyperplasia, which was treated with naftopidil. He had a 15-pack-year history of smoking. He did not report any symptoms and his physical examination was unremarkable. Computed tomography (CT) revealed multiple lung nodules and mediastinal and hilar adenopathy (Fig. 1). Mediastinum demonstrated the accumulation of gallium-67. EBUS-TBNA (BF-UC260FW, Olympus, Tokyo, Japan) was performed in the

lymph node station 4R using 21 gauge needle (NA-201SX-4021, Olympus, Tokyo, Japan) and a transbronchial lung biopsy (TBLB) was performed for multiple lung nodules. On EBUS-TBNA, echographic images suggested an isoechoic texture. 3 passes were made with 21 gauge needle without any event during the procedure and the patient was discharged the following day.

Although only tracheal cartilage was detected from the EBUS-TBNA sample, a non-caseating granuloma was seen in the TBLB samples and he was diagnosed with sarcoidosis. *Klebsiella pneumoniae* was detected from TBNA needle washing culture but he had no symptom up to two weeks during follow-up and the culture result was considered as contamination during the procedure.

Six weeks after the EBUS-TBNA, the patient developed a fever, chills, and fatigue and presented to the emergency department next day. On arrival, his vital signs were as follows: body temperature, 40.7 °C; blood pressure, 104/43 mmHg; pulse rate, 123 beats/min; SpO<sub>2</sub>, 97% in ambient air. On physical examination, his extremities were cold but other than that, the remainder of the examination was unremarkable.

Results from blood tests revealed white blood cell count of  $3.8 \times 10^9$  cells/L, C-reactive protein level of 193.6 mg/L, and procalcitonin level of 42.51 µg/L (Table 1). A widened mediastinum was

\* Corresponding author. Department of Respiratory Internal Medicine, Yokosuka Kyosai Hospital, 1–16 Yonegahama dori, Yokosuka, Kanagawa, 238-8558, Japan.

E-mail address: [shi2pulm@tmd.ac.jp](mailto:shi2pulm@tmd.ac.jp) (S. Shimada).

<https://doi.org/10.1016/j.rmcr.2018.08.015>

Received 3 June 2018; Received in revised form 21 August 2018; Accepted 21 August 2018

2213-0071/© 2018 The Authors. Published by Elsevier Ltd. This is an open access article under the CC BY-NC-ND license (<http://creativecommons.org/licenses/by-nc-nd/4.0/>).

detected by a chest radiograph and an enhanced CT revealed swelling of station 4R lymph node where the EBUS-TBNA was performed six weeks ago. The lesion had a hypodense center suggestive of an abscess. Severe sepsis due to infectious mediastinal adenitis was suspected and treatment consisting of 1g of doripenem was administered every 8 hours and vasopressor was initiated. *Klebsiella pneumoniae*, the same species that was identified from TBNA needle washing culture, was detected in a blood and sputum culture. The patient started recovering and the vasopressor was tapered off on day 6. The fever lasted till day 21 and antibiotics were continued for one month.

CT on day 28 revealed a shrinkage of the hypodense region in the lymph node and the patient was discharged on day 34 (Fig. 2).

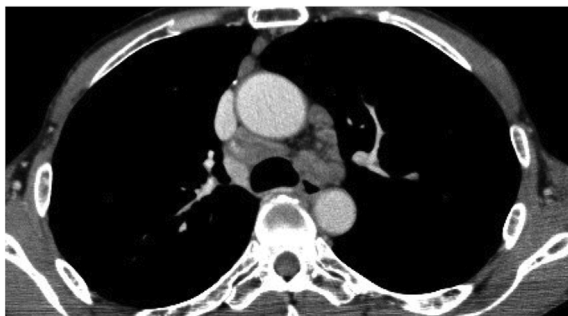

Fig. 1. Computed tomography before endobronchial ultrasound-guided transbronchial needle aspiration. Enlarged mediastinal lymph nodes with calcification were observed.

Table 1  
Blood examination on date of admission.

Peripheral blood		Biochemistry	
White blood cells	$3.8 \times 10^9/L$	Lactate dehydrogenase	486 IU/L
Neutrophil	93.2%	Aspartate aminotransferase	236 IU/L
Lymphocyte	4.2%	Alanine aminotransferase	73 IU/L
Monocyte	1.6%	Alkaline phosphatase	405 IU/L
Eosinophil	0.5%	$\gamma$ -glutamyl transpeptidase	118 IU/L
Basophil	0.3%	Creatine kinase	214 IU/L
Hemoglobin	118g/L	Urea nitrogen	19 IU/L
Platelets	$1.64 \times 10^{11}/L$	Creatinine	11.9 mg/L
Blood coagulation		Sodium	140 mEq/L
Activated partial thromboplastin time	44.1 sec	Potassium	3.2 mEq/L
Prothrombin time	16.3 sec	Chloride	106 mEq/L
Prothrombin time-international normalized ratio	1.26	Calcium	84 mg/L
D-dimer	20.3 mg/L	Serology	
		C-reactive protein	193.6 mg/L
		Procalcitonin	42.51 $\mu$ g/L

### 3. Discussion

EBUS-TBNA has been reported to be a safe and useful method of choice for the diagnosis of mediastinal lesion. Sonographic features of EBUS itself is helpful differentiating sarcoidosis from other diseases and the diagnostic accuracy of EBUS-TBNA for sarcoidosis can be as high as 79%, ranging from 54–93% [1,2]. TBLB is another procedure used to establish the diagnosis of sarcoidosis, but its accuracy ranges from 40–90% [3,4] and it carries a risk of a pneumothorax (1–6%) and hemoptysis (0.8%) [5]. A nationwide survey in Japan reported that the complication rate of EBUS-TBNA was relatively low (1.23%) and infectious complications developed in 0.19% of patients, which included 7 cases of mediastinal infection [6]. Other studies also report the rate of severe adverse events from EBUS-TBNA to be less than 1% [7,8]. Complications associated with EBUS-TBNA are rare, but mediastinal infectious complication after EBUS-TBNA has been reported sporadically with fatal clinical course.

From 28 cases of mediastinal infectious complication after EBUS-TBNA (Table 2), the symptom of most cases started with slight illness, such as fever or chest pain but progressed into a severe condition, such as septic shock. In 20 cases, invasive treatment such as thoracotomy were needed and one case resulting in mortality [30]. Epstein SK et al. suggested that the mechanism for infectious complication after TBNA is infection by the oropharyngeal commensal organisms that contaminate the working channel of the EBUS-scope while passing the oropharyngeal airway and being inoculated into the target lesion by a puncture needle [9]. In this case, *Klebsiella pneumoniae* was cultured from TBNA needle washings which we send for culture routinely. The same organism was found in the blood and sputum cultures six weeks after the procedure,

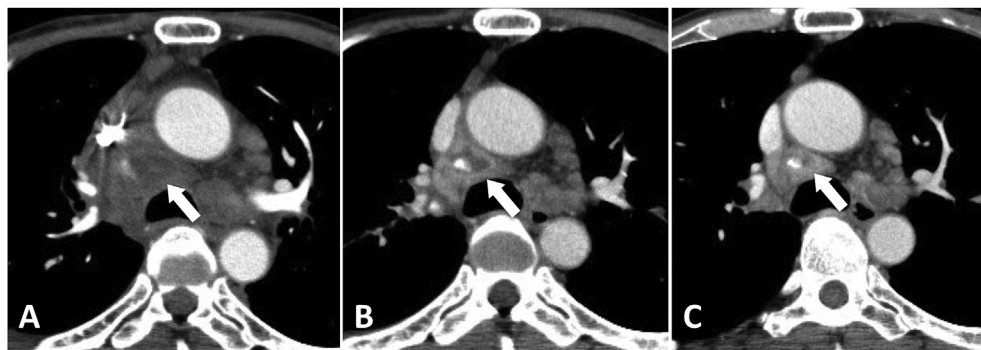


Fig. 2. Computed tomography on day of admission (A), 2 weeks (B), 4 weeks (C) after treatment. The 4R lymph nodes were shrinking gradually after treatment.

Download English Version:

<https://daneshyari.com/en/article/10097284>

Download Persian Version:

<https://daneshyari.com/article/10097284>

[Daneshyari.com](https://daneshyari.com)