



## Case report

# Successful long-term treatment of persistent pulmonary air leak in pneumocystis jirovecii pneumonia by unidirectional endobronchial valves

Stefanie Bader<sup>a</sup>, Christian Faul<sup>a</sup>, Stephan Raab<sup>b</sup>, Martin Schwaiblmair<sup>a</sup>, Thomas M. Berghaus<sup>a,\*</sup>

<sup>a</sup> Department of Cardiology, Respiratory Medicine and Intensive Care, Klinikum Augsburg, Ludwig-Maximilians-University Munich, Germany

<sup>b</sup> Department of Thoracic Surgery, Klinikum Augsburg, Ludwig-Maximilians-University Munich, Germany



## ARTICLE INFO

## Keywords:

Pneumocystis jirovecii pneumonia  
Spontaneous pneumothorax  
Persistent air leak  
Endobronchial valves

## ABSTRACT

Spontaneous pneumothorax is a rare complication of pneumocystis jirovecii pneumonia. We report a patient with pneumocystis jirovecii pneumonia and therapy-refractory, right-sided pneumothorax due to persistent air leak (PAL) despite prolonged chest tube placement and multiple pleurodesis attempts. Due to the patient's morbidity, we evaluated if the PAL can be sealed by unidirectional endobronchial valves (EBVs). After occlusion of the right upper lobe by a balloon catheter, the air leak flow-rate decreased from 800 ml/min to 250 ml/min. Zephyr EBVs (ZEBVs) were placed in the segmental right upper lobe bronchi and subsequently, a complete resolution of the pneumothorax was noted. During 30 months of follow-up, neither recurrence of pneumothorax nor any adverse events of EBV treatment were noted. We conclude that ZEBV placement might be an effective and well-tolerated treatment option for PAL secondary to pneumocystis jirovecii pneumonia with promising long-term results.

## 1. Introduction

Persistent air leak (PAL) of the lung is defined as an abnormal communication between the bronchial tree or the alveolar space and the pleural cavity which may lead to pneumothorax [1]. PAL can occur spontaneously or can result from thoracic surgery or chronic lung diseases. Spontaneous pneumothorax occurs in up to 2% of patients suffering from pneumocystis jirovecii pneumonia [2].

The therapy of PAL can be challenging, especially in the critically ill patient. If prolonged chest tube placement with or without pleurodesis is not efficacious, some patients will require surgical interventions. However, many critically ill patients are poor surgical candidates. Therefore, bronchoscopic attempts have been made using different devices like tissue glue, gel foam, silver nitrate, autologous blood patches, spigots or stents [3]. As none of these methods has shown significant efficacy to replace surgical intervention, the placement of unidirectional intrabronchial valves using flexible bronchoscopy has been evaluated, showing promising results as an alternative and less invasive treatment of PAL [1].

## 2. Case report

A 42-year-old man with human immunodeficiency virus infection and acquired immune deficiency syndrome (AIDS) presented to the emergency department with bilateral pneumonia. His anti-retroviral therapy with emtricitabin, tenofovir and raltegravin was continued and he received intravenous antibiotic treatment with piperacillin and tazobactam 4.5 g tid. Rapid respiratory failure shortly after admission required immediate orotracheal intubation and mechanical ventilation. Computed tomographic pulmonary angiography excluded acute pulmonary embolism but revealed bilateral pulmonary infiltrates suspicious for pneumocystis jirovecii pneumonia and a right-sided pneumothorax (Fig. 1). A chest tube with continuous suction of  $-20$  cm H<sub>2</sub>O was placed. Flexible bronchoscopy with broncho-alveolar lavage detected pneumocystis jirovecii. The patient was started on trimethoprim-sulfamethoxazole 20/100 mg/kg qid. Intravenous prednisolone was administered due to severe hypoxemia. Subsequently, the respiratory situation improved and the patient could be weaned and extubated after seven days of ventilator support.

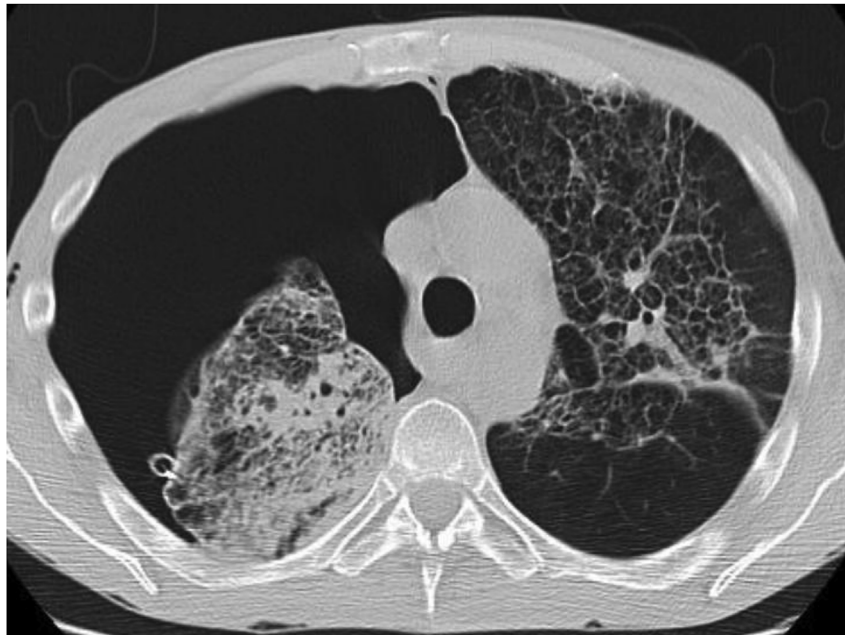
\* Corresponding author. Klinikum Augsburg, Stenglinstrasse 2, D-86156 Augsburg, Germany.

E-mail address: [thomas.berghaus@klinikum-augsburg.de](mailto:thomas.berghaus@klinikum-augsburg.de) (T.M. Berghaus).

<https://doi.org/10.1016/j.rmcr.2018.08.021>

Received 11 April 2018; Received in revised form 23 August 2018; Accepted 24 August 2018

2213-0071/© 2018 The Authors. Published by Elsevier Ltd. This is an open access article under the CC BY-NC-ND license (<http://creativecommons.org/licenses/by-nc-nd/4.0/>).



**Fig. 1.** Thoracic computed tomographic scan revealing bilateral pulmonary infiltrates suspicious for pneumocystis jirovecii pneumonia and a right-sided pneumothorax.

However, pneumothorax persisted and chest tube evacuation revealed right-sided PAL despite multiple pleurodesis attempts using doxycycline. Therefore, and due to the patient's significant morbidity (AIDS, severe bilateral pneumonia with hypoxemia, cachexia), we decided to evaluate if the PAL might be successfully sealed by unidirectional endobronchial valves (EBVs). A flexible bronchoscopy in deep sedation was performed and the air leak flow-rate was continuously measured using a medela pump (Medela GmbH & Co., Dietersheim, Germany). After occlusion of the right upper lobe segmental bronchi by a balloon catheter (Teleflex Medical Europe Ltd., Athlone, Ireland), flow-rate decreased from 800 ml/min to 250 ml/min. As balloon occlusion on sub-segmental level of the right upper lobe did not achieve similar results, the segmental bronchi were occluded using 3 Zephyr EBVs (ZEBV 5.5 mm, ZEBV 4.0 mm, ZEBV 4.0 LP, Pulmonx Inc., Neuchâtel, Switzerland). Subsequently, resolution of the pneumothorax was noted and the air leak flow completely ceased. The chest tube was removed eight days after EBV treatment, and the patient could be discharged after 52 days in hospital. Removal of the valves was offered to the patient eight weeks after discharge from the hospital; however, he refused another bronchoscopy. During 30 months of follow-up, neither recurrence of pneumothorax nor any adverse events of EBV treatment were noted (Fig. 2).

### 3. Discussion

The use of unidirectional intrabronchial valves in the treatment of PAL has been described several times since 2005 [1]. Most patients suffered from post-operative PAL, suppurative lung disease or spontaneous pneumothorax [3]. To date, there exists only one report in the current literature about EBV treatment of PAL secondary to pneumocystis jirovecii pneumonia [4].

In a recent review, EBV treatment for pneumothorax secondary to PAL was found to be effective and well-tolerated with resolution rates between 48 and 100% and rare complications like infection, expectoration or migration of the valves [3]. However, in most previous case reports, EBVs were removed four to eight weeks after resolution of the PAL in order to minimise the risk of side effects [1]. None of these case series report long-term follow-up results.

To our best knowledge, this is the first report of successful EBV therapy in a patient with PAL secondary to pneumocystis jirovecii pneumonia with a long-term follow-up. We conclude that ZEBV placement might be an effective and well-tolerated treatment option for PAL secondary to pneumocystis jirovecii pneumonia with promising long-term results.

### Disclosure of potential conflicts of interest

All authors certify that they have no affiliations with or involvement in any organization or entity with any financial interest (such as honoraria; educational grants; participation in speakers' bureaus; membership, employment, consultancies, stock ownership, or other equity interest; and expert testimony or patent-licensing arrangements), or non-financial interest (such as personal or professional relationships, affiliations, knowledge or beliefs) in the subject matter or materials discussed in this manuscript.

### Ethical approval and Informed consent

All procedures performed in studies involving human participants were in accordance with the ethical standards of the institutional and/or national research committee and with the 1964 Helsinki declaration and its later amendments or comparable ethical standards. Informed

Download English Version:

<https://daneshyari.com/en/article/10097286>

Download Persian Version:

<https://daneshyari.com/article/10097286>

[Daneshyari.com](https://daneshyari.com)