



Contents lists available at ScienceDirect

International Journal of Surgery Case Reports

journal homepage: www.casereports.com

Coloseminal vesicle fistula after low anterior resection: Report of a case and review of the literature

M. Boulianne^{a,*}, G. Bouchard^b, J. Cloutier^c, A. Bouchard^d^a PGY 2, General Surgery Program, CHU de Québec, Laval University, 2325 rue de l'Université, Québec, Québec, G1V 0A6, Canada^b Division of Diagnostic Radiology, St-François d'Assise Hospital, CHU de Québec, 10 rue de l'Espinay, Québec, Québec, G1L 3L5, Canada^c Division of Urology, St-François d'Assise Hospital, CHU de Québec, 10 rue de l'Espinay, Québec, Québec, G1L 3L5, Canada^d Division of Colorectal Surgery, St-François d'Assise Hospital, CHU de Québec, 10 rue de l'Espinay, Québec, Québec, G1L 3L5, Canada

ARTICLE INFO

Article history:

Received 7 June 2018

Received in revised form 14 August 2018

Accepted 15 August 2018

Available online 31 August 2018

Keywords:

Fistula

Seminal vesicle

Low anterior resection

Anastomotic leakage

ABSTRACT

INTRODUCTION: A rectoseminal vesicle fistula after a low anterior resection for rectal cancer is a rare complication despite their anatomic proximity. From a Medline search from 1966 to date, a total of twenty-one previous cases of coloseminal vesicle fistula have been reported. From these cases, eleven were a complication of laparoscopic low anterior resection for rectal cancer.

DESCRIPTION OF THE CASE: This report presents the case of a 63-year-old patient who was readmitted to the hospital on the fifteenth postoperative day after his surgical intervention for fever, abdominal pain, dysuria and pneumaturia. A sinography with water-soluble contrast revealed a tract between the rectum and the seminal vesicle. The condition was treated conservatively with antibiotics, urinary catheter and a transanastomotic Malecot probe for abscess drainage. The fistula had completely recovered on postoperative day 71 and the patient is still symptoms free, six months after the complication developed.

DISCUSSION: This case reinforces the presumed link between anastomotic leakage and rectoseminal vesicle fistula in cases of low anterior resection while reviewing and summarizing similar previously reported cases on the course of the disease, diagnostic procedures and treatment options.

CONCLUSION: Seminal vesicle are susceptible to fistula in oncological resection of rectum. Both CT scan with water-soluble contrast or sinography are effective diagnostic examinations. Depending on the characteristics of the fistula, conservative approach may be adequate and benefits much less morbidities than the surgical options.

© 2018 The Author(s). Published by Elsevier Ltd on behalf of IJS Publishing Group Ltd. This is an open access article under the CC BY-NC-ND license (<http://creativecommons.org/licenses/by-nc-nd/4.0/>).

1. Introduction

Fistulas between the colon and the seminal vesicles are rarely seen in patients. From a Medline search from 1966 to date, a total of twenty-one cases have been reported [1–18]. The etiologies of this type of fistula vary among Crohn's disease [1,2,5], acute diverticulitis [9,11,12], operative complications of prostate [6,7], direct invasion by rectal cancer [8], iatrogenic perforation with transrectal drainage of seminal vesicle abscess [10] and finally, eleven of these reported cases are a direct complication of low anterior resection for rectal cancer [3–5,13–18].

From the previous reported cases, it seems confirmed that anastomotic leakage in patients who had a low anterior resection is a clear risk factor for rectoseminal vesicle fistula. Therefore, with those patients, who may have symptoms of pneumaturia, fever, abdominal tenderness and possibly scrotal swelling and testicular pain, with negative investigations for rectovesical fistula, it is nec-

essary that we keep our level of suspicion high for a rectoseminal vesicle fistula.

The intention of this report is to present a case of rectoseminal vesicle fistula and to review and analyze the presumed course of the disease, diagnostic procedures and treatment options, according also to the background literature.

This work has been reported in line with the SCARE criteria [21].

2. Case report

A 63-years-old male was referred to our tertiary center for treatment of an adenocarcinoma of the rectum, 2 cm from the anal verge. The cancer was diagnosed by colonoscopy after a positive history of melena. The preoperative staging was T2N0M0. The patient did not receive any neoadjuvant therapy.

A low anterior resection was performed by laparoscopy with end-to-end anastomosis and loop ileostomy. The inferior mesenteric artery was resected at its origin and a CEEA 28 mm was used to perform the anastomosis. The tissue rings were intact and the air test was negative at the time of the operation. The final pathology revealed an adenocarcinoma of the rectum pT2N0 (0/28) with com-

* Corresponding author.

E-mail address: melissa.boulianne.1@ulaval.ca (M. Boulianne).

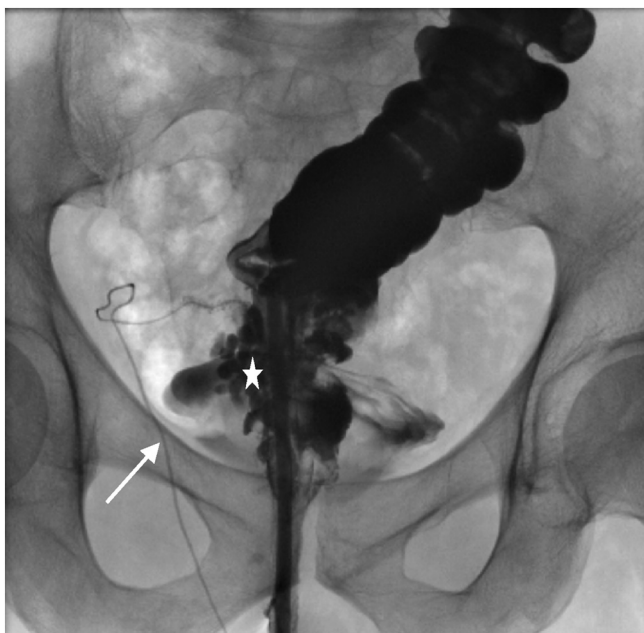


Fig. 1. Sinography. Opacification of rectum and distal colon via transanastomotic Malecot probe. Anterior to the rectum, the right seminal vesicle is identified (star). The linear structure with an oblique path corresponds to the right vas deferens (arrow).

plete mesorectum and negative margins. The postoperative period was uneventful and the patient was discharged on the third day.

At time of the discharge the patient still had abdominal and anal pain. Then, on postoperative day 8, he developed dysuria, urinary retention and low grade fever. Then, on postoperative day 15, he developed pneumaturia and was readmitted to the hospital. A short colonoscopy confirmed the anastomotic leakage and antibiotic therapy was initiated. The patient was brought to the OR for drainage and installation of transanastomotic Malecot probe. The investigations for rectovesical fistula were negatives (urethrocytology & cystography). The antibiotics were stopped and patient was discharged on postoperative day 21 with a urinary catheter and his transanastomotic Malecot probe.

On follow up appointment, 6 weeks after the initial surgery, a sinography by the transanastomotic Malecot probe with water-soluble contrast finally diagnosed the rectoseminal vesicle fistula by opacification of both seminal vesicles, the bladder, the right ejaculatory duct, right vas deferens and proximal urethra (Figs. 1 and 2). The urinary catheter and Malecot probe were removed and the patient was kept on antibiotic prophylaxis. A water-soluble contrast enema done one month later showed resolution of the anastomotic leakage. Antibiotics were stopped and patient underwent closure of his loop ileostomy 4 months after initial surgery. As of today, the patient is still complication free of his rectoseminal vesicle fistula.

3. Discussion

Rectoseminal vesicle fistula is a rare complication of low anterior resection for rectal cancer. Patients present with symptoms of epididymitis, low urinary tract infection and pneumaturia with negative investigations for rectovesical fistula. Many factors increase the risks of such complication but anastomotic leak seems to be the stronger element (Table 1).

Anastomosis insufficiency is still the more frequent complication of low anterior resections, accounting for 6% of cases [17]. The conditions associated with anastomotic leakage are male sex, neoadjuvant chemoradiotherapy, low anastomotic level and

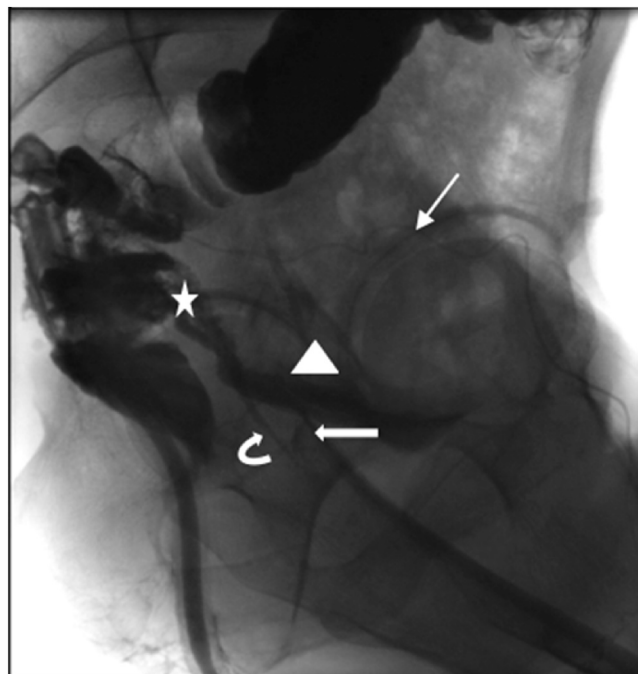


Fig. 2. Lateral view showing opacification of the seminal vesicles (star), right vas deferens (thin arrow), right ejaculatory duct (curved arrow), proximal urethra (thick arrow) and bladder (triangle).

patients' comorbidities such as obesity, diabetes and preoperative intake of steroid and non-steroidal anti-inflammatory medication [19,20]. The use of a diverting stoma however, is associated with a decreased risk of anastomotic leakage [19].

More than anastomotic leak, it seems that it is the rupture of the pelvic abscess that causes the fistula, which is supported by the late onset of this complication (mean value of 27 days after initial surgery within all reported cases in the literature, Table 1).

Another element linked with seminal vesicle fistula in cases of low anterior resections is the removal of Denonvilliers's fascia when performing total mesorectum excision [16]. This rectoprostatic fascia is composed of several layers of fibromuscular tissue that covers the seminal vesicles by dividing the prostate and urinary bladder from the rectum beneath the peritoneal reflection. Therefore, with a low anastomotic level and Denonvilliers's fascia resected, the seminal vesicles are susceptible of fistula when exposed to inflammation and infection. Inflammation can be caused also by antibiotic-induced colitis as reported in two other cases [3,18].

Moreover, iatrogenic fistula by the resection of the seminal vesicles themselves without prophylactic ligation is another risk factor for rectoseminal vesicle fistula [16].

One question that has not been asked however is whether there is a link between anastomotic leakage and ligation of the inferior mesenteric artery from its origin instead of ligating only the superior rectal artery while performing the surgery. Is there an impact on the vasculature that causes low grade ischemia at the level of the anastomosis that results in leakage in the subsequent postoperative days? Except this case, none of the previous ones in the literature give enough operative details to make such an assumption.

The diagnosis of rectoseminal vesicle fistula cannot be performed with the usual investigations for rectovesical fistula, such as cystoscopy and cystography. Therefore, with corresponding clinical signs, a high level of suspicion is indicated and either sinography or CT scan with water-soluble contrast to demonstrate the coloseminal vesicle fistula [3–5,14–18]. While a vasogram could be used, it is invasive, expensive and it has not been proven to be superior to the

Download English Version:

<https://daneshyari.com/en/article/10130019>

Download Persian Version:

<https://daneshyari.com/article/10130019>

[Daneshyari.com](https://daneshyari.com)