

## Case Report

# Combined cilioretinal artery and hemi-retinal vein occlusion in Sturge Weber syndrome Expanding the clinical spectrum

Sawsan S. Bakri<sup>a</sup>; Deema Jomar<sup>a</sup>; Sulaiman M. Alsulaiman<sup>b</sup>; Marwan A. Abouammoh<sup>a,\*</sup>

## Abstract

A 9-year-old boy with the diagnosis of Sturge-Weber Syndrome, and port-wine stain involving the right side of the face, presented with acute visual loss of the right eye. Examination revealed a high intraocular pressure and a combined cilioretinal artery and inferior hemi-retinal vein occlusion in the right eye. Systemic work-up was negative. After controlling the intraocular pressure, gradual improvement of vision was noticed with simultaneous disappearance of signs of vascular occlusion.

**Keywords:** Retinal artery occlusion, Retinal vein occlusion, Sturge-Weber syndrome, Glaucoma

© 2017 The Authors. Production and hosting by Elsevier B.V. on behalf of Saudi Ophthalmological Society, King Saud University. This is an open access article under the CC BY-NC-ND license (<http://creativecommons.org/licenses/by-nc-nd/4.0/>). <http://dx.doi.org/10.1016/j.sjopt.2017.07.001>

## Introduction

Sturge-Weber syndrome, or encephalo-trigeminal angiomatosis, is a non-inherited congenital disorder characterized by facial cutaneous vascular malformations (referred to as port-wine stain), ipsilateral leptoangioma and ocular involvement.<sup>1</sup> Port-wine stain typically involves the ophthalmic and maxillary branches of the trigeminal nerve which has been linked to various ocular complications.<sup>2</sup> Glaucoma, choroidal hemangioma, retinal detachment, macular edema and retinal venous obstruction have all been previously reported in Sturge-Weber patients.<sup>3</sup> To our knowledge, this is the first report of combined cilioretinal artery occlusion (CLRAO) and hemi-retinal vein occlusion (HRVO) in Sturge-Weber Syndrome.

## Case report

A 9-year-old boy with Sturge-Weber syndrome presented to the ophthalmic emergency department with sudden decrease in vision in his right eye. His past medical history was unremarkable except for having laser skin treatment for the port-wine stain on the right side of his face a week prior to presentation. On examination, a naevus flammeus (port-wine-stain) involving the right side of the face was noted. The best corrected visual acuity (BCVA) was hand motion in the right eye and 20/20 in the left eye. Intraocular pressure (IOP) was 30 mmHg in his right eye and 19 mmHg in his left eye. A right relative afferent pupillary defect was noted. Gonioscopy showed open angles in both eyes. Examination of the right fundus revealed a clear media, a subtotal optic

Received 26 March 2017; received in revised form 19 May 2017; accepted 31 July 2017; available online xxx.

<sup>a</sup> Department of Ophthalmology, College of Medicine, King Saud University, Riyadh, Saudi Arabia

<sup>b</sup> Retina Division, King Khaled Eye Specialist Hospital, Riyadh, Saudi Arabia

\* Corresponding author at: Department of Ophthalmology, College of Medicine, King Saud University, P.O. Box 245, Riyadh 11411, Saudi Arabia. Fax: +966 11 4775724.

e-mail addresses: [ss\\_md@hotmail.com](mailto:ss_md@hotmail.com) (S.M. Alsulaiman), [dr.abouammoh@gmail.com](mailto:dr.abouammoh@gmail.com) (M.A. Abouammoh).



Peer review under responsibility of Saudi Ophthalmological Society, King Saud University



Production and hosting by Elsevier

Access this article online: [www.saudiophthaljournal.com](http://www.saudiophthaljournal.com) [www.sciencedirect.com](http://www.sciencedirect.com)

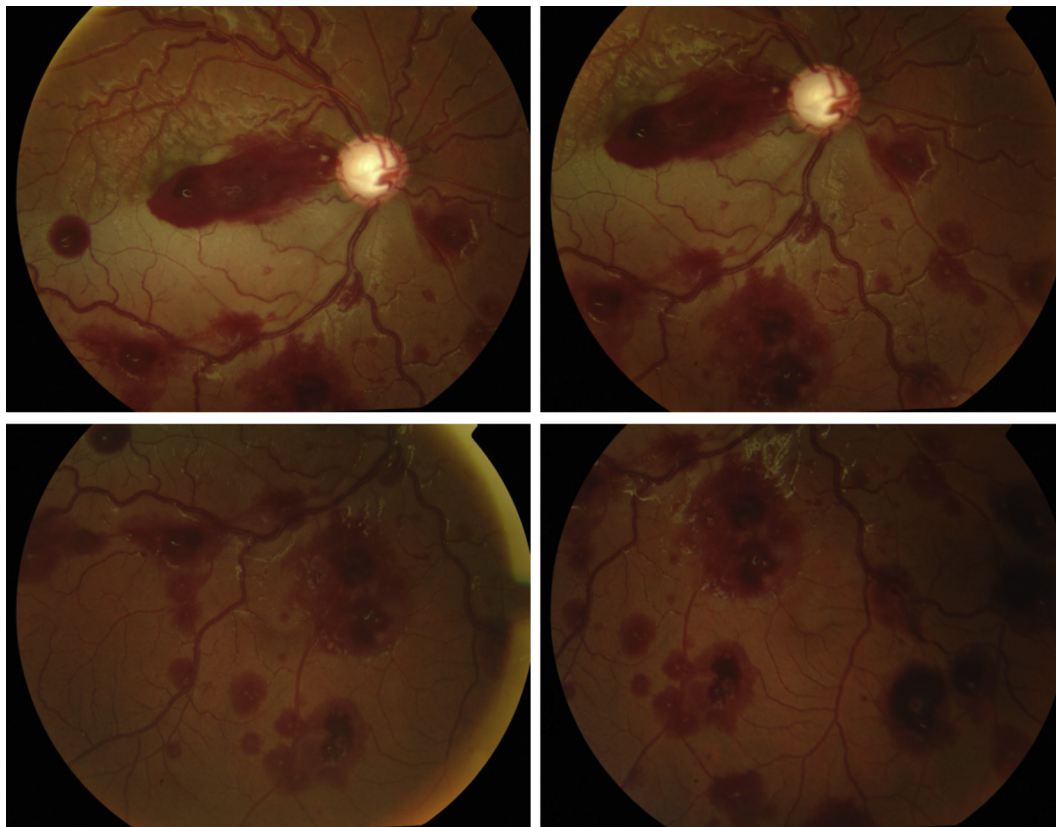
nerve head cupping, and vascular tortuosity in all four quadrants. There was an area of retinal ischemic whitening involving the inferior part of the macula along with subhyaloid and sub-internal limiting membrane blood over the fovea, and multiple white-dotted intraretinal hemorrhages involving the inferior two quadrants (Fig. 1). Fluorescein angiography showed delayed filling of the cilioretinal artery and generalized delayed venous filling –especially in the inferior hemisphere- (Fig. 2). There was no evidence of a choroidal hemangioma by examination or ultrasound. A diagnosis of Sturge-Weber syndrome related open-angle glaucoma with combined inferior HRVO and CLRAO in the right eye was made and the patient's right eye was started on timolol/dorzolamide 0.5%/2% twice daily and bimatoprost 0.03% at bed time.

A battery of tests including complete blood count, erythrocyte sedimentation rate, hematocrit, blood glucose, blood culture, renal and liver function tests, lipid profile, thrombophilia screen, serum protein electrophoresis, antiphospholipids antibodies, carotid doppler, electrocardiogram, and echocardiography evaluations were completely normal. On subsequent follow-ups, the retinal ischemic whitening and hemorrhages resolved gradually over 2 months and the IOP was well-controlled on topical anti-glaucoma medications. On his three-month follow-up, the patient recovered to a final visual acuity of 20/80 in his right eye (Fig. 3).

## Discussion

We report a case of combined inferior HRVO and CLRAO in a patient with Sturge-Weber syndrome. Combined cilioretinal artery and central retinal vein occlusion has been described previously.<sup>4,5</sup> It presents clinically as a drop of vision with fundus findings consistent with both venous and arterial obstruction such as: intra-retinal hemorrhages, disc edema and ischemic whitening of the retina. The exact pathogenesis of combined central retinal vein and cilioretinal artery occlusion is controversial. It is unclear if the arterial or venous obstruction precedes or both occur simultaneously.<sup>6,7</sup> Our patient had sequential events which ultimately lead to combined cilioretinal artery and vein occlusion in his right eye ipsilateral to his port-wine stain. We postulate that he first developed a retinal venous congestion with inferior HRVO due to an increase in IOP, the HRVO caused a significant rise in the intraluminal pressure because the central retinal artery continues to pump blood into the retina. Soon after, and since the perfusion pressure of the cilioretinal artery is lower than the central retinal artery, it becomes occluded.<sup>4,5</sup>

Thus, the preceding event in our case was the IOP rise. It is well known that Sturge-Weber patients are at risk of retinal venous occlusion due to the high frequency of glaucoma.<sup>8</sup> High-IOP in these patients has been linked to the presence of vascular abnormalities and usually develops on the ipsilateral side of the port-wine stain.<sup>3</sup>



**Fig. 1.** Color fundus photo of the right eye showing macular ischemic whitening along with subhyaloid and sub-internal limiting membrane blood covering the fovea, with multiple intraretinal hemorrhages involving the inferior two quadrants.

Download English Version:

<https://daneshyari.com/en/article/10211502>

Download Persian Version:

<https://daneshyari.com/article/10211502>

[Daneshyari.com](https://daneshyari.com)