

## Case Report

## A healthy infant with bloody tears Case report and mini-review of the literature

Salwa Bakhurji<sup>a</sup>; Sanaa A. Yassin<sup>b,\*</sup>; Reemaz M. Abdulhameed<sup>c</sup>

## Abstract

A 4-month old healthy infant was brought by her parents to the emergency department with bloody tears of three days duration. There was also intermittent yellowish discharge since birth and a history of flu-like symptoms a week prior to presentation. Extensive investigations revealed no infection or other possible etiologies. The patient was treated with antibiotic eye drops and her condition resolved within a three-four days.

In the literature, 15 cases with haemolacria of undermined source were reviewed; the median age of onset (12 years), bilateral involvement and female gender were more commonly encountered, and the most common associated illnesses were headache and epistaxis. The condition is self-limiting and spontaneous resolution is seen in majority of cases. Idiopathic haemolacria is a rare condition that can be presumed in patients presenting with bloody tears when all work-up turns to be negative. The condition is self-limiting with spontaneous resolution.

**Keywords:** Idiopathic, Haemolacria, Bloody tears

© 2017 The Authors. Production and hosting by Elsevier B.V. on behalf of Saudi Ophthalmological Society, King Saud University. This is an open access article under the CC BY-NC-ND license (<http://creativecommons.org/licenses/by-nc-nd/4.0/>). <https://doi.org/10.1016/j.sjopt.2017.10.006>

## Introduction

Haemolacria is a rare condition in which a person bleeds from the eyes. This condition was first described by Doda-naeus in 1581 who noticed it in a 16-year old non menstruating girl.<sup>1</sup>

Haemolacria is usually unilateral, benign, and a self-limiting. It has a wide range of etiologies. The most common ones are inflammations, lacerations, or infections of the conjunctiva, eyelids, or nasolacrimal system.<sup>1,2</sup>

Other causes include trauma, tumors of the lacrimal sac or paranasal sinuses, hereditary hemorrhagic telangiectasia, Henoch-Schonlein Purpura, epistaxis with retrograde flow, vascular malformations, and inherited or acquired bleeding disorders or coagulopathies.

We report a healthy infant presenting with bilateral bloody tears without any obvious underlying cause, which resolved with topical antibiotics course. A review of literature to summarize and highlight the characteristics of patients presenting with idiopathic haemolacria was carried out.

Received 11 May 2017; received in revised form 15 October 2017; accepted 24 October 2017; available online xxxx.

<sup>a</sup> Department of Ophthalmology, Armed Forces Hospital King Abdulaziz Airbase, Dhahran, Saudi Arabia

<sup>b</sup> Department of Ophthalmology, Imam Abdulrahman Bin Faisal University, Formerly (University of Dammam), PO Box 40097, Al-Khobar 31952, Saudi Arabia

<sup>c</sup> Imam Abdulrahman Bin Faisal University, Dammam, Saudi Arabia

\* Corresponding author. Fax: +966 138966776.  
e-mail address: [syassin@uod.edu.sa](mailto:syassin@uod.edu.sa) (S.A. Yassin).



Peer review under responsibility of Saudi Ophthalmological Society, King Saud University



Production and hosting by Elsevier

Access this article online:  
[www.saudiophthaljournal.com](http://www.saudiophthaljournal.com)  
[www.sciencedirect.com](http://www.sciencedirect.com)

## Case report

A 4-month old healthy, agitated girl was brought by her parents to the emergency department with complaints of bloody tears from both eyes for three days (Fig. 1). There was a history of intermittent yellowish discharge since birth. Flu-like illness was reported one week prior to presentation, with no other symptoms of infection. There was no history of any previous similar episodes or any family history of bleeding disorders. General past medical, surgical, and family history were negative. The child was a product of full-term spontaneous vaginal delivery.

Ophthalmologic examination of both eyes was normal with normal conjunctival fornices and puncti apart from the bloody tears when the child cries. Fixation, extraocular eye movements, cycloplegic-refraction and fundoscopy were unremarkable. ENT evaluation was normal.

Laboratory studies including full blood count, coagulation profile, bleeding time, clotting time, prothrombin time, and platelets count were within the normal ranges. Results for bilateral conjunctival swab culture and sensitivity showed no growth. CT scans of orbits and paranasal sinuses were unremarkable.

The child was considered to have haemolacria of undetermined source. Both the bloody tears and discharge resolved within three-four days after treatment with fusidic acid (Fucithalmic) 1% viscous eye drops. The child was followed up for four months with no further recurrence of the discharge or bloody-tears to justify subjecting the child for further work-up such as; examination under anaesthesia or probing, as the condition was completely resolved.

## Discussion

Haemolacria is a very rare condition with heterogeneous etiopathogenesis ranging from idiopathic, infectious, traumatic, neoplastic, vascular, inflammatory, self-inflicted, bleeding or coagulation disorders to side effects of topical medication.<sup>1</sup> However, most of bloody tears cases are secondary to conjunctival lesions and are usually benign.<sup>2</sup> The

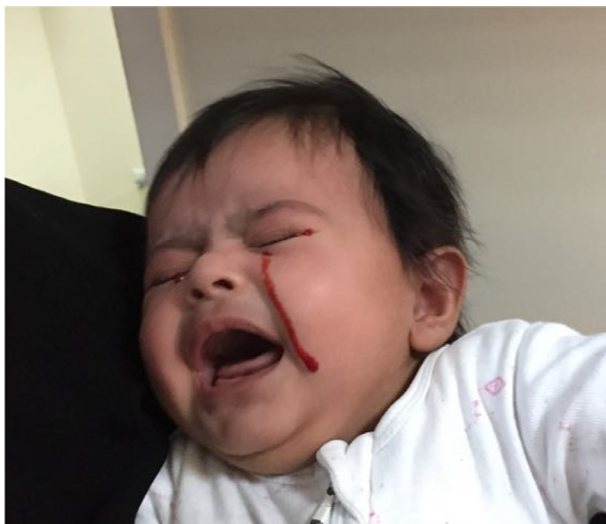


Fig. 1. Bilateral bloody tears in a 4-month old infant.

source of the bleeding can be the lacrimal glands, ocular surface or nasolacrimal system.<sup>1</sup> Usually the etiology of haemolacria is established by means of thorough history taking, general, ophthalmologic examinations, laboratory, and radiological assessments.

The management of this condition is diverse and basically aims to mend the underlying cause. Treatment can include antibiotics (topical or systemic), correction of the bleeding disorders, anti-inflammatory agents, or resection of lesions such as mass or granuloma. Bloody tearing can be alarming to patients, parents or caregivers so counseling services can also be provided to help them cope with this disturbing condition.

A diagnosis of idiopathic haemolacria can only be made when all work-up are normal and secondary causes are ruled. It is uncommon for the cause of haemolacria to be unidentified.<sup>3</sup>

The literature review revealed that only 10 case reports and case series have been identified reporting 15 cases with undetermined source of haemolacria that has been investigated thoroughly.<sup>1-10</sup> The criteria of these cases in addition to our case are summarized in Table 1. The age ranged from 4 month to 20 year with a median age of onset at 12 years. Our case was the youngest among all reported cases. Females were more commonly affected than males (13:3). Bilateral involvement is more common than unilateral involvement in a ratio of 2:1. The duration of symptoms ranged from 1 day to 5 years. Associated illnesses included headache, epistaxis, haematohidrosis, yellowish eye discharge, twitching of extremities, spitting blood, low-grade fever, and menorrhagia. Headache and epistaxis were the most common association. The presence of haematohidrosis (bloody sweat) was seen in three patients and was usually associated with psychological stress and showed a more persistent, complex course of the disease.<sup>1,4,8</sup> Moreover, psychological stress can be a preexisting association or it may be aggravated by having this unnerving disorder. Most of the cases resolved spontaneously over few days to 14 month and majority of cases had no recurrence. The two cases with yellowish eye discharge received antibiotic treatment that resolved the condition. The source of the bloody tears was not identified in all eyes. However, in two eyes of two patients whom were reported by Fowler et al.,<sup>3</sup> nasolacrimal system was believed to be the source of bleeding. These eyes had punctal plugs that were inserted into each patient's inferior punctum on the left side only. This treatment modality resulted in immediate cessation of haemolacria of the left eye of both patients while the problem persisted on the right eye indicating that the nasolacrimal system is the source of bleeding. The treatment was aimed to provide symptomatic relief and to assists in anatomic localization. Moreover, epistaxis was an associated finding in five out of the 15 cases which may point towards an occult lesion in the nasolacrimal system to be the source of bleeding.<sup>2-6</sup>

In conclusion, patients with haemolacria, in whom all investigations (radiological, laboratory, and histopathological) are negative, can be deemed idiopathic. The condition is self-limiting and spontaneous resolution is seen in majority of cases. It is important for patients with unknown etiology to have regular follow up to ascertain not missing occult pathologies. Counseling services can also be provided to

Download English Version:

<https://daneshyari.com/en/article/10211505>

Download Persian Version:

<https://daneshyari.com/article/10211505>

[Daneshyari.com](https://daneshyari.com)