

CASE REPORT

Phacoemulsification with intraocular pinhole implantation associated with Descemet membrane endothelial keratoplasty to treat failed full-thickness graft with dense cataract

Bruno Lovaglio Caçado Trindade, MD, PhD, Fernando Caçado Trindade, MD, PhD, Claudio Lovaglio Caçado Trindade, MD, Marcony Santhiago, MD, PhD

We present a case in which a different approach was used to treat an eye with dense cataract associated with an irregular failed full-thickness corneal graft. After cataract surgery, a foldable intraocular pinhole was implanted in the capsular bag to treat the irregular corneal astigmatism. Next, a Descemet membrane endothelial keratoplasty graft was used to improve transparency in the failed

penetrating keratoplasty. This approach addressed the cataract, irregular cornea, and failed graft through a standard 2.2 mm clear corneal phacoemulsification incision, thus avoiding open-sky surgical time and expediting visual rehabilitation.

J Cataract Refract Surg 2018; ■:■-■ © 2018 ASCRS and ESCRS

Penetrating keratoplasty (PKP) has been widely used to treat advanced keratoconus over the years. It is known that although vision might fully recover initially, graft failure can occur after 20 to 30 years.^{1,2} Traditionally, substituting a full-thickness graft is the treatment for such a condition. More recently, with introduction of endothelial keratoplasty, it is possible to salvage a failed graft with the replacement of the endothelium and Descemet membrane by Descemet-stripping automated endothelial keratoplasty (DSAEK) or Descemet membrane endothelial keratoplasty (DMEK).^{3,4} These techniques, provide faster visual recovery with less induced astigmatism, preservation of ocular integrity, and no open-sky surgical time.

Anshu et al.⁵ have shown that endothelial keratoplasty has a lower rejection rate than PKP and that DMEK has the lowest rate of the two techniques. Also, cataract surgery can be associated with this procedure to treat lens opacity at the time of the corneal surgery.⁶ However, this approach is limited by the regularity of the anterior surface of the initial corneal graft. By transplanting only the posterior layers of the graft, existing irregular corneal astigmatism is not treated and vision can still be limited by it after the cornea clears. In such cases, rigid contact lenses might be required; however, when their use is not possible, a full-thickness graft might be required in an attempt to achieve better anterior surface regularity.

We published a new way of addressing corneal irregular astigmatism by using an intraocular pinhole device (Xtrafocus, Morcher GmbH).⁷ This device was designed to be implanted in the ciliary sulcus in pseudophakic eyes. It is made of hydrophobic foldable acrylic with a 1.3 mm central opening and no dioptric power.

We present a case of a failed irregular corneal graft associated with dense cataract that was treated using a DMEK graft combined with cataract surgery and implantation of an intraocular pinhole. We believe this is the first reported case in which this approach was used.

CASE REPORT

A 63-year-old woman presented with reports of a progressive decrease of vision in the left eye over the past 2 years. She had a history of PKP in both eyes in the 1980s, to treat advanced keratoconus; the PKP was performed elsewhere. The patient remarked that a new graft had to be placed in the right eye 1 year after the initial procedure because of graft failure resulting from endothelial rejection. The uncorrected and corrected vision in the right eye had been much better than in the left eye since the corneal graft surgeries. Although the patient was offered a new PKP in the left eye to improve her uncorrected vision, she refused. Contact lenses had been tested multiple times in the past. Although she reported an improvement in vision, she refused to keep wearing the lenses because of a lack of comfort. The uncorrected distance visual acuity (UDVA) was 20/200 and the uncorrected near visual acuity (UNVA) was Jaeger (J) 2 in the right eye, improving to

Submitted: May 26, 2018 | Final revision submitted: June 19, 2018 | Accepted: June 21, 2018

From Caçado Trindade Eye Institute (B.L.C. Trindade, F.C. Trindade, C.L.C. Trindade), Medical Sciences School of Medicine (B.L.C. Trindade), Medical Sciences University Hospital Eye Institute (B.L.C. Trindade), Belo Horizonte, and the University of Sao Paulo (C.L.C. Trindade, Santhiago), São Paulo, Brazil.

Corresponding author: Bruno Lovaglio Caçado Trindade, MD, PhD, Rua Manaus, 595, Belo Horizonte, MG, 30150-350, Brazil. Email: bruno.trindade@ioct.org.

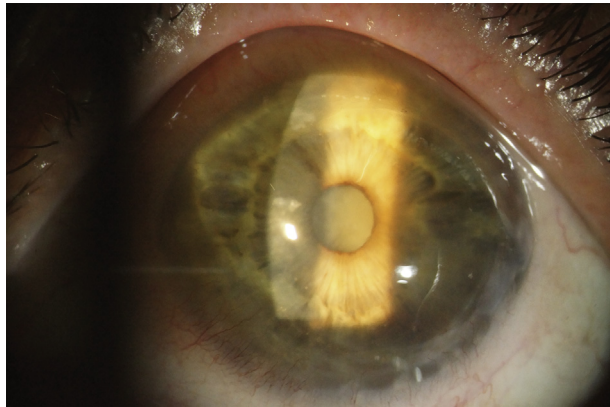


Figure 1. Preoperative biomicroscopy of the left eye.

20/60 with +3.00 –1.25 × 30. UCDVA in the left eye was counting fingers with no improvement with refraction. Anterior segment biomicroscopy showed a clear, well-centered corneal graft in the right eye with grade II nuclear lens opacity. The left eye had an edematous irregular graft associated with 360-degree thinning of the graft–host junction and dense cataract (Figure 1).

Fundoscopy of the right eye showed an attached retina with posterior vitreous detachment. The cup-to-disc ratio was 0.3. Lens opacity hindered posterior examination in the left eye; thus, a B-scan was performed, which showed no abnormality other than total vitreous detachment. The central corneal thickness, assessed using an ultrasound pachymeter (500 Pachette, DGH Technology, Inc.), was 626 μm in the right eye and 774 μm in the left. Corneal tomography (Pentacam HR, Oculus Optikgeräte GmbH) showed an irregular and steep graft in the left eye with diffuse edema. The anterior corneal astigmatism was 18.3 diopters (D) according to simulated keratometry (Figure 2).

Scheimpflug image analysis showed a protruded graft with thinning of the graft–host junction. Biometry using optical laser interferometry (Lenstar, Haag-Streit AG) showed an elongated left eye (axial length [AL] 25.48 mm) with a very deep anterior chamber (5.11 mm). The intraocular lens (IOL) power calculation using the Holladay 1 formula recommended a –9.0 D monofocal acrylic IOL. After a discussion of the pros and cons, the patient gave informed consent for cataract removal with implantation of an

intraocular pinhole in the capsular bag; the plan was to leave the ciliary sulcus open in case secondary implantation was needed to correct the implant power. This was to be followed by DMEK graft placement under the failed PKP. A neodymium:YAG laser inferior peripheral iridotomy was performed 1 day before surgery.

A single superonasal 2.2 mm clear corneal incision peripheral to the original graft–host junction was created. Trypan blue 0.1% was used to stain the anterior capsule. A capsulorhexis was performed with a diameter of approximately 5.5 mm in the usual manner. This was followed by phacoemulsification using the surgeon’s preferred technique. After cortex removal, the bag was reinflated with a cohesive ophthalmic viscoelastic device (sodium hyaluronate 1.0% [Healon]). The intraocular pinhole was implanted in the capsular bag using an IOL cartridge (D cartridge, Alcon Laboratories, Inc.) through the same unenlarged incision used for cataract surgery (Figure 3).

Next, acetylcholine chloride (Miochol) was administered to promote pupil constriction. Two additional side-port incisions were created. Descemetorhexis was performed under air inside the previous graft, with care not to disturb the posterior aspect of the graft–host junction. A graft from a 61-year-old donor, which had been prestripped and pre-“F”-stamped to warrant right-side-up graft insertion, was then punched to 7.75 mm with a Barron corneal punch (Katena Products, Inc.). After Descemet peeling, the graft was stained with trypan blue 0.1% for 2 minutes and loaded in a glass pipette (Geuder AG). Graft implantation was performed through the main phacoemulsification incision, with unfolding and centration of the graft completed in less than 2 minutes (Figure 4).

Air was used to fixate the graft. Interrupted 10-0 nylon sutures were placed in the main incision and in the side ports. Intraocular pressure (IOP) was elevated to approximately 40 to 50 mm Hg for 10 minutes, and surgery was completed after pressure was reduced to physiologic levels, leaving a total air fill in the anterior chamber. Two hours after surgery, the patient was checked and the air bubble was above the inferior peripheral iridotomy; the IOP was 20 mm Hg, and the patient was discharged. On the following day, the patient had a 30% air fill of the anterior chamber and a very edematous cornea with an IOP of 14 mm Hg. Moxifloxacin–dexamethasone 0.1% (Vigadexa) drops every 2 hours were then prescribed. Five days later, the patient returned with worsening of the corneal edema. Anterior-segment optical coherence tomography (Visante, Carl Zeiss Meditec AG) was performed and showed a subtotal graft detachment with inferior edge curling (Figure 5).

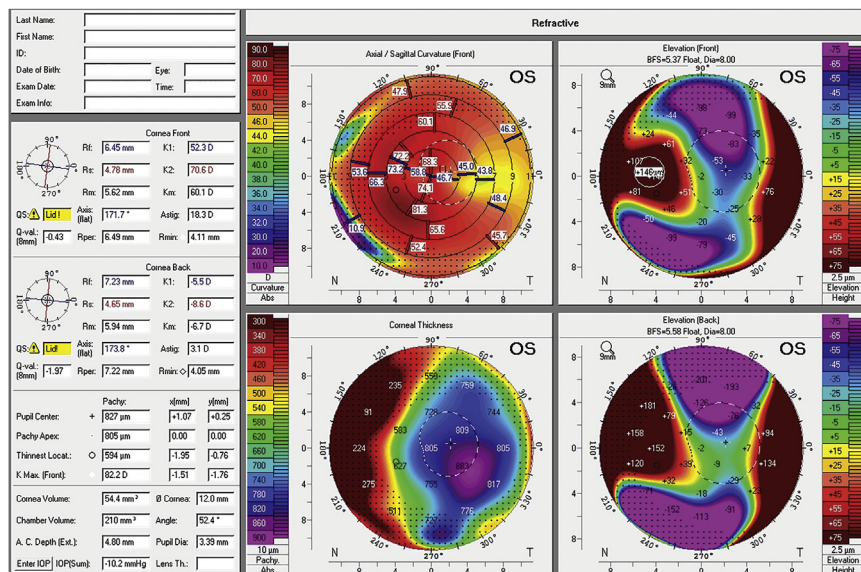


Figure 2. Scheimpflug corneal tomography shows a very irregular left cornea.

Download English Version:

<https://daneshyari.com/en/article/10220795>

Download Persian Version:

<https://daneshyari.com/article/10220795>

[Daneshyari.com](https://daneshyari.com)