

Available online at www.sciencedirect.com

ScienceDirect

journal homepage: www.elsevier.com/locate/radcr

Case Report

Pulmonary embolism and megaloblastic anemia: is there a link? A case report and literature review

Grecia Iveth Raymundo-Martínez, MD^a, Rodrigo Gopar-Nieto, MD^a, Gonzalo Carazo-Vargas, MD^a, Diego Araiza-Garaygordobil, MD^b, Sergio Raul Scuri, MD^c, Laura Leticia Rodríguez-Chavez, MD^d, Nilda Espinola-Zavaleta, MD, PhD^{e,*}

^a Fellows in training of Cardiology, National Institute of Cardiology Ignacio Chavez, Mexico City, Mexico

^b Chief of Fellowship in Cardiology and fellow in Coronary Care Unit, National Institute of Cardiology Ignacio Chavez, Mexico City, Mexico

^c Chief of Fellowship in Cardiology, Italian Hospital, La Plata, Buenos Aires, Argentina

^d Out-patient Clinic, National Institute of Cardiology Ignacio Chavez, Mexico City, Mexico

^e Nuclear Cardiology, National Institute of Cardiology Ignacio Chavez, Mexico City, Mexico

ARTICLE INFO

Article history:

Received 16 June 2018

Revised 9 July 2018

Accepted 16 July 2018

Keywords:

Pulmonary embolism

Megaloblastic anemia

B12 deficiency

ABSTRACT

Many factors have been associated with venous thromboembolism. Among them, vitamin B12 deficiency can produce elevated homocysteine levels, which is a risk factor for venous embolism, since the latter interferes with the activation of Va coagulation factor by activation of C protein.

We present a case of a patient with metabolic syndrome with apparently unprovoked pulmonary embolism. After careful evaluation, megaloblastic anemia was detected. Even though the patient had biochemistry findings of hemolysis and blood smear did not show fragmented erythrocytes, which is consistent with pseudo-microangiopathic hemolytic anemia.

© 2018 The Authors. Published by Elsevier Inc. on behalf of University of Washington.

This is an open access article under the CC BY-NC-ND license.

(<http://creativecommons.org/licenses/by-nc-nd/4.0/>)

Introduction

Acute pulmonary embolism is a cardiovascular emergency. After initial stratification and directed treatment, etiology must be identified to decide anticoagulation time and to prevent future episodes. Many factors have been associated with venous thromboembolism. Among them, vitamin B12 deficiency can

produce elevated homocysteine levels, which is a risk factor for venous embolism, since the latter interferes with the activation of Va coagulation factor by activation of C protein. This factor also increases the expression of tissue factor and suppresses sulfate heparin, an endogenous anticoagulant.

We present a 74-year-old patient with pulmonary embolism that was taken to thrombofragmentation and thrombolysis in situ. After careful analysis, it was considered that

Conflict of interest: The author(s) declare that there is no conflict of interest.

Funding: This research received no specific grant from any funding agency in the public, commercial, or not-for-profit sectors.

* Corresponding author.

E-mail address: niesza2001@hotmail.com (N. Espinola-Zavaleta).

<https://doi.org/10.1016/j.radcr.2018.07.018>

1930-0433/© 2018 The Authors. Published by Elsevier Inc. on behalf of University of Washington. This is an open access article under the CC BY-NC-ND license. (<http://creativecommons.org/licenses/by-nc-nd/4.0/>)

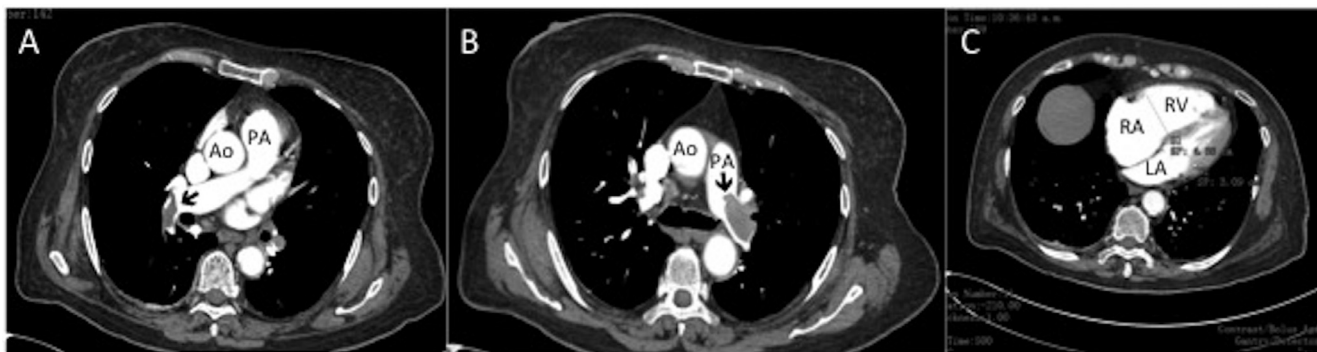


Fig. 1 – A,B- CT angiography showing thrombus (Black arrows) in the main, and subsegmental branches of the pumony artery. Ao, Aorta; LA, left ventricle; PA, pumony artery; RA, right atrium, RV, right ventricle.

megaloblastic anemia and metabolic syndrome, as a state of hyperhomocysteinemia, was the cause of this particular event. Supplementary treatment with B12 was administered with no further events. Vitamin B12 deficiency must be addressed and treated as a cause of acute pulmonary embolism.

Case report

A 74-year-old female with a background of metabolic syndrome was admitted to the emergency room with typical angina, dyspnea and syncope in 2 occasions. At admission, the blood pressure was normal (130/80 mmHg) as well as oxygen saturation (S_{O2}-92%), but the patient was tachycardic and tachypneic with heart rate of 110 bpm and respiratory rate of 24 rpm. Electrocardiogram revealed sinus tachycardia, complete right bundle branch block, with ST segment elevation of 2 mm in the inferior wall; therefore, an emergency coronary angiography was performed, without coronary arteries lesions. Laboratory findings revealed increment of troponin I and NT-pro BNP, D-dimer was positive and data of megaloblastic anemia were detected. CT angiography confirmed a bilateral main, subsegmental acute pulmonary embolism (Fig. 1A and B) and dilatation of the right cavities (Fig. 1C). Echocardiogram revealed normal left ventricular systolic function with ejection fraction of 60%, right ventricular dilation with basal diameter of 46 mm, moderate pulmonary hypertension with systolic pulmonary artery of 60 mm Hg and right ventricular systolic dysfunction with the tricuspid annulus displacement during systole of 15 mm, right ventricular fractional shortening area of 25%, S tricuspid wave of 9.21 cm/seg, right ventricular and/or left ventricular ratio of 1.48 and shift of the interventricular septum to the left. Pulmonary thromboembolism was diagnosis with PESI score of 114 points and New York Heart Association functional class IV; therefore low molecular-weight heparin was administered.

Right catheterization revealed systolic and/or diastolic and/or mean pulmonary artery pressure of 60/18/35 mm Hg, respectively, right ventricular systolic and diastolic pressure of 60/4 mm Hg, respectively, end-diastolic right ventricular pres-

sure of 12 mm Hg, right atrial a wave of 10 mm Hg, v wave of 12 mmHg and mean pressure of 11 mmHg.

Two days later she developed cardiogenic shock, which was treated with norepinephrine and dobutamine. Once stabilized, she underwent bilateral thrombofragmentation, pulmonary thrombolysis in situ with alteplase (10 mg left ap and 5 mg right ap) (Fig. 2) and vena cava filter placement was performed without complications. Post procedure the systolic and/or diastolic and/or mean pulmonary pressure was of 55/18/30 mmHg, respectively.

Provoked causes of venous thromboembolism were dismissed. Infectious diseases and hereditary thrombophilia was ruled out. She was discharged with vitamin k antagonist. Megaloblastic anemia was confirmed with multisegmented neutrophils in blood smear. Aspirate of bone marrow was negative for malignancy. B12 levels were measured, and were found below reference values (20 ng/l). Endoscopy and colonoscopy were normal, atrophic gastritis was ruled out. It was determined that the cause of pulmonary embolism was megaloblastic anemia since there were no other identifiable causes. After 2 years of follow-up, she remains without new episodes of venous embolism. She developed an iron deficiency anemia, and is being replaced with iron, B12 and folic acid (Table 1).

Discussion

A first event of unprovoked pulmonary embolism should raise the suspicion of B12 deficiency in the presence of megaloblastic anemia. B12 deficiency has 2 important components that are usually unrecognized: the prothrombotic potential and the ability to simulate a microangiopathic hemolytic anemia. B12 deficiency is generally underdiagnosed and undertreated. It increases homocysteine plasma levels, a highly known risk factor for venous embolism. Homocysteine interferes with activation of factor Va, by increasing levels of protein C, apart from increasing the expression of tisular factor and suppressing sulfate heparin, an endogenous anticoagulant [1–3].

Although our patient had biochemical findings of hemolysis, peripheral smear did not show typical fragmented erythrocytes, which can relate to the term pseudo-

Download English Version:

<https://daneshyari.com/en/article/10222552>

Download Persian Version:

<https://daneshyari.com/article/10222552>

[Daneshyari.com](https://daneshyari.com)