

Available online at www.sciencedirect.com

ScienceDirect

journal homepage: www.elsevier.com/locate/radcr

Case Report

Uterine anteversion after uterine fibroid embolization

Driss Raissi, MD^a, Qian Yu, BS^{b,*}, Qiong Han, MD^a^a Department of Radiology, University of Kentucky, 800 Rose Street HX315E, Lexington, KY 40506 USA^b College of Medicine, University of Kentucky, 800 Rose Street HX315E, Lexington, KY 40506 USA

ARTICLE INFO

Article history:

Received 10 July 2018

Revised 10 August 2018

Accepted 12 August 2018

Keywords:

Anteverted uterus

Retroverted uterus

Anteversio

UFE

Flipped uterus

Tipped uterus

ABSTRACT

Uterine fibroid embolization has been proven effective in treating symptomatic uterine fibroids for appropriately selected patients as an alternative option to surgical approaches. The most common adult uterine position is anteverted followed by a retroverted uterus which can be found in roughly 15%–20% of normal adult females. The positioning of the uterus can change from anteversion to retroversion due to the filling of bladder or during pregnancy; however, changing from retroverted to anteverted position without prior pregnancy or endometriosis is rather uncommon. Here, we describe a case of uterine orientation change from retroversion to anteversion presenting 6 months after uterine fibroid embolization.

© 2018 The Authors. Published by Elsevier Inc. on behalf of University of Washington.

This is an open access article under the CC BY-NC-ND license.

(<http://creativecommons.org/licenses/by-nc-nd/4.0/>)

Introduction

Uterine fibroid embolization (UFE) has been proven effective in treating symptomatic uterine fibroids for appropriately selected patients as an alternative option to surgical approaches [1–3]. The most common adult uterine position is anteverted followed by a retroverted uterus which can be found in roughly 15%–20% of normal adult females [4]. The positioning of the uterus can change from anteversion to retroversion due to the filling of bladder or during pregnancy; however, changing from retroverted to anteverted position without prior pregnancy or endometriosis is rather uncommon. Here, we describe a case of incidental uterine anteversion presenting 6-months after UFE.

Case report

Forty-six-year old nulliparous female, status post prior myomectomy for dysfunctional uterine bleeding presented to our multidisciplinary uterine fibroid clinic with menometrorrhagia. Patient's preprocedural magnetic resonance imaging (MRI) revealed multiple intramural fibroids within an overall enlarged retroverted uterus measuring 9 cm × 6.3 cm × 5 cm. The largest fibroid which we termed the index fibroid was located within the uterine fundus and measured 2.3 cm × 2.1 cm × 2 cm. The second largest fibroid was located anteriorly and measured 1.8 cm × 1.7 cm × 1.5 cm. Both fibroids demonstrated post contrast isoenhancement compared to the

* Corresponding author.

E-mail address: qyu227@uky.edu (Q. Yu).<https://doi.org/10.1016/j.radcr.2018.08.009>1930-0433/© 2018 The Authors. Published by Elsevier Inc. on behalf of University of Washington. This is an open access article under the CC BY-NC-ND license. (<http://creativecommons.org/licenses/by-nc-nd/4.0/>)

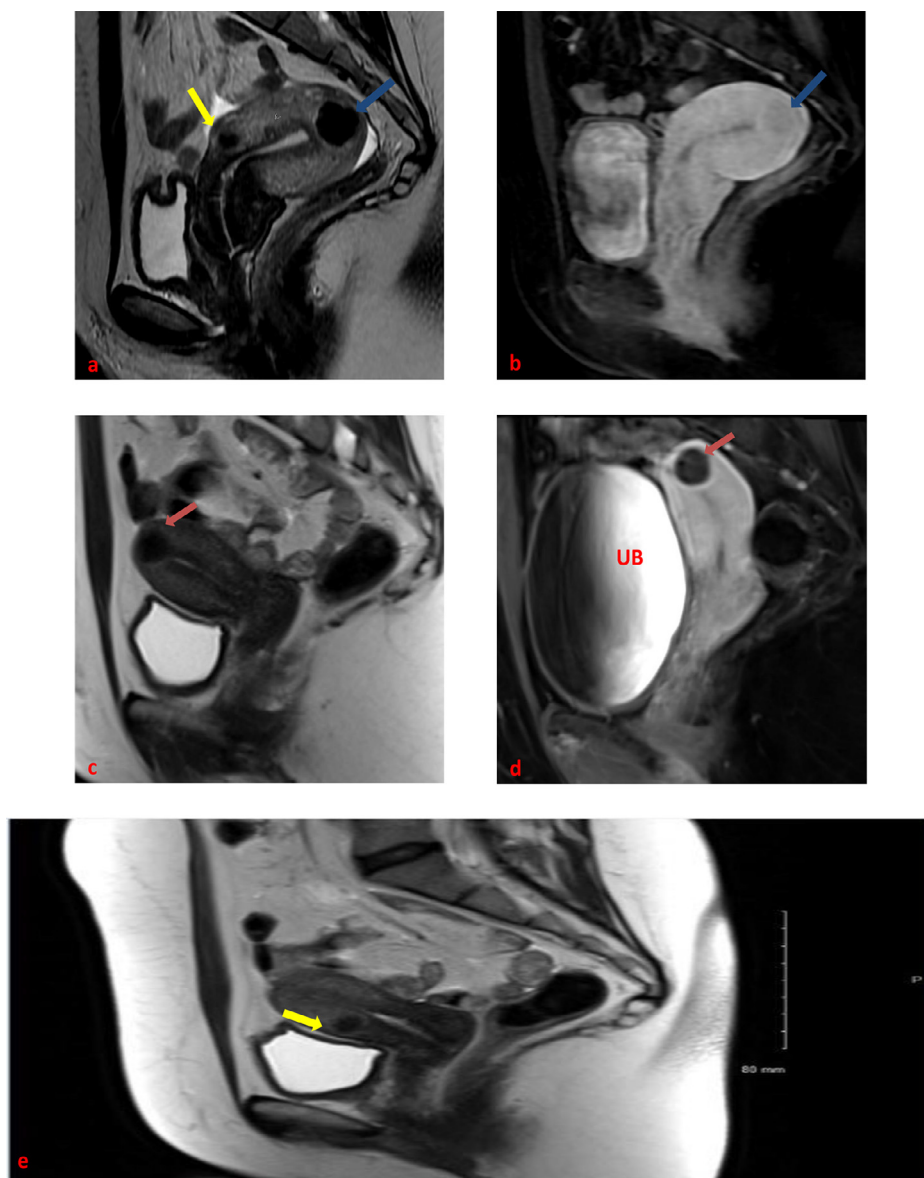


Fig. 1 – Forty-six-year-old female with multiple fibroids before and after embolization: pre-UFE T2-weighted (a) and postgadolinium T1-weighted (b) sagittal images showing an enhancing intramural fundal fibroid (blue arrows) within a retroverted uterus. An anteriorly located fibroid with similar imaging features can also be seen on pre-UFE imaging (yellow arrow). (For interpretation of the references to colour in this figure legend, the reader is referred to the web version of this article).

background myometrium. Other much smaller intramural fibroids we also noted. (Fig. 1 a and b).

All treatment options were reviewed with the patient, including myomectomy, hysterectomy, hormonal therapies, and uterine fibroid embolization. Patient decided to proceed with UFE. Pre procedural work-up included a pelvic MRI with and without contrast enhancement, a Pap smear and an endometrial biopsy. Tissue results were negative for atypia and/or malignancy. A routine UFE was carried out with selective left uterine artery embolization followed by right uterine artery embolization from right common femoral artery access, using multiple vials of 500-700 microns Embosphere (Embospheres, Biosphere Medical, Rockland, MA) particles followed by 700-

900 microns Embosphere (Embospheres, Biosphere Medical, Rockland, MA) particles. Embolization proceeded to near stasis for both uterine arteries. (Fig. 2)

At our institution, patients undergoing UFE are given epidural patient-controlled analgesia post procedurally and admitted for 23-hour observation. In our case, the patient's subsequent hospitalization course was uneventful with well-controlled post procedural pain. The patient came back to our multidisciplinary clinic for her 6-month post UFE follow-up. She reported complete resolution of her original presenting symptoms, including her menstrual pain and heavy bleeding. Her 6-months post UFE contrast enhanced MRI images showed complete devascularization and shrinkage of her

Download English Version:

<https://daneshyari.com/en/article/10222574>

Download Persian Version:

<https://daneshyari.com/article/10222574>

[Daneshyari.com](https://daneshyari.com)