

Accepted Manuscript

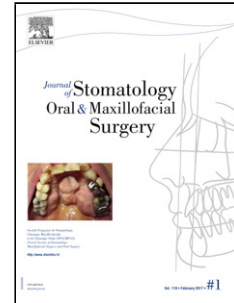
Title: Para commissural cleft of the lower lip: a first case described in the literature

Author: Julie Chauvel-Picard Arnaud Gleizal

PII: S2468-7855(18)30078-8

DOI: <https://doi.org/doi:10.1016/j.jormas.2018.04.003>

Reference: JORMAS 170



To appear in:

Received date: 17-2-2018

Accepted date: 6-4-2018

Please cite this article as: Julie Chauvel-PicardArnaud Gleizal Para commissural cleft of the lower lip: a first case described in the literature (2018), <https://doi.org/10.1016/j.jormas.2018.04.003>

This is a PDF file of an unedited manuscript that has been accepted for publication. As a service to our customers we are providing this early version of the manuscript. The manuscript will undergo copyediting, typesetting, and review of the resulting proof before it is published in its final form. Please note that during the production process errors may be discovered which could affect the content, and all legal disclaimers that apply to the journal pertain.

Para commissural cleft of the lower lip : a first case described in the literature

Julie CHAUVEL-PICARD, MD ^{a-b}, Arnaud GLEIZAL, MD, PhD ^{a-b-c}

a. Department of Cranio-Maxillo-Facial Surgery of the pediatric hospital, Hôpital Femme Mère Enfant, 59 Boulevard Pinel, 69677 BRON, France

b. Université Claude Bernard Lyon 1, 43 Boulevard du 11 Novembre 1918, 69100 Villeurbanne

c. INSERM, National Institute of Health and Medical Research, Unit 1032, 151 Cours Albert Thomas 69424 LYON CEDEX 03

Corresponding Author :

Dr CHAUVEL-PICARD Julie

Service de Chirurgie Maxillo-Faciale pédiatrique

Hôpital Femme Mère Enfant

59 Boulevard Pinel

69677 Bron, France

Mail : Julie.chauvelpicard@gmail.com

Phone : 33 (0)6 24 28 21 86

Abstract:

We described the first case of para-commissural cleft of the lower lip in a 2 year-old child. He is from a trichorionic triamniotic triplet pregnancy after ovarian stimulation. He has no history except a selective fetal reduction of the mother. We correct this cleft of the lower lip with a double plasty of Malek. The functional and aesthetic result is satisfactory. This particular cleft can not be explained by the embryological theory. We favor two hypothesis to explain this anomaly: a vascular origin with the stapedia artery and the selective fetal reduction.

Key words: facial cleft; paracommissural cleft; cleft lip; multifetal pregnancy reduction; selective fetal reduction

Introduction:

Download English Version:

<https://daneshyari.com/en/article/10224564>

Download Persian Version:

<https://daneshyari.com/article/10224564>

[Daneshyari.com](https://daneshyari.com)