Journal of Forensic Radiology and Imaging 5 (2016) 31–37

Contents lists available at ScienceDirect

Journal of Forensic Radiology and Imaging

journal homepage: www.elsevier.com/locate/jofri

Case report

Biological profiling of Richard III using post-mortem computed tomography scanning

A. Brough [a,*], B. Morgan [b], C. Robinson [c], J. Appleby [d], R. Buckley [d], G. Rutty [a]

[a] University of Leicester, East Midlands Forensic Pathology Unit, Robert Kilpatrick Building, Leicester LE2 7LX, United Kingdom
[b] University of Leicester, Radiology Department, Robert Kilpatrick Building, Leicester LE2 7LX, United Kingdom
[c] Imaging Department, University Hospitals of Leicester, Leicester Royal Infirmary, Leicester LE2 7LX, United Kingdom
[d] University of Leicester, School of Archaeology and Ancient history, University Road, Leicester LE1 7RH, United Kingdom

ARTICLE INFO

Article history:
Received 15 October 2015
Received in revised form
12 January 2016
Accepted 14 January 2016
Available online 15 January 2016

Keywords:
Richard third
Post-mortem computed tomography
Identification
Anthropology
Biological profiling

ABSTRACT

In August 2012 a skeleton was excavated in Leicester that was subsequently identified as that of Richard III, the last King of England to die in battle. In addition to a traditional full osteological analysis, an independent osteological assessment was undertaken using post-mortem computed tomography (PMCT). This publication presents the methods that were used for the PMCT examination of the skeleton, the results achieved and a comparison to the traditional osteological results. The results from the PMCT examination are comparable to those achieved from the osteological examination, but were carried out remotely, with no contact with the remains. This system is therefore extremely beneficial when dealing with fragile remains, particularly those of great historic significance.

1. Introduction

In August 2012 a skeleton was excavated in Leicester that was subsequently identified as that of Richard III, the last King of England to die in battle. The identification was achieved using primary, secondary and tertiary identifiers [1], including a DNA match with modern maternal-line relatives [2], archaeological evidence of the burial structure and location, and osteological analysis of the skeleton, respectively.

As part of the identification process a traditional osteological analysis of the entire skeletal remains was undertaken. In addition to this an independent osteological assessment was undertaken using post-mortem computed tomography (PMCT), blinded to the results of the traditional analyses. At the time of data analysis the suspected identity of the skeleton was also unknown. We present the method used for the PMCT assessment, the results achieved and a comparison to the traditional osteological assessment.

2. Materials and methods

2.1. Osteological analysis

Standard osteological methods were used, by direct observations of the skeletal remains, by a certified osteologist. Age was determined from the auricular surface of the ilium [3], the pubic symphysis [4], fusion of the medial clavicular epiphysis [5] and the development of the dentition. Osteological sex was determined from the pelvis, following the criteria set out by Phenice [6] and Brickley, 2004; and skull, from cranial characteristics described by Buikstra and Ubelaker [7] and characteristics of the mandible (relevant to British skeletal populations) in line with Brickley [8]. Metric analysis was also performed using the calculations denoted by Buikstra and Ubelaker [7]. Stature calculations were made using Trotter and Gleser's [9] recommendations for white males. Non-metric traits were recorded following the guidelines of Brothwell and Zakrzewski [10].

2.2. Post-mortem computed tomography

The PMCT image data were reviewed by an anthropologist experienced in PMCT, independent to the later known identification of the skeleton and to the biological profile determined by the traditional, dry bone osteological examination. The complete

* Corresponding author.
E-mail address: alb39@le.ac.uk (A. Brough).

http://dx.doi.org/10.1016/j.jofri.2016.01.003
2212-4780/© 2016 Published by Elsevier Ltd.

Fig. 1. Specially designed polystyrene mould to hold the bones in a truer anatomical position.

skeleton underwent PMCT examination. During the first scanning session, the bones were laid out in anatomical position. All bones were scanned with an Aquilion 64-slice scanner (Toshiba, Zoetermeer, Netherlands; 100 and 135 kVp; 60 mA; thickness 0.5 mm; matrix 512 × 512), reconstructed to 0.5 mm or 1 mm. After analysis of this scan, the bones were scanned again on a specially designed polystyrene mould to hold the bones in a truer anatomical position (Fig. 1). The limbs, pelvis, spine, and head were scanned separately (100 kVp; 40 mA; reconstructed to 0.5 mm). The anonymized DICOM images were then transferred to an Apple Mac Pro workstation, and the radiograph data was processed for analysis using OsiriX 3D imaging software (version 3.7.1; distributed as open-source software under the GNU licensing scheme at the following Web site: http://homepage.mac.com/rossetantoine/osirix. Pixie: Switzerland).

A 'minimum data set' biological profiling form was constructed as described by Brough et al. [11]. As the remains in question were fully skeletonised (i.e. had no soft tissue remaining), and were not complete, the form was modified accordingly. The 3D skeletal view of the whole body was used to identify anti-, peri- and post mortem skeletal trauma (discussed in more detail in following sections), and congenital or acquired bone disease, for example scoliosis. The second page of the form included (where available), 7 views detailing the complete morphology of the skull; all the long bones and their measurements; a clear view of each joint of the shoulder, elbow, hip and knee; an isolated view of the hand, foot, pelvis and rib ends; the spine, sacrum and axis; and finally, dental orthopantomograms (OPT) reconstructions. The final minimum data-set form for the remains in question is illustrated in Figs. 2 and 3.

A total of 12 peri-mortem injuries were also identified on the minimum-data set form, nine to the skull and three to the post-cranial skeleton. This prompted a request for supplementary images, which were subsequently provided (from the same/original dataset), for a more comprehensive final anthropological report (Fig. 4).

3. Results and discussion

3.1. Skeletal preservation/completeness

The skeleton was generally well preserved and largely complete (Fig. 2). The distal tibiae and right fibula showed post-mortem breaks in the distal shafts, with the distal ends missing. The feet were missing, as was the left fibula, as discussed in a separate publication [12]. The right trapezium, trapezoid and pisiform bones were missing, as were one intermediate phalanx and nine distal phalanges.

There were two sites of damage caused during unearthing and excavation. The left tibia was crushed and a blow to the left side of the skull caused minor damage to the area of the coronal suture.

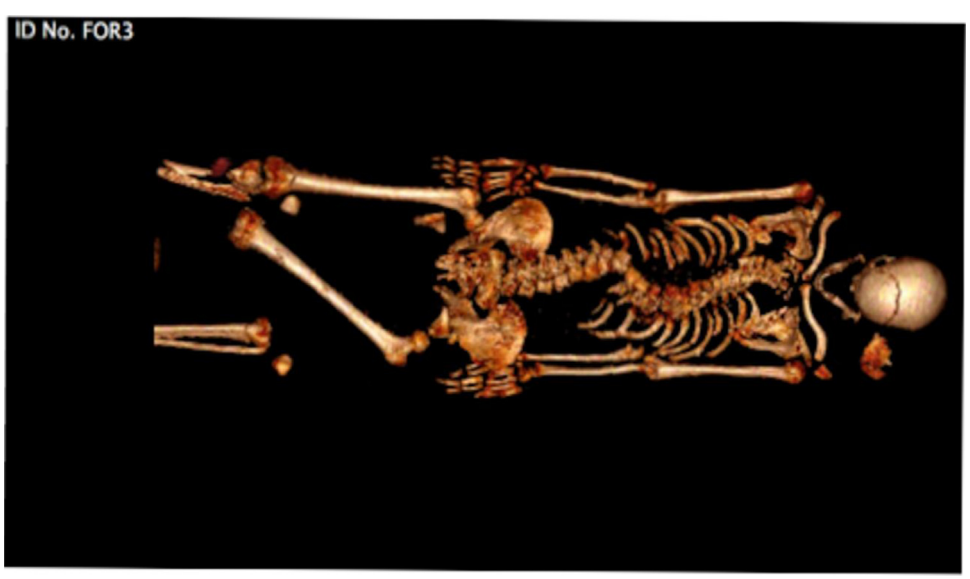

Fig. 2. Minimum data set anthropological reporting form: page 1.