Legal Medicine 21 (2016) 38–44

Contents lists available at ScienceDirect

Legal Medicine

journal homepage: www.elsevier.com/locate/legalmed

Case Report

An autopsy case of acetyl fentanyl intoxication caused by insufflation of 'designer drugs'

Izumi Takase [a,*], Takako Koizumi [b], Ihoko Fujimoto [a], Aya Yanai [a], Tatsuya Fujimiya [a]

[a] Department of Legal Medicine, Yamaguchi University Graduate School of Medicine, Japan
[b] Forensic Science Laboratory, Yamaguchi Prefectural Police Headquarters, Japan

ARTICLE INFO

Article history:
Received 19 November 2015
Received in revised form 16 May 2016
Accepted 18 May 2016
Available online 18 May 2016

Keywords:
Acetyl fentanyl
Designer drugs
Insufflation
Naloxone

ABSTRACT

We present a fatal case of intoxication due to insufflation of acetyl fentanyl. His blood concentration of acetyl fentanyl was 270 ng/mL, and the manner of death was classified as an accident. This is the first report of an autopsy case of acetyl fentanyl delivered by insufflation, rather than intravenous administration. He had been snoring loudly for at least 12 h prior to death, and transport to a hospital during this time and treatment with naloxone may have saved his life. In this sense, it can be said that his death was preventable.

This case reemphasizes the risk of death associated with drug overdose and the narrow range of acetyl fentanyl between the effective dose (ED50) and lethal dose (LD50). The case should also raise awareness among medical professionals of the effectiveness of naloxone and the need to establish a comprehensive system for toxicological analysis while keeping the possibility of use of 'designer drugs' in mind.

1. Introduction

Acetyl fentanyl [*N*-(1-phenethylpiperidin-4-yl)-*N*-phenylacetamide] is a synthetic fentanyl analogue in which the propionyl moiety of fentanyl is replaced with an acetyl moiety [1]. This compound has emerged in the international drug scene within the last decade [2]. Fentanyl is used as a general anesthetic and as a strong analgesic for postoperative or cancer pain, whereas acetyl fentanyl is not available as a prescription drug. With increasing use of the Internet, 'designer drugs' containing acetyl fentanyl can be easily purchased on websites, and the risk of these drugs seems to be underestimated. In the United States, 14 overdose death cases were reported in Rhode Island from March through May 2013 [3]. Uchiyama et al. reported that acetyl fentanyl was first identified in illegal products available in Japan in 2014 [4]. Acetyl fentanyl is thought to act as a μ-opioid receptor agonist and is associated with euphoria, drowsiness, and respiratory depression [5]. The range between the effective dose (ED_{50}) and lethal dose (LD_{50}) is narrower than that of morphine [1].

Here, we present the first report of an autopsy case of acetyl fentanyl intoxication by insufflation.

* Corresponding author at: Department of Legal Medicine, Yamaguchi University Graduate School of Medicine, 1-1-1 Minami-Kogushi, Ube, Yamaguchi 755-8505, Japan.

E-mail address: takase@yamaguchi-u.ac.jp (I. Takase).

http://dx.doi.org/10.1016/j.legalmed.2016.05.006
1344-6223/

2. Case report

2.1. History

A 34-year-old plasterer was found by his mother on his bed in a supine position, with his head lower than the rest of his body and located between the bed and the wall. There was a moderate amount of vomit on the floor beneath his head. His mother immediately performed external cardiac massage and called an ambulance. When the emergency medical technicians arrived at the scene, they confirmed that rigor mortis had already set in and did not transport him to hospital. According to the bereaved, he had been snoring loudly for at least 12 h before death. A police investigation of his room revealed the presence of 'designer drugs' [Fig. 1] and insufflation straws in his bag and in the drawers of a chest. He had been working at several different construction sites from early morning until midnight without a holiday for about a year. However, he had recently been less busy and he had finished before midnight for the last few months.

2.2. Autopsy findings

The height and weight were 163 cm and 63 kg, respectively, with normal nutritional status. The face and neck region was congested. Moderate postmortem lividity appeared on the back side.

Fig. 1. The package of 'designer drugs' containing acetyl fentanyl as the main ingredient found in the room of the deceased.

An external examination showed neither obvious needle track marks nor injury. Both lungs were heavy (left 590 g, right 780 g) and macroscopically moderately to severely edematous with mild to severe intraalveolar hemorrhage depending on the site, moderate emphysematous changes, and a moderate to large number of intraalveolar hemosiderin-laden macrophages on histological examination [Fig. 2a, b]. The enlarged heart weighed 530 g, and moderate to diffuse interstitial fibrosis and fatty infiltration of the right ventricle were observed microscopically [Fig. 3a, b]. The liver weighed 1610 g, was swollen, and showed a tendency for fibrosis on microscopic examination. The brain weighed 1430 g and was also swollen. No other organs showed notable findings.

2.3. Toxicological findings

An Oasis® HLB column (Waters, Milford, MA) was preconditioned with 1 mL of methanol followed by 1 mL of distilled water. Cardiac blood from the right ventricle, gastric contents or urine obtained at autopsy (1 mL each) was loaded onto the column and retained. Methanol (5%) in water wash solvent was applied. The column was eluted with methanol and the eluate was evaporated to dryness under reduced pressure. The residue was dissolved in 0.2 ml of methanol and qualitatively analyzed by gas chromatography mass spectrometry (GC/MS) and liquid chromatography–tandem mass spectrometry (LC/MSMS).

Cardiac blood (500 μL) was diluted with an equal quantity of distilled water. The diluted solution was mixed with 0.5 g of potassium carbonate and 0.1 mL of ethyl acetate by brief vortexing and then centrifuged at 10,000 rpm for 10 min. The supernatant was

a

b

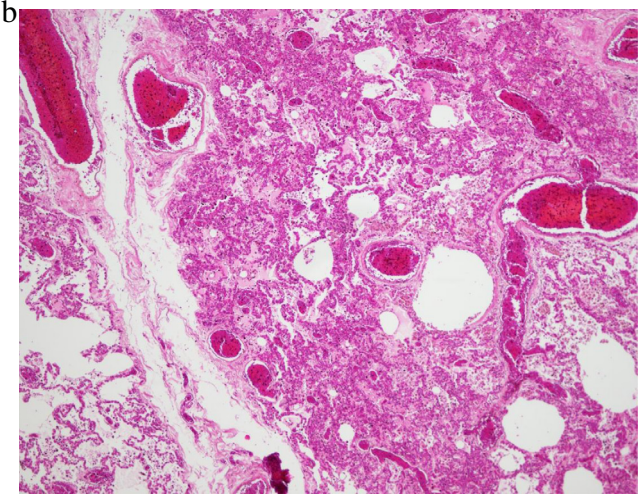

Fig. 2. a. Cut surface of each lung. b. Histological findings for the lung [HE staining, ×40].

a

b

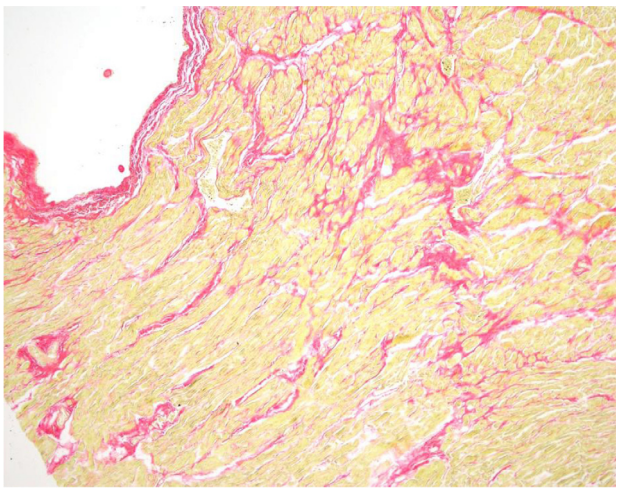

Fig. 3. a. Surface of the heart. b. Histological findings around the AV node showed moderate to diffuse interstitial fibrosis (indicated by red staining regions) [Sirius Red staining, ×40].