Legal Medicine 21 (2016) 45–52

Contents lists available at ScienceDirect

Legal Medicine

journal homepage: www.elsevier.com/locate/legalmed

# Assessment of sex in a modern Turkish population using cranial anthropometric parameters

Oguzhan Ekizoglu [a,*], Elif Hocaoglu [b], Ercan Inci [b], Ismail Ozgur Can [c], Dilek Solmaz [d], Sema Aksoy [b], Cudi Ferat Buran [c], Ibrahim Sayin [e]

[a] Department of Forensic Medicine, Tepecik Training and Research Hospital, Izmir, Turkey
[b] Department of Radiology, Bakirkoy Dr. Sadi Konuk Training and Research Hospital, Istanbul, Turkey
[c] Department of Forensic Medicine, Dokuz Eylul University, Faculty of Medicine, Izmir, Turkey
[d] Department of Rheumatology, Katip Celebi University, Faculty of Medicine, Izmir, Turkey
[e] Department of Head and Neck Surgery, Bakirkoy Dr. Sadi Konuk Training and Research Hospital, Istanbul, Turkey

ARTICLE INFO

*Article history:*
Received 18 January 2016
Received in revised form 31 May 2016
Accepted 2 June 2016
Available online 3 June 2016

*Keywords:*
Sex determination analysis
Cranium
Forensic anthropology
Multidetector computed tomography

ABSTRACT

The utilization of radiological imaging methods in anthropometric studies is being expanded by the application of modern imaging methods, leading to a decrease in costs, a decrease in the time required for analysis and the ability to create three-dimensional images. This retrospective study investigated 400 patients within the 18–45-years age group (mean age: 30.7 ± 11.2 years) using cranial computed tomography images. We measured 14 anthropometric parameters (basion-bregma height, basion-prosthion length, maximum cranial length and cranial base lengths, maximum cranial breadth, bizygomatic diameter, upper facial breadth, bimastoid diameter, orbital breadth, orbital length, biorbital breadth, interorbital breadth, foramen magnum breadth and foramen magnum length) of cranial measurements. The intra- and inter-observer repeatability and consistency were good. From the results of logistic regression analysis using morphometric measurements, the most conspicuous measurements in terms of dimorphism were maximum cranial length, bizygomatic diameter, basion-bregma height, and cranial base length. The most dimorphic structure was the bizygomatic diameter with an accuracy rate of 83% in females and 77% in males. In this study, 87.5% of females and 87.0% of males were classified accurately by this model including four parameters with a sensitivity of 91.5% and specificity of 85.0%. In conclusion, CT cranial morphometric analysis may be reliable for the assessment of sex in the Turkish population and is recommended for comparison of data of modern populations with those of former populations. Additionally, cranial morphometric data that we obtained from modern Turkish population may reveal population specific data, which may help current criminal investigations and identification of disaster victims.



## 1. Introduction

The assessment of sex is important in forensic science. Morphological methods must be objective; their reliability needs to be reviewed in terms of factors that influence an individual's physical development, including geographical features, nutrition and race [1–3]. Even if morphometric analyses seem to provide reliable results, use of morphological and metric methods together will increase the success rate of sex assessment [1–4]. Statistical analysis of the results of morphological measurements, discriminatory functional analysis, and logistic regression analysis assists researchers. Both analyses have attracted attention as an important method in cranial morphometric investigations [3–8,42,43].

Although important data can be obtained by analyzing DNA from bones, contamination, technical difficulties, high costs and other factors—including mutations, incorrect coding and artificial conditions that may cause mistakes in assessment—are important limitations [9–14]. All currently available methods have limitations; therefore, combining genetic and morphometric methods may increase the success rate.

The cranium is one of the skeletal regions used most frequently to determine sex. Developmentally, with the transition to adulthood, female skull preserves some prepubertal properties like smoothness and gracility. In addition, in males the cranium is robuster and involves larger muscle attachment areas [4–6]. Research has shown that the cranium is the next best contributor

* Corresponding author at: Department of Forensic Medicine, Tepecik Training and Research Hospital, Güney Mahallesi 1140/1, Yenisehir, Konak, Izmir, Turkey.
*E-mail address:* drekizoglu@gmail.com (O. Ekizoglu).

http://dx.doi.org/10.1016/j.legalmed.2016.06.001
1344-6223/

of sex assessment after the pelvis. Krogman and Iscan [1] reported that sex could be determined from the pelvis with accuracy of 95%, and from the cranium with the accuracy of 92%. Cranium investigations depend on morphometric analyses, and their accuracy rate in different populations has been investigated. Researchers have reported an accuracy rate of >80% in Cretan [3], Afro-American [7], South African [8,15], Indian [16], Japanese [17], and Australian [18] populations. On the other hand, we didn't see any study which reveals multiparametric cranial morphometric data belong to Turkish population in searching of literature.

In morphometric analyses, the use of radiological methods such as computed tomography (CT) and MRI, together with direct observational studies, is striking [19–26]. In living individuals many radiological imaging techniques are performed, and their frequency of use is increasing [29]. In studies that involve generation of a database, radiological imaging is invaluable as it enables thin slicing and three-dimensional assessments, which reduce costs, increase the speed of analysis; avoid ethical concerns regarding postmortem maceration [19–24]. Radiological data are consistent with measurements derived using callipers. Fatah et al. [27] showed that caliper- and CT-derived data on cranial base length, maximum cranial length, bizygomatic breadth, and foramen magnum length, were in good agreement. The mean measurement error was <2 mm; no significant between-method difference in measurements was evident.

Our study presents the value of 14 different metric parameters measured radiologically belong to cranium about sexual dimorphism in contemporary Turkish population. The importance of this study is the potential of contributing to the population specific standards for Turkish population. The objective of this study was to develop an anthropometric method for sex assessment in the contemporary-Turkish population standards by using cranium measurements and a logistic regression analysis.

## 2. Materials and methods

The present study was conducted at the Bakirköy Dr. Sadi Konuk Teaching and Research Hospital. All medical records and cranial CT images of patients admitted to the Emergency Service Department and outpatient clinics of the hospital, from June 2014 and January 2015, with diagnoses of trauma, were retrospectively evaluated. Cases that had fracture, surgery, congenital or an acquired anomaly in the craniofacial region were excluded from the study (108 cases). Additionally, cases less than 18 years old were excluded by reason of characteristics of skeletal development in childhood and adolescence [4,6]. Index population consists of individuals consulted from different regions of Turkey and was considered as representative of Turkish population. The study protocol was approved by the hospital Ethics Board. Finally, 400 patients with an age range of 18–45 years (200 males, mean age: 30.1 ± 15.9 and 200 females, mean age: 31.6 ± 16.6 and overall mean age for both sexes was 30.7 ± 11.2 years.) were included.

Multi-detector CT (MDCT) examinations were performed using a 128-slice MDCT scanner (Siemens Medical Solutions, Erlangen, Germany). All scans were obtained with the patients supine, head first, using the following parameters: tube voltage, 120 kV; 150 effective mAs; slice thickness 1 mm. MDCT images were obtained using 3D reconstructions and a volume-rendering technique (VRT). We measured 14 cranial parameters. Each measurement was performed according to the introduced by Buikstra and Ubelaker [37], Moore-Jansen et al. [38], Martin and Saller [39], and Howells [40]. The definitions of the measurements are defined in Table 1. Each measurement was performed by researchers manually at Leonardo workstation. As measurements were being made, appropriate one was chosen from sagittal, coronal and axial techniques for images in which measurement points could be best detected according to measurement suggestions presented by previous studies. As a result the maximum cranial length (Fig. 1) and basion-bregma height, basion-prosthion length, cranial base lengths (Fig. 2) were measured using the sagittal images. The maximum cranial breadth, bizygomatic diameter, upper facial breadth (Fig. 3) and bimastoid diameter (Fig. 4), orbital breadth and orbital height (Fig. 5), biorbital breadth (Fig. 6) and interorbital breadth (Fig. 7) were measured using the coronal images. The foramen magnum breadth and foramen magnum length (Fig. 8) were measured using axial images.

In this study, all of the CT images were assessed by two radiologists. Both were experienced in musculoskeletal CT assessments. Two weeks after the first radiology assessment of the CT images,

**Table 1**
Definitions of cranial measurements.

| Measurements | Distance |
|---|---|
| Maximum cranial length | Distance between glabella and opisthocranion |
| Maximum cranial breadth | Distance between euryon and euryon |
| Bizygomatic diameter | Distance between most lateral points on the zygomatic arches |
| Basion-bregma height | Distance from the lowest point on the anterior margin of foramen magnum (ba), to bregma |
| Cranial base length | Distance from nasion to basion |
| Basion-prosthion length | Distance from basion to prosthion |
| Upper facial breadth | Distance between the two external points on the frontomalar suture |
| Bimastoid diameter | Distance between points of the mastoid processes |
| Orbital breadth | Distance from dacryon to ectoconchion |
| Orbital height | Distance between the superior and inferior orbital margins |
| Biorbital breadth | Distance between right and left ectoconchion |
| Interorbital breadth | Distance between right and left dacryon |
| Foramen magnum length | Distance from basion to opisthion |
| Foramen magnum breadth | Distance between the lateral margins of foramen magnum at the points of greatest lateral curvature |

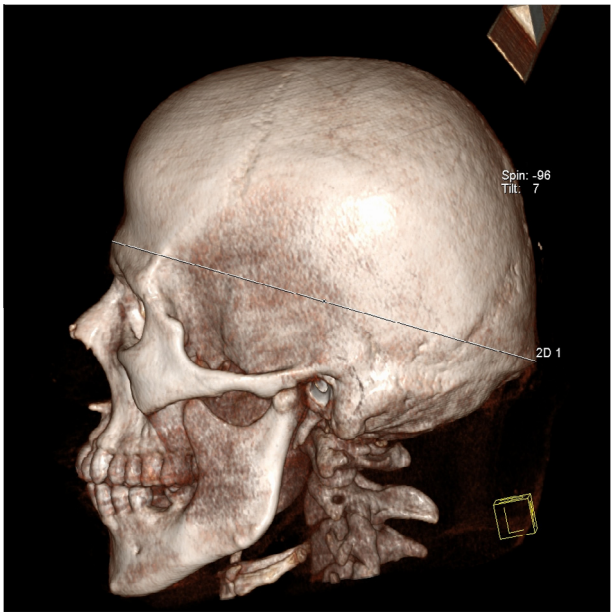


**Fig. 1.** D1: Maximum cranial length.