Legal Medicine 21 (2016) 58–63

Contents lists available at ScienceDirect

Legal Medicine

journal homepage: www.elsevier.com/locate/legalmed

Estimation of stature and sex from scapular measurements by three-dimensional volume-rendering technique using in Chinese

Kui Zhang [a,1], Jing-hui Cui [a,1], Ying-zhen Luo [a], Fei Fan [a], Ming Yang [b], Xing-hai Li [b], Wei Zhang [c], Zhen-hua Deng [a,d,*]

[a] Department of Forensic Pathology, West China School of Preclinical and Forensic Medicine, Sichuan University, Chengdu, Sichuan 610041, PR China
[b] Nan Chong Public Security Bureau, Nan Chong, Sichuan 610000, PR China
[c] Department of Forensic Medicine, North Sichuan Medical College, Nan Chong, Sichuan 610000, PR China
[d] Shanghai Key Laboratory of Forensic Medicine, Institute of Forensic Science, Ministry of Justice, PR China

ARTICLE INFO

Article history:
Received 26 April 2016
Received in revised form 21 June 2016
Accepted 22 June 2016
Available online 23 June 2016

Keywords:
Forensic anthropology
Sexual dimorphism
Stature estimation
Scapula
Discriminant function analysis
Regression equations

ABSTRACT

In order to develop population – specific discriminant function equations and stature prediction equations for predicting sex and stature from measurements of the scapula in a contemporary Chinese, 414 individual 3D CT images were collected from participants undergoing routine examination. Sex differences for the variables were tested by Student's *t*-test. Fisher's method has been followed for discriminant analysis. Regression analysis was applied to match the six linear parameters against stature. The stepwise analysis of all measurements yielded a sex classification accuracy rate of 86.7% and a sex bias of 3.1%. All the classification accuracy rates of the univariate discriminant function analyses are of more than 80%. For stature estimation, the accuracy of stature prediction ranged from 5.252 to 7.210 cm for male, from 4.630 to 6.484 cm for female, respectively. This paper provides indications that the scapula is an important bone for sex diagnosis and it could be effectively used as alternatives in forensic cases. Furthermore, the equations presented for stature estimation in this study should be used as alternatives in forensic cases when long bones were unavailable for stature estimation.

1. Introduction

Individual identification is one of the most challenge aspects of forensic science. The sex, age, ethnic background and stature are four main attributes of biological identity that forensic investigators try to determine. Accurate sex estimation based on measurements of dimorphic dimensions in unknown human remains is a crucial first step toward making individual identification because the estimation of stature and age at death is usually performed using sex-specific standards [1–3].

Associated with the highest accuracy levels, the skull and pelvis are widely acknowledged as the most useful skeletal regions for sex estimation [4,5]. And also, due to accurate estimates to be made, several authors have proposed formulae for stature estimation based on measurements of the lengths of different long bones [6–12]. However, taphonomic processes such as decomposition and carnivore modification may damage these bones [13].

In cases where the skull and pelvis are unavailable, other parts of the human skeleton should be used for sex estimation. Previous studies have focused on estimating sex from various skeletal parts such as the humerus, radius, ulna, femur, tibia, talus, metatarsals, sternum, and ribs [14–26]. In many cases long bones are found to be fractured or in an otherwise unsuitable condition for anthropometric analysis and so, the skull [27–29] and various short bones [30–39], such as the sternum, hand or metatarsal bones have been considered as alternative skeletal elements to analyze for stature estimation.

In concordance with these theories that the morphological changes of the scapula are negligible during life after development is complete [40], and by the scenario that where flat and short bones seem to be better preserved than long bones in cases of chattered bodies [3], some studies previously examined sexual dimorphism [6,17,18,41,42] and stature estimation [40,43] of the scapula in different populations. However, osteometric standards cannot be accurately applied to other disparate samples, as human groups differ with regard to body size [44]. In addition, populations may experience secular variation, and thus the use of temporally

* Corresponding author at: Department of Forensic Pathology, West China School of Preclinical and Forensic Medicine, Sichuan University, Chengdu 610041, PR China.
E-mail address: newman-zhk@163.com (Z.-h. Deng).
[1] These authors contributed equally to this work.

http://dx.doi.org/10.1016/j.legalmed.2016.06.004
1344-6223/

representative skeletal collections is required for the derivation of anthropological standards [45,46].

Forensic investigation of cases in which human remains have been skeletonized basically rely on biological profiles. For individual identification, traditional techniques are more commonly used than more accurate approaches such as DNA analysis [47]. The biological profiles which used for individual identification can be acquired from direct measurements, radiographs, the ultrasound attenuation detecting results, CT scans, or MRI images. Skeletal measurements based on CT scan images could be standardized because the anatomical landmarks are easy to locate. The 3D images of bones can immediately be generated from MDCT data using CT values, and therefore, forensic researchers are able to collect contemporary population-specific data using MDCT scanning and formulate standards for the estimation of biological profiles in the skeleton, including sex [19,48] and stature [49–51].

Therefore, the objective of the present study was to develop population - specific discriminant function equations and stature prediction equations for predicting sex and stature from measurements of the scapula in a contemporary Chinese by using three-dimensional volume-rendering technique.

2. Materials and methods

The data used in the present study were obtained from participants undergoing routine examination at the West China Hospital of Sichuan University. The study sample comprised 414 individuals in China, including 190 females and 224 males, with documented ages between 24 and 78 years (Fig. 1). Subjects with a history of chronic illness, trauma, physical deformity, or any surgical procedure that might affect stature or scapular dimensions were excluded from the study. The data collection was conducted during an eight-month period between 9:00 am and 10:00 a.m. to avoid the influence of diurnal variation as it affects the standards generated and equations developed for the estimation of stature [52]. The present study was performed with the approval of the ethics committee of the West China Hospital of Sichuan University and all the participants provided written informed consent.

Multidetector computed tomography (MDCT) was carried out on Somatom definition AS 128 slice CT Machine by Siemens Germany Ltd. After obtaining the scout projection, the area of scanning was defined to include the region from fifth cervical vertebra until the first lumbar vertebra. The scanning protocol was as follows: collimation of 1 mm, reconstruction interval of 1 mm, tube voltage of 120 kV, tube current of 110 mA, and scanning time of 0.3 s. Image data were processed on a workstation (Syngo CT 2011A) to obtain volume-rendering technique images. The three-dimensional (3D) reconstructed image was used for assessment.

All measurements on the both sides were recorded from 3D reconstructed image. All the measurements were recorded twice by two investigators respectively. The average was used for statistics analysis. The value mentioned in statistics analysis in our study is true value adjusted by magnification. The parameters for scapulae were defined as follows:

Morphological breadth (MB): The distance between the medial margin and the middle of the glenoid cavity.
Morphological length (ML): The distance between the end of the inferior angle and the vertex of the superior angle.
Longitudinal scapular length (LSL): The distance between the end of the inferior angle and the superior margin of the coracoid process.
Longitudinal maximum length (LML): The distance between the end of the inferior angle and the superior margin of the acromion process.
Transverse scapular length (TSL): The distance between the medial margin and the inferior margin of the glenoid cavity.
Length of axillary margin (LAM): The distance between the end of the inferior angle and the inferior margin of the glenoid cavity.

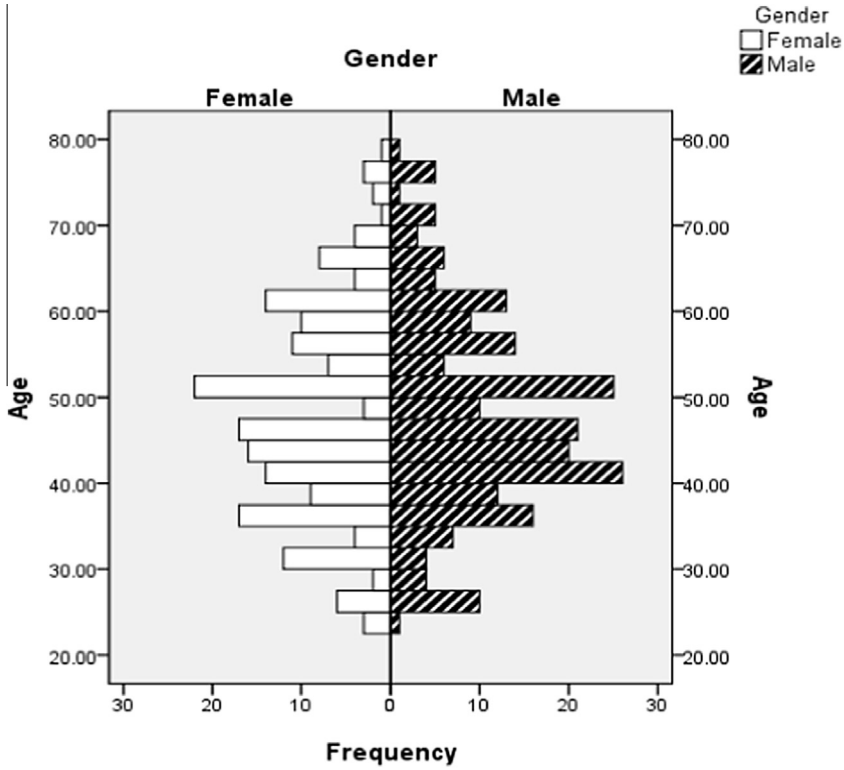

Fig. 1. Age and sex distribution of the collected samples.