Legal Medicine 17 (2015) 517–520

Contents lists available at ScienceDirect

Legal Medicine

journal homepage: www.elsevier.com/locate/legalmed

Case Report

Multiple infectious pseudoaneurysms: An autopsy case

Shuntaro Abe [a,*], Yoshikatsu Okada [b], Takako Sato [a], Koichi Suzuki [a]

[a] Department of Legal Medicine, Division of Preventive and Social Medicine, Faculty of Medicine, Osaka Medical College, 2-7, Daigaku-machi, Takatsuki, Osaka, Japan
[b] Department of Pathology, Division of Comprehensive Medicine, Faculty of Medicine, Osaka Medical College, 2-7, Daigaku-machi, Takatsuki, Osaka, Japan

ARTICLE INFO

Article history:
Received 4 August 2015
Received in revised form 28 October 2015
Accepted 28 October 2015
Available online 29 October 2015

Keywords:
Multiple pseudoaneurysm
Infectious arteritis
Steroid therapy
Intravenous drug abuse
Vasculitic syndrome

ABSTRACT

A 47-year-old Japanese woman died unexpectedly 11 days after admission due to acute cerebellar infarction. The patient had a history of Sjögren syndrome with long-term steroid therapy, hypertension, thalamic infarction and amphetamine psychosis. Multiple pseudoaneurysms in both the aorta and coronary artery were found at autopsy, and one located in the aortic root had ruptured into the pericardium resulting in sudden unexpected death. The detailed examination suggested that the pseudoaneurysms resulted from microbial infection to the arterial wall via the vasa vasorum. Immunosuppression induced by the long-term steroid therapy and abused drug injection could have influenced the formation of pseudoaneurysms.

1. Introduction

We report herein an autopsy case of multiple pseudoaneurysms involving both the aorta and coronary arteries. Pseudoaneurysm, also known as false aneurysm, is extravascular hematoma that is formed as a result of a leaking hole in the vascular wall, leading to free communication with the intravascular space. Pseudoaneurysms are generally induced by trauma and are sporadic; however, pseudoaneurysms are occasionally induced by iatrogenic events, spontaneous dissection, fibromuscular dysplasia, arterial infection, vasculitic syndrome or autoimmune inflammatory disorders [1].

In this case, it was difficult to identify the cause of disease because she had an autoimmune disease under treatment with steroids and a history of injection drug abuse. A detailed forensic examination was thus needed to clarify the pathogenesis. Multifocal pseudoaneurysms are quite rare, involving both the aorta and coronary arteries. In this article, we discuss pathological findings, forensic diagnosis and pathogenesis of this case.

2. Case history

A 47-year-old Japanese woman admitted to a hospital because of dizziness and nausea. She was diagnosed with left cerebellar infarction. Eleven days after admission, she died unexpectedly. A forensic autopsy was performed 29 h after death.

Medical history included Sjögren syndrome (diagnosed 8 years earlier), hypertension (unknown onset), thalamic infarction (6 years earlier) and amphetamine psychosis (3 months prior to her admission). Prednisolone had been administered to treat Sjögren syndrome for 8 years. Six years before the death, she had been admitted to a hospital with the diagnosis of thalamic infarction. She had been known as an amphetamine abuser for the prior 31 years, and she was frequently arrested during those years. About one month before her most recent admission, she was discharged from compulsory hospitalization for amphetamine psychosis.

3. Autopsy findings and examination results

3.1. Autopsy findings

The decedent was 151 cm tall and weighed 57 kg. Old and new injection vestiges were observed in the extremities. The heart weighed 343 g. The pericardial space was filled with 430 mL of dark reddish blood with clots. Multiple hemispherical aortic aneurysms with intimal holes were found at the aortic root to aortic arch (Figs. 1 and 2a). Hematomas adjacent to the circumflex branch of the left coronary artery and to the right coronary artery were observed (Fig. 3). Several white scars were scattered in the intima of the thoracic and abdominal aorta (Fig. 4a and b). One of the pseudoaneurysms in the aortic root ruptured into the hemopericardium (Fig. 1a). White scar was observed in the posterior wall of the left ventricle. Dilatation of the aortic root, mural thrombus, and vegetation in endocardium were not observed (Fig. 1b).

* Corresponding author.
E-mail address: zelkova@art.osaka-med.ac.jp (S. Abe).

http://dx.doi.org/10.1016/j.legalmed.2015.10.011
1344-6223/

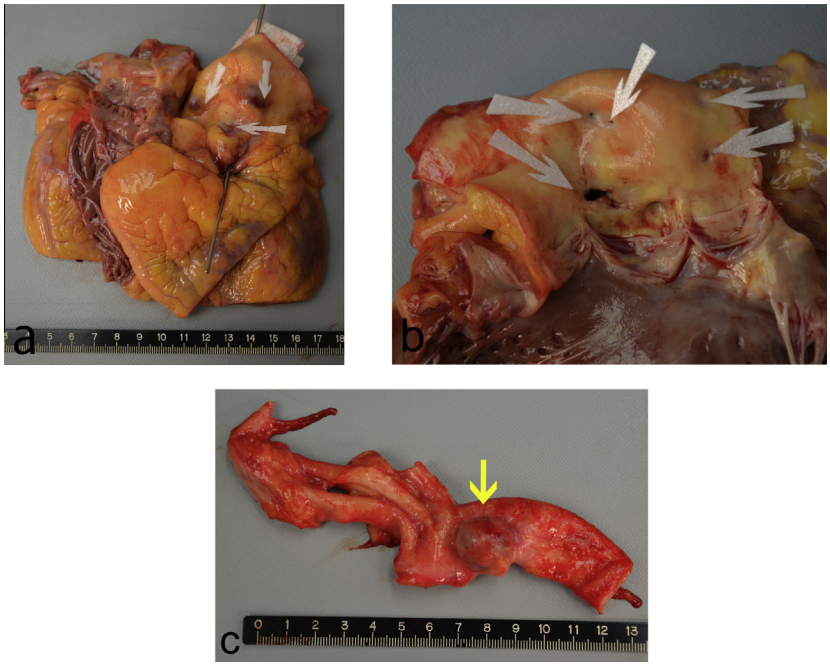

Fig. 1. Macroscopic findings of the heart and aorta. a: Adventitial surface of the aortic root. The metal probe indicates the perforation of the aneurysm, and white arrows mark hemispheric aortic aneurysms. b: Intima of the aortic root. Small orifices in the aoritic lumens are indicated by white arrows. c: Adventitial surface of the thoracic aorta. A hemispheric aortic aneurysm (indicated by the yellow arrow) was conspicuous in the aortic arch. (For interpretation of the references to color in this figure legend, the reader is referred to the web version of this article.)

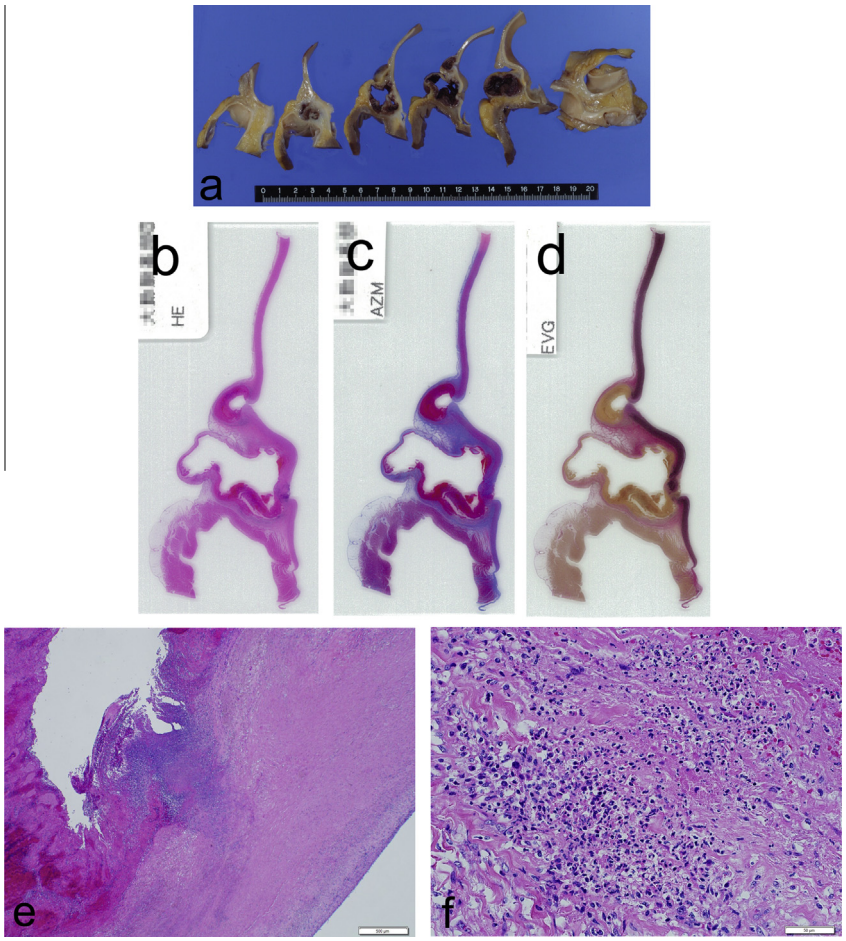

Fig. 2. Aneurysm at the aortic root. a: Serial sections of formalin-fixed tissue specimen. b: HE stain. c: Azan stain. d: Elastica van Gieson stain. The hematoma wall lacks three layers of aorta. e, f: Aneurysm wall with neutrophilic infiltration and macrophages. HE stain.