Legal Medicine 17 (2015) 313–319

Contents lists available at ScienceDirect

Legal Medicine

journal homepage: www.elsevier.com/locate/legalmed

Estimation of sex from the anthropometric ear measurements of a Sudanese population

Altayeb Abdalla Ahmed [a,b,*], Nosyba Omer [b]

[a] Department of Basic Medical Sciences, College of Medicine, King Saud bin Abdulaziz University for Health Sciences, Mail Code: 3127, P.O. Box 3660, Riyadh 11481, Saudi Arabia
[b] Anatomy Department, Faculty of Medicine, University of Khartoum, P.O. Box 102, Khartoum 11111, Sudan

ARTICLE INFO

Article history:
Received 26 November 2014
Received in revised form 15 February 2015
Accepted 8 March 2015
Available online 14 March 2015

Keywords:
Anthropometry
Ear
Forensic
Identification
Sex estimation
Sudanese

ABSTRACT

The external ear and its prints have multifaceted roles in medico-legal practice, e.g., identification and facial reconstruction. Furthermore, its norms are essential in the diagnosis of congenital anomalies and the design of hearing aids. Body part dimensions vary in different ethnic groups, so the most accurate statistical estimations of biological attributes are developed using population-specific standards. Sudan lacks comprehensive data about ear norms; moreover, there is a universal rarity in assessing the possibility of sex estimation from ear dimensions using robust statistical techniques. Therefore, this study attempts to establish data for normal adult Sudanese Arabs, assessing the existence of asymmetry and developing a population-specific equation for sex estimation.

The study sample comprised 200 healthy Sudanese Arab volunteers (100 males and 100 females) in the age range of 18–30 years. The physiognomic ear length and width, lobule length and width, and conchal length and width measurements were obtained by direct anthropometry, using a digital sliding caliper. Moreover, indices and asymmetry were assessed. Data were analyzed using basic descriptive statistics and discriminant function analyses employing jackknife validations of classification results. All linear dimensions used were sexually dimorphic except lobular lengths. Some of the variables and indices show asymmetry. Ear dimensions showed cross-validated sex classification accuracy ranging between 60.5% and 72%. Hence, the ear measurements cannot be used as an effective tool in the estimation of sex. However, in the absence of other more reliable means, it still can be considered a supportive trait in sex estimation. Further, asymmetry should be considered in identification from the ear measurements.

1. Introduction

Biological profiling through the estimation of race, sex, age and stature is a crucial step in establishing the identity of an individual in medico-legal practice. This estimation will result in the reduction of matching tests needed for further definitive confirmative tools, e.g., DNA and fingerprinting to be used [1]. Therefore, there is a continuous need to utilize different body parts and techniques to establish these big four parameters. Identification from an ear print or impression is sometimes needed in a crime scene. Moreover, direct ear examination can be helpful in cases when the examiner is confronted with a severely mutilated face, as in crimes or accidents either for confirmation purposes or at least elimination [2].

The auricle is the part of the external ear that is composed of the helix-antihelical complex, the conchal complex and the lobule. It has been used as a major feature in forensic practice due to its fixed location on the lateral side of the face and because it has a size which is larger than other facial parts, e.g., the retina and iris [3]. Furthermore, it has shown relative stability of shape and orientation compared to facial expression. Additionally, it is believed that external ear characteristics are unique to an individual, meaning that they can be used as corroborative evidence [2,4].

The external ear mutual proportions attain their final form at the fourth month of intrauterine life [5]. Nevertheless, the ear continues to grow postnatally in size until a person reaches the age of maturation in ear width (6 years of age for North American females and 6.6 years among Indian females; males ear mature at the age of 7 for both North Americans and Indians) [6,7]. Conversely, Indians reach maturation 1 year after the age at which North Americans reach maturity in ear length (12 years for females and 13 years in males) [6,7]. However, although proportionality in growth is not affected, it has been found that the gravity causes changes in

* Corresponding author at: Department of Basic Medical Sciences, College of Medicine, King Saud bin Abdulaziz University for Health Sciences, Mail Code: 3127, P.O. Box 3660, Riyadh 11481, Saudi Arabia. Tel.: +966 (11) 4295269 (Office), mobile: +966 558962147; fax: +966 (11) 4299999x95276.

E-mail addresses: drahmedal@gmail.com, ahmedal@ksau-hs.edu.sa (A.A. Ahmed).

http://dx.doi.org/10.1016/j.legalmed.2015.03.002
1344-6223/

vertical dimensions due to non-linear stretching which is maximally expressed in the lobule. Aging is yet another factor that causes significant changes in auricular dimensions, with older individuals having larger values more manifested in ear length compared to width; this length was attributed to lobe and elastic fibers changes. Conversely, lobule width showed the reverse relation with advances in age [8].

A number of studies have assessed ear dimensions and morphology using direct anthropometry, scanning and photogrammetric measurements for different objectives, e.g., to establish basic data, assess their capability in personal identification, growth, congenital anomalies assessment, and aging in Caucasians e.g., American [8], Turkish [9], and Italians [10]; and Asians, e.g., Indians [11] and Chinese [12]. In contrast, there are scanty studies of ear morphology in Africans e.g., Afro-Caribbean's [13]. To the authors' knowledge, no previous reports on ear morphology where found in normal healthy Arabs or mixed Arab-Africans apart from a study assessing subjects with Down syndrome and one assessing lobe morphology [14,15]. An extensive literature review revealed relative scarcity of published research assessing the accuracy of sex estimation using the ear, although there is a general consensus that males tend to have larger ears than females. The only reported study exploring the possibility of sex estimation utilizing the ear was conducted in a mixed group of Indians utilizing ear length and width, base of the auricle, lobule length and width, and the physiognomic ear index. The authors reported an average accuracy between 67.7% and 71% using multiple discriminant function analyses [11].

The knowledge of ear morphology has multiple purposes. It can provide important information for further comparative studies between Sudanese and other populations or even among different Sudanese ethnic groups. In addition, it will provide population specific-standards for the estimation of sex, which is important for establishing identity, especially in the Sudan where there is limitation on the utilization of routine confirmative tests due to either a lack of records or high cost. Complicating matters further, there has also been an escalation in violence. The findings of the present study can be utilized in the diagnosis of congenital anomalies, ear constructive plastic surgeries, in ergonomics and in construction of compatible ear hearings aids.

There are population variations among people from different regions around the world in terms of body part dimensions. Sudan is located in northeastern Africa, and due to the presence of the river Nile, it has experienced multiple migrations of Arabs and Copts resulting in a unique admixture of Arabs and local African populations constituting the majority of contemporary Sudan inhabitants. The glaring shortage of Sudanese identification system standards and escalating violence due to civil war and tribal conflicts necessitate the establishment of Sudanese formulae to obtain accurate identification and to estimate identity attributes [16–19]. Nonetheless, the ear has not been assessed, and the current study aims to establish basic information on ear morphology among young Sudanese adults in terms of dimensions and to assess the existence of bilateral asymmetry. Furthermore, the study primarily aims to explore sexual dimorphism of Sudanese ear measurements and provide population-specific standards for sex assignment based on these measurements.

2. Materials and methods

2.1. Sample

The study sample comprised 200 healthy Sudanese Arab volunteers, 100 males and 100 females. Hence, in total, 400 individual ears were assessed. All subjects were students and staff at the University of Khartoum who originally come from different areas of Sudan and are therefore representative of the contemporary populations of Sudanese Arabs. Each subject was asked to fill the study questionnaire, including basic demographic data and general questions e.g., handedness. Moreover, they were required to sign a consent form. The age of subjects included in this study ranged from 18 to 30 years; the mean age for males was 21.82 ± 2.71 years and for females, it was 21.59 ± 2.74 years. Subjects with a previous history of maxillofacial deformity, congenital anomalies, malignancy, ear trauma, ear diseases or ear surgery were not included in the sample. The study protocol received approval from the ethical committee of the Faculty of Medicine, University of Khartoum.

2.2. Measurements

The subjects were requested to sit upright with their heads in Frankfurt horizontal plane in a well-lit room. Using a standard anthropometric instrument (digital sliding caliper), six measurements were obtained by the same investigator bilaterally. Two concurrent readings were obtained for each measurement, and the mean values were recorded. These measurements included the parameters detailed in the following sections and anatomical landmarks were depicted in Fig. 1.

- Physiognomic ear length (PEL) was measured as the straight distance between superaurale and subaurale following the longitudinal axis of the ear [20].
- Physiognomic ear width (PEW) was measured as the straight distance between preaurale and postaurale [20].

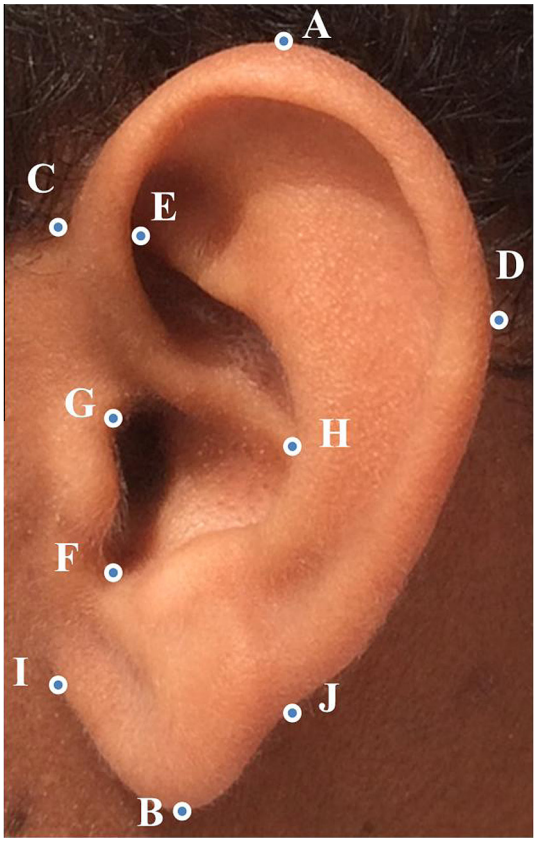

Fig. 1. Anatomical landmarks of the external ear. (A) superaurale, (B) subaurale, (C) preaurale, (D) postaurale, (E) concha superior, (F) incisura intertragica inferior, (G) most posterior point on the edge of incisura anterior auris, (H) strongest anithelical curvature, (I) anterior lobule, (J) posterior lobule.