Journal of Biomechanics 47 (2014) 736–741

Contents lists available at ScienceDirect

Journal of Biomechanics

journal homepage: www.elsevier.com/locate/jbiomech
www.JBiomech.com

Comparative evaluation of scapular and humeral coordinate systems based on biomedical images of the glenohumeral joint

Manuela Calderone [a], Andrea Cereatti [a,*,1], Maurizio Conti [b], Ugo Della Croce [a]

[a] Information Engineering Unit, POLCOMING Department, University of Sassari, Sassari, Italy
[b] Department of Clinical and Experimental Medicine, University of Sassari, Sassari, Italy

ARTICLE INFO

Article history:
Accepted 19 October 2013

Keywords:
Scapula
Humerus
Glenohumeral joint
Anatomical coordinate system
Magnetic resonance

ABSTRACT

Bio-imaging techniques represent a powerful tool for shoulder joint biomechanical analysis. However, the restricted field of view may prevent the acquisition of complete scapula and humerus bone models and hence limiting the applicability of standardized anatomical coordinate system (ACS) definitions. The aim of this study was to propose ACS definitions for both scapula and humerus which can be implemented when limited portions of the relevant bones are available. Magnetic resonance (MR) images of twenty right humeri and scapulae were acquired. The proposed ACSs were assessed in terms of (1) sensitivity to bone morphological variation, (2) intra – and inter – operator repeatability and (3) consistency with the anatomical cardinal directions. A comparison with alternative ACS definitions was also performed. Overall, our ACS scapular proposal and that presented in Kedgley and Dunning (2010) were found to be the least sensitive to the morphometric variability (mean angular absolute deviation lower than 8.3 deg) and they were characterized by a high intra – and inter – operator repeatability (mean angular absolute deviation lower than 1.5 deg). The humeral ACS proposal showed a morphometric variability similar to Amadi et al. (2009b) (mean angular absolute deviation lower than 8.3 deg) but a higher reproducibility. The scapular and humeral ACS mean angular deviation from the reference anatomical cardinal directions were smaller than 15 deg and 8.6 deg, respectively. The proposed scapular and humeral ACS definitions are therefore suitable to be applied when a limited portion of the glenohumeral joint is available as it may occur in standard shoulder clinical exams.
© 2013 Elsevier Ltd. All rights reserved.

1. Introduction

Scapular and humeral anatomical coordinate systems (ACSs) are necessary to quantify the gleno-humeral joint (GHJ) kinematics (Alberta et al., 2006), to describe the normal GHJ relationship (Verstraeten et al., 2013) and to develop GHJ analytical models for stability analysis (Novotny et al., 2000).

The ACS definitions, proposed in the literature for both scapula and humerus, are based either on the identification of anatomical landmarks (ALs) (Pearl et al., 1992; van der Helm, 1997; Novotny et al., 2000; Veeger, 2000; Wu et al., 2005; Kedgley and Dunning, 2010; Ludewig et al., 2010; Verstraeten et al., 2013), or of anatomical regions (ARs) (Sahara et al., 2007; Amadi et al., 2008b; Amadi et al., 2009b). Generally, the spatial locations of the abovementioned morphological parameters are identified by manual palpation or visual inspection of 3D digital models of the bones obtained from biomedical images (Salvia et al., 2009). The size of the reconstructed portion of the bone and the resolution of the images used to reconstruct it determine the applicability of a specific ACS. For instance, the humeral and scapular ACSs recommended by the International Society of Biomechanics (Wu et al., 2005) utilize ALs located on both proximal and distal portions of the bones, and therefore they can be used only if the entire bones are included in the field of view (FoV) of clinical bio-imaging techniques. Considering that technologies allowing for the highest spatial resolution are based on ionizing radiation, such as computer-tomography scanning (CT), dual fluoroscopy, it would be ideal to limit the bone portions to be exposed (Lee et al., 2008). A restricted FoV allows magnetic resonance scans (MR) to be faster, to have a finer spatial resolution and a higher tolerance to motion artifacts (Smith and Nayak, 2012). To this extent, it would be desirable to have ACSs readily applicable when limited scapula and humerus bone portions are included in the FoV.

Moreover, to meet the requirements of intra- and inter-operator repeatability, the ACS definition should be based on ALs (or ARs), which are easy to identify, irrespective of the bone morphology acquisition tool used and least susceptible to the physiological morphometric variability (Amadi et al., 2008b). In addition, ACSs should be consistent with the anatomical cardinal

* Corresponding author. Tel./fax: +39 792 28340.
E-mail address: acereatti@uniss.it (A. Cereatti).
[1] Present address: Information Engineering Unit, POLCOMING Department, University of Sassari, Viale Mancini, 5, 07100 Sassari, Italy.

0021-9290/$ - see front matter © 2013 Elsevier Ltd. All rights reserved.
http://dx.doi.org/10.1016/j.jbiomech.2013.10.045

directions to be clinically interpretable (Amadi et al., 2008b, 2009b; Ludewig et al., 2010).

The primary aim of this study is to present ACS definitions for both scapula and humerus to be used when only their portions near the gleno-humeral joint fall in the FoV (Fig. 1) and fulfilling the abovementioned requirements.

The sensitivity of the newly proposed ACS definitions to bone morphological variation was assessed along with a preliminary analysis of the inter – and intra – operator repeatability associated to the uncertainty in the ALs (and ARs) identification and ACS consistency with the anatomical cardinal directions. A comparison with alternative ACS definitions found in the literature, which do not require the entire scapula and humerus models, was also performed (Fig. 1).

2. Materials and methods

Twenty healthy asymptomatic subjects (9 females, 31 ± 8 y.o.) were enrolled for this study and signed an informed consent. The study was approved by the local Institutional Review Board. MR scans of the whole right humerus and scapula were obtained by using a 1.5 T MR scanner (Philips Intera Achieva version 1.7). Spin Echo imaging sequences were used (axial T1-W: TR 660 ms; TE 18 ms; flip angle 90 deg; Contiguous Slice Thickness 4 mm, FoV 280 mm). Bone contours were identified using a semiautomatic segmentation procedure. 3D reconstructions of the entire scapular and humeral bones were obtained using the AMIRA image processing software (Visualization Sciences Group, v.5.4).

In the following ACS definitions, right-handed ACSs are considered, anatomical planes are defined with respect to the standing subject in the anatomical position (Cappozzo et al., 1995; Wu et al., 2005).

2.1. Proposal for the scapular and humeral ACS

Scapular ACS—The glenoid margin, and consequently its surface, is manually isolated from the scapular model. The scapular origin (O_s) coincides with the centroid (K) of the glenoid, calculated as the average of the coordinates of the vertices forming the triangular meshes. A plane (α) is then fitted to the glenoid margin points (Amadi et al., 2008a). The Z_s axis is oriented as the line orthogonal to α pointing to the right in accordance with Amadi et al. (2008a). An ellipse is fitted to the projections on α of the glenoid margin points. The X_s and Y_s axes are oriented as the minor and major axes of the ellipse, pointing anteriorly and upward, respectively (Fig. 2).

Humeral ACS—The humeral ACS origin (O_h) coincides with the center of the best fitting sphere to the humeral head (HHC) (Gamage and Lasenby, 2002). The Y_h axis is oriented as the canal axis identified by the least square regression line connecting the centers of the humeral shaft cross-section (C1: surgical neck; C2: at a distance of 10 mm from C1, C3 at a distance of 20 mm from C1) pointing upwards. The X_h axis is oriented as the line orthogonal to the Y_h axis, passing to lesser tubercle (LT) and pointing anteriorly. The Z_h is equal to the cross-product between the X_h and Y_h axes (Fig. 3).

2.2. Scapular ACSs selected for comparison

Sahara et al. (2007)—The identification of the following ARs is required: glenoid margin and the flat central region of the glenoid. Since the instructions provided by Sahara et al. (2007) for the identification of the flat central region of the glenoid were ambiguous ("… defined as 3D contiguous meshes including the central mesh and the meshes under 25-30° angles from the central one"), the flat region was identified as follows. An inverted right circular cone with the axis coinciding to the normal to α (see Section 2.1), with an aperture equals to 150° and with the apex coinciding with the closest point of the glenoid surface from the centroid K of the glenoid, is determined. The points of the glenoid surface not included in the cone were selected as the "flat" area of the glenoid. A plane β is then fitted to the points belonging to the flat area (Fig. 7 in Supplementary material). The scapular origin coincides with K. The Z_s axis is oriented as the line orthogonal to the plane β pointing to the right. The X_s axis direction is defined as the line orthogonal to the Z_s, passing through the closest point of the glenoid margin and pointing anteriorly. The Y_s is defined as the cross-product between Z_s and X_s axes (Fig. 4).

Kedgley and Dunning (2010)—The identification of the following ALs is required: the tip of coracoid process (CP), root of the scapular spine (TS) and the acromial angle (AA). The origin coincides with the AA. The Z_s axis is oriented as the line connecting TS and AA, pointing to AA. The Y_s axis direction is defined as the cross product between the oriented line from CP to AA and the Z_s axis. The X_s is defined as the cross-product between Y_s and Z_s axes (Fig. 4).

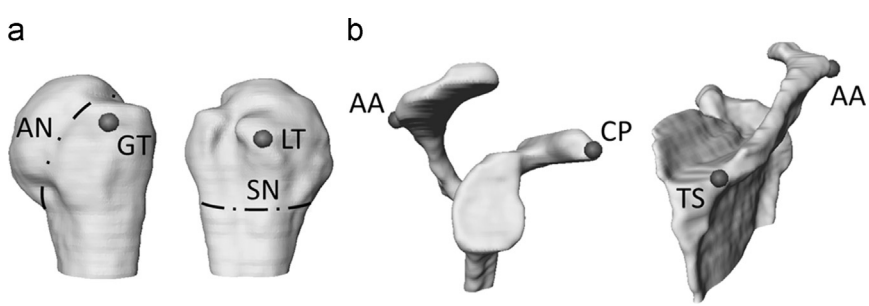

Fig. 1. Bony scapular and humeral portions hypothesized to be available from MR images. The greater tubercle (GT), the lesser tubercle (LT), the anatomical neck (AN) and surgical neck (SN) for the right humerus are reported in (a); the acromial angle (AA), the root of scapular spine (TS) and tip of coracoid process (CP) are reported for the right scapula (b).

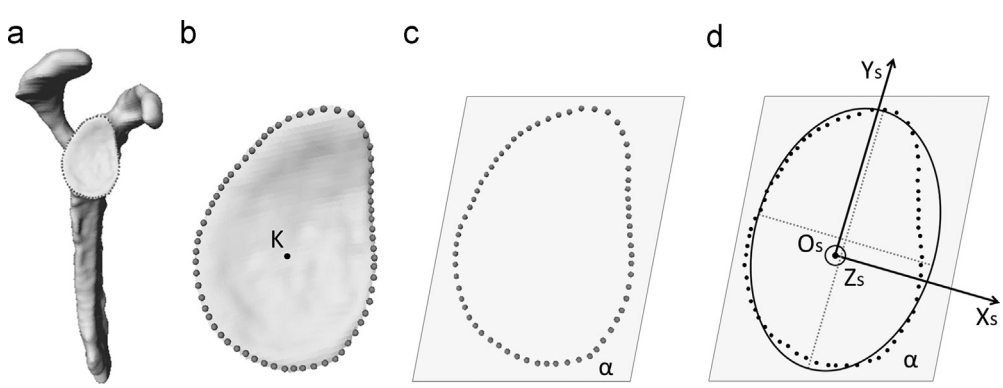

Fig. 2. The novel scapular ACS definition. Glenoid margin is manually identified from the reconstructed glenoid model ((a) and (b)); the plane α is fitted to the selected glenoid points (c); an ellipse is fitted to the points of the glenoid margin projected on α. The ACS for a right scapula is also shown (d).

Download English Version:

https://daneshyari.com/en/article/10431472

Download Persian Version:

https://daneshyari.com/article/10431472

Daneshyari.com