



Clinical note

Case report: Long-standing complex regional pain syndrome relieved by a cephalosporin antibiotic

Mark A. Ware^{a,b,e,*}, Gary J. Bennett^{c,d,e}^a The Alan Edwards Pain Management Unit, McGill University Health Centre, McGill University, Montreal, Quebec, Canada^b Department of Family Medicine, McGill University, Montreal, Quebec, Canada^c Department of Anesthesia, McGill University, Montreal, Quebec, Canada^d Faculty of Dentistry, McGill University, Montreal, Quebec, Canada^e The Louise and Alan Edwards Centre for Research on Pain, McGill University, Montreal, Quebec, Canada

Sponsorships or competing interests that may be relevant to content are disclosed at the end of this article.

ARTICLE INFO

Article history:

Received 5 February 2014

Received in revised form 14 March 2014

Accepted 19 March 2014

Available online xxx

Keywords:

Cefadroxil

Ceftriaxone

Cephalosporin

CRPS

RSD

Neuropathic pain

ABSTRACT

We describe a young woman who had had treatment-refractory complex regional pain syndrome (CRPS) for 6 years before receiving antibiotic treatment with cefadroxil (a cephalosporin derivative) for a minor infection. Cefadroxil reduced the patient's pain and motor dysfunction (dystonia and impaired voluntary movement) within days; the pain and motor disorder returned when cefadroxil was discontinued; and both again abated when cefadroxil was re-instituted. The patient has now had symptom relief for more than 3 years on continuing cefadroxil therapy. We discuss this case in the context of previous reports of antibiotic treatment relieving neuropathic pain in experimental animals.

© 2014 International Association for the Study of Pain. Published by Elsevier B.V. All rights reserved.

1. Introduction

We describe a case of a patient with intractable complex regional pain syndrome who responded to the antibiotic cefadroxil, given for an incidental infection, with impressive and sustained effects on pain and dystonia.

2. Case report

The patient is a young right-handed woman who developed complex regional pain syndrome (CRPS) in the left upper extremity when she was 24 years of age. The injury occurred in February 2004 while her arm was elevated and stretched as she pulled a sweater over her head. She reports feeling a slightly painful “popping” sensation at the time of injury, and points to the posterior shoulder region as its location.

A report of an electrodiagnostic examination performed in May 2004 stated, “She can only abduct the left arm from the side of her body to about 50°. There is virtually no ability to elevate the left arm above the horizontal plane. The left hand remains visibly edematous. The median, radial, and ulnar sensory nerve action potentials were studied bilaterally, and no abnormalities were seen. However, there was some relative reduction in the sensory nerve action potential amplitudes on the left side. The median and ulnar nerve motor conduction velocities were studied bilaterally and no abnormalities were seen. The distal right and left ulnar F-wave latencies were comparable in value. EMG of the left biceps and left abductor pollicis brevis was normal”.

Her first examination in our clinic was 10 months after the precipitating injury. Her history revealed the following. She was previously well aside from routine tonsillectomy and appendectomy. She reported that pain and weakness in the left extremity were evident the morning after the injury, and that, within a few days, her entire arm and hand had become painful and allodynic to touch, bluish-purple in color, and that the whole arm and the left breast were swollen. She described the pain as “burning” and “pulling,” continuous but fluctuating, and with an average intensity of 8.5 on a numeric rating scale (NRS) of 0 to 10. The tactile

* Corresponding author. Address: E19.145 Montreal General Hospital, 1650 Cedar Avenue, Montreal, QC H3G 1A4, Canada. Tel.: +1 (514) 934 1934; fax: +1 (514) 934 8096.

E-mail address: mark.ware@mcgill.ca (M.A. Ware).

<http://dx.doi.org/10.1016/j.pain.2014.03.014>

0304-3959/© 2014 International Association for the Study of Pain. Published by Elsevier B.V. All rights reserved.

allodynia was severe, with contact from clothing unbearable and pain being felt when a breeze blew across the skin. She reported that her pain was worsened by cold, but it is not certain that this reflected cutaneous cold allodynia. She stressed that the pain and allodynia interfered with her sleep to the point that her work and daily activities were badly compromised. The patient reported that the fingernails of the affected hand grew abnormally quickly and were brittle. The patient reported that her hand and arm was unresponsive to motor commands, that she could lift her arm only slightly, and that the attempt required great effort and induced a coarse tremor. She complained of occasional spontaneous convulsive arm movements.

Examination revealed minor atrophy of the left arm muscles, skin discoloration, tremor, and tactile allodynia on the hand and forearm. The left hand was slightly warmer than the right. The hair on the dorsal hand and forearm was darker and coarser than on the other side. She held the arm in a flexed position next to her body for protection. The hand was in a stiff claw-like posture, and she could not move her fingers or thumb (over the next 3 years, this progressed to a posture with all fingers flexed and the thumb locked in adduction and trapping the index finger) (Fig. 1A). Subsequent investigations included a blood test for autoimmune disease; venogram; brain, cervical, thoracic, and brachial plexus magnetic resonance imaging, brachial plexus and lumbar computed tomography, and lumbar puncture; however, none of these was informative. Psychological evaluation in February 2005 revealed no evidence of depression but significant anxiety with regard to her future (work, health, sleep). She had had episodes of panic attack and agoraphobia. Her daily activities were dominated by her preoccupation with pain and the loss of use of her arm. Subsequent evaluation by medical specialists in neurology, physiatry, neurosurgery, and anesthesia confirmed the diagnosis of CRPS. The patient refused an offer to have a spinal stimulator installed.

The following treatments were tried without success: stellate ganglion blocks, intra-articular shoulder injections, 3 suprascapular nerve root blocks, extensive physiotherapy including mirror box therapy, transcutaneous electrical nerve stimulation (TENS), and a hand brace. Individual psychotherapy was conducted with the aim of reducing anxiety and improving coping skills. She attended a group therapy self-management program. Medication trials included nonsteroidal anti-inflammatory drugs (NSAIDs), tricyclic antidepressants, gabapentin, pregabalin, venlafaxine, opioids (codeine, oxycodone, and methadone), topiramate, calcitonin, and intravenous lidocaine, none of which afforded her any useful relief. Her pain and disability were pronounced, and she struggled

to cope. After participating in a clinical trial of smoked cannabis [15], she continued to use cannabis because it helped with sleep and reduced her tremor and convulsive arm movements but without any effect on the pain.

In March 2010, she was started on cefadroxil 500 mg orally twice daily for an infection under the lateral fold of the fingernail on digit IV of her left (CRPS) hand. Starting within 1 to 2 days, she noted a gradual reduction in dystonia (reduced clenching of the fingers and thumb, and improved voluntary movement of her arm) and a lessening of her fatigue ("more energy"). Over the next several days, her motor function continued to improve, and she noted a reduction in the intensity of her pain and allodynia. Pain, allodynia, and motor symptoms returned within 12 hours after she completed her 10-day course of antibiotic treatment.

To further investigate her response to cefadroxil, we performed an unblinded trial of alternating periods of 1 week on-drug and 1 week off-drug at the dose that she had used previously. The trial began on July 13, 2010, with the patient keeping a pain diary in which she recorded daily average pain-at-rest on an NRS of 0 to 10, where 0 = no pain, and 10 = worse pain imaginable. She also made daily entries of the average severity of her motor dysfunction using a scale of 0 to 10 that she devised. Cefadroxil was resumed, and 6 days later the trial began (Fig. 2). For the first 6 days on the drug, her pain ranged from 3.5 to 4.0, and her motor dysfunction was steady at a score of 4.0. When the drug was withdrawn, her pain and motor dysfunction worsened quickly (starting within 1 day), with her pain score climbing to 8.0 and her motor score to 7.5. Re-instating the drug resulted in improved pain scores and motor scores within 2 to 3 days. Discontinuing drug for a second time again resulted in a rapid (1-day) worsening of pain and motor scores. Re-instating the drug for a second time again resulted in marked symptom improvement within a period of 2 to 3 days.

At the conclusion of this trial, and after consulting infectious disease specialists and discussing the risks of prolonged antibiotic exposure, the decision was made to continue cefadroxil at 500 mg twice daily. Subsequent efforts to use intermittent dosing (1 week on, 1 week off) were followed by continuing rapid worsening of symptoms during the off-drug week. Reducing the dose to 250 mg twice daily resulted in symptoms returning. She has remained on cefadroxil 500 mg twice daily ever since, with regular follow-up examinations every 4 months.

While on cefadroxil, the patient reports loose stools, difficulty initiating sleep, and mild irritability. She describes her sleep problem as serious and ascribes it to the feeling of "having more energy." She now takes an over-the-counter probiotic supplement (Bio-K+; Bio-K Plus International, Laval, QC, Canada), which corrects her bowel function. She continues to use cannabis to help her sleep (her cannabis use is under the aegis of the Canadian *Marihuana for Medical Purposes Regulations*). An informal trial of oral nabilone as a sleep aide was unsuccessful.

When last seen (November 2013; 3 years 8 months after starting cefadroxil), she rated her pain-at-rest as 0/10 but said that the pain increases to 3/10 with prolonged use of her arm/hand. She had nearly normal function of the left arm, and she noted that her left biceps had returned to near normal size; however, her left forearm muscles were still atrophied. The nails were normal, skin color was normal, and the hair on the dorsal hand and forearm was normal or very nearly so. The hand (Fig. 1B) was greatly improved, although not fully functional. The fingers were unclenched but now distorted by disuse contractures; the thumb was mobile. The intrinsic muscles of the hand were atrophied. She continues to take cefadroxil 500 mg twice daily and has had no serious adverse effects from therapy. She is active and practicing yoga. She left her previous job and started her own business. She sleeps well with continued use of cannabis before bedtime. She states that although she was initially dominated by her condition, she

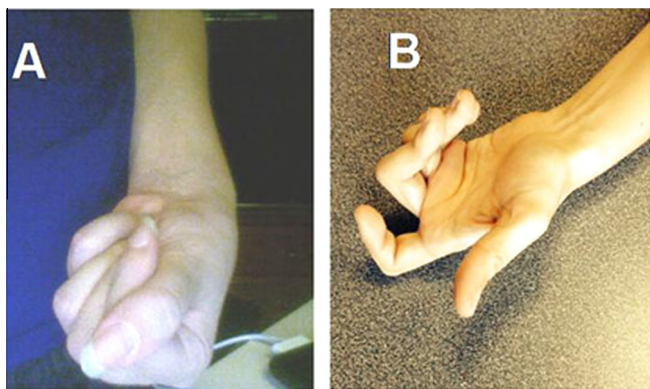


Fig. 1. Photographs of the hand affected by complex regional pain syndrome, taken in (A) March 2008 before antibiotic therapy, and (B) in November 2013, after 3 years and 8 months of cefadroxil treatment.

Download English Version:

<https://daneshyari.com/en/article/10450529>

Download Persian Version:

<https://daneshyari.com/article/10450529>

[Daneshyari.com](https://daneshyari.com)