Ultrasound in Med. & Biol., Vol. 41, No. 7, pp. 1896–1904, 2015
Copyright © 2015 World Federation for Ultrasound in Medicine & Biology
Printed in the USA. All rights reserved
0301-5629/$ - see front matter

http://dx.doi.org/10.1016/j.ultrasmedbio.2015.02.012

● *Original Contribution*

QUANTIFICATION OF MICROVASCULAR TORTUOSITY DURING TUMOR EVOLUTION USING ACOUSTIC ANGIOGRAPHY

Sarah E. Shelton,* Yueh Z. Lee,†‡ Mike Lee,§ Emmanuel Cherin,§ F. Stuart Foster,§ Stephen R. Aylward,¶ and Paul A. Dayton*‡

*Joint Department of Biomedical Engineering, University of North Carolina at Chapel Hill and North Carolina State University, Chapel Hill, North Carolina, USA; †Department of Neuroradiology, University of North Carolina at Chapel Hill, Chapel Hill, North Carolina, USA; ‡Biomedical Research Imaging Center, University of North Carolina at Chapel Hill, Chapel Hill, North Carolina, USA; §Department of Medical Biophysics, Sunnybrook Health Sciences Centre, Toronto, Ontario, Canada; and ¶Kitware Medical Imaging, Carrboro, North Carolina, USA

(*Received* 3 *October* 2014; *revised* 18 *February* 2015; *in final form* 21 *February* 2015)

Abstract—The recent design of ultra-broadband, multifrequency ultrasound transducers has enabled high-sensitivity, high-resolution contrast imaging, with very efficient suppression of tissue background using a technique called acoustic angiography. Here we perform the first application of acoustic angiography to evolving tumors in mice predisposed to develop mammary carcinoma, with the intent of visualizing and quantifying angiogenesis progression associated with tumor growth. Metrics compared include vascular density and two measures of vessel tortuosity quantified from segmentations of vessels traversing and surrounding 24 tumors and abdominal vessels from control mice. Quantitative morphologic analysis of tumor vessels revealed significantly increased vascular tortuosity abnormalities associated with tumor growth, with the distance metric elevated approximately 14% and the sum of angles metric increased 60% in tumor vessels versus controls. Future applications of this imaging approach may provide clinicians with a new tool in tumor detection, differentiation or evaluation, though with limited depth of penetration using the current configuration. (E-mail: padayton@email.unc.edu) © 2015 World Federation for Ultrasound in Medicine & Biology.

Key Words: **Tortuosity, Contrast agent, Microbubble, Ultrasound, Acoustic angiography, Microvasculature, Angiogenesis, Superharmonic imaging.**

INTRODUCTION

Ultrasound imaging has several advantages over other modalities in the clinic such as low cost, portability, tolerability and real-time imaging capability. However, gray-scale ultrasound suffers from speckle noise and has poor sensitivity to blood flow in small vessels. In contrast-enhanced ultrasound (CEUS), a microbubble contrast agent is administered to enhance imaging sensitivity to blood flow, and CEUS is used primarily to enhance delineation of the left ventricle in echocardiography. Quantitative CEUS imaging, including techniques such as wash-in and wash-out curves, has been widely used in oncology imaging because of the involvement of vascular networks in tumor progression (Quaia 2011). Current CEUS imaging is performed at clinically relevant frequencies between 1 and 12 MHz, and uses techniques such as pulse inversion and amplitude modulation to enhance detection of microbubbles and reduce tissue background (Averkiou et al. 2003; Martin and Dayton 2013). However, these strategies also limit both the resolution and contrast-to-tissue ratio of existing CEUS imaging.

Acoustic angiography is a significant advance in CEUS imaging made possible by the application of dual-frequency ultrasound transducers, which, as of yet, are still only available as prototype devices (Gessner et al. 2013). In acoustic angiography imaging, microbubble contrast agents are excited by a low-frequency ultrasound transducer element, similar to those used in clinical imaging (2–4 MHz), yet imaging data are received with a second transducer at a much higher frequency, for example, 25–30 MHz, using the technology described here. The excited microbubbles produce broadband superharmonic energy, which can be detected with the high-frequency receiver, whereas tissue scatters almost

Address correspondence to: Paul A. Dayton, UNC-NCSU Joint Department of Biomedical Engineering, 152 MacNider Hall, CB7575, Chapel Hill, NC 27599, USA. E-mail: padayton@email.unc.edu

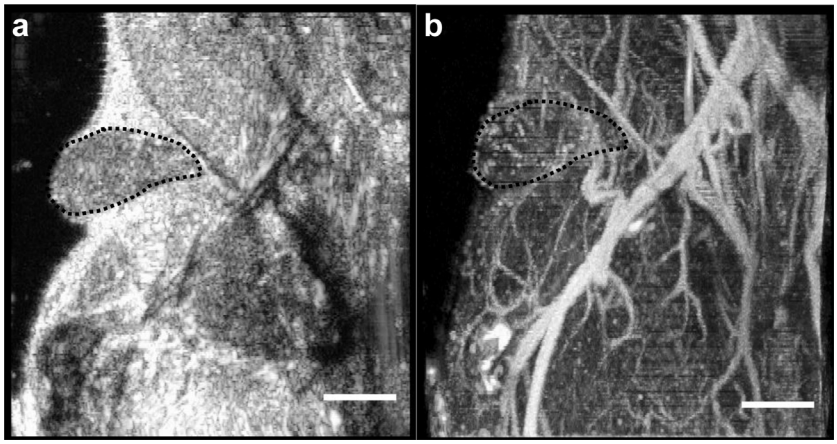

Fig. 1. (a) Coronal slice reconstruction of a B-mode tissue volume. (b) Maximum intensity projection of the acoustic angiography image of the same tissue volume, approximately 2.5 × 2.5 cm. The *dashed outline* delineates a tumor in the right inguinal mammary pad of a mouse in both images. Bars = 4 mm.

negligible energy at this frequency (Kruse and Ferrara 2005). This dual-frequency approach results in images of the contrast agent only (flowing through the microvessels) with very minimal if any tissue background. This new technique yields images of blood vessel morphology entirely unlike standard B-mode ultrasound images and resembling X-ray angiograms, thus leading us to refer to this technique as "acoustic angiography." An additional substantial advantage is that the dual-frequency approach enables resolution as dictated by the high-frequency receiver, although this also provides a limitation in penetration depth caused by (one-way) attenuation of high-frequency signals from the microbubbles (Lindsey et al. 2014). Figure 1 depicts a side-by-side comparison of B-mode and acoustic angiography (maximum intensity projection) images of the same tissue volume, approximately 2.5 × 2.5 cm, in the coronal view, illustrating the advantages of acoustic angiography in assessing microvascular structure.

Because acoustic angiography can image microvessel structure, it is an ideal tool for visualizing abnormal vascular morphology resulting from cancer angiogenesis. Angiogenesis is the process of new vascular growth, which is a necessary process for physiologic events such as wound healing (Nissen et al. 1998), but escapes normal pathologic control during tumor development. Malignant angiogenesis is so pervasive across different types of tumors that it is one of Hanahan and Weinberg's (2011) "hallmarks of cancer." Judah Folkman (1971) was one of the first researchers to realize the importance of angiogenesis in cancer and posited that tumors would not grow beyond 2–3 mm in size without neovascularization, and the work described here found that 2- to 3-mm tumors do indeed exhibit quantifiable angiogenesis in the mouse model chosen. A number of mechanisms of tumor angiogenesis exist, driven by different pro-angiogenic growth factors and molecular pathways (Carmeliet and Jain 2011). However, the end result of such abundant pro-angiogenic processes is a vascular network that is abnormal in both form and function. Tumor vessel networks lack the ordered, hierarchical branching networks found in normal tissue; vessels are leaky and tortuous and have unpredictable relationships between size and flow rate (Jain et al. 2014). The angiogenic factors produced by tumors (such as vascular endothelial growth factor [VEGF]) often cause increased vessel diameter, vascular density, permeability, as well as alterations in vessel structure (Jain 2005, 2014). Acoustic angiography has the unique potential to improve visualization and quantification of some of these angiogenic changes.

The microvascular maps produced by acoustic angiography have sufficient contrast and detail that computerized segmentation using multiscale ridge traversal for centerline extraction (Aylward and Bullitt 2002) can be used to define the spatial coordinates occupied by individual vessels. From the spatial coordinates, the "curvedness," or tortuosity, of the vessels can be computed, enabling the definition of multiple descriptions of vessel shape. It is the quantification of these tortuosity metrics that provides a new way to describe tumors using ultrasound imaging (Gessner et al. 2012). Tortuosity associated with malignancy has been used previously with other imaging modalities such as magnetic resonance angiography, photo-acoustic tomography, microscopy and computed tomography (CT) (Badea et al. 2008; Bullitt et al. 2004, 2005b, 2006; Jain 2003; Laufer et al. 2012; Sodi et al. 2013). However, ultrasound applications of tortuosity metrics have been limited primarily to quantification of skeletonizations from intensity thresholding of Doppler ultrasound images (Chang et al. 2012; Huang et al. 2008; Molinari et al.

Download English Version:

https://daneshyari.com/en/article/10691236

Download Persian Version:

https://daneshyari.com/article/10691236

Daneshyari.com