



Deliniation of oral mucosa

A novel method for delineation of oral mucosa for radiotherapy dose–response studies



Jamie A. Dean ^{a,*}, Liam C. Welsh ^b, Sarah L. Gulliford ^a, Kevin J. Harrington ^b, Christopher M. Nutting ^b

^aJoint Department of Physics at The Institute of Cancer Research and The Royal Marsden NHS Foundation Trust; and ^bHead and Neck Unit, The Royal Marsden NHS Foundation Trust, London, UK

ARTICLE INFO

Article history:

Received 11 July 2014

Received in revised form 2 February 2015

Accepted 5 February 2015

Available online 13 March 2015

Keywords:

Contouring

Delineation

Oral mucosa

Oral mucositis

Dose–response

ABSTRACT

There is currently no standard method for delineating the oral mucosa and most attempts are oversimplified. A new method to obtain anatomically accurate contours of the oral mucosa surfaces was developed and applied to 11 patients. This is expected to represent an opportunity for improved toxicity modelling of oral mucositis.

© 2015 The Authors. Published by Elsevier Ireland Ltd. Radiotherapy and Oncology 115 (2015) 63–66
This is an open access article under the CC BY license (<http://creativecommons.org/licenses/by/4.0/>).

Mucositis of the oral mucosa is a common and important acute toxicity in head and neck radiotherapy warranting efforts to mitigate its severity and impact on patients. It may result in reduced quality of life due to pain, dysphagia [1–3], weight loss and aspiration [4,5]. These effects can result in patients being hospitalised and missing treatment fractions [6], compromising locoregional control [7,8]. Mucositis is also frequently the dose-limiting toxicity in dose escalation and accelerated fractionation regimens, designed to improve tumour control [9–11], and has been implicated in causing ‘late’ toxicity [12–15].

Heterogeneous dose distributions are delivered to the mucosa with intensity-modulated radiotherapy (IMRT), allowing the oral mucosa to be partially spared [16]. However, the development and grade of mucositis is challenging to predict. If a relationship between the dose distribution and toxicity is established, it may be possible to reduce oral mucositis, by means of a treatment planning intervention. Few dose–response studies have been performed for oral mucositis. The complex shape of the mucosal surface, coupled with the fact that it is poorly visualised on computed tomography (CT) are challenges to accurate delineation. Previous oral mucosa dose–response studies [16–18] have reduced the complex shape of the oral mucosa surfaces to a solid oral cavity volume. Clinical experience suggests that dose–area effects may influence mucositis severity. Characterising the dose delivered to

the surfaces of the oral mucosa is necessary to properly study the dose–response relationship. A method of obtaining the dose distribution delivered to the oral mucosa surfaces would, therefore, represent an important advance in attempts to model and, thereby, reduce oral mucositis.

The primary aim of this study was to develop CT-based delineation guidelines to contour the surfaces of the oral mucosa in an anatomically realistic manner. The secondary aim was to establish the worth of the new contouring approach for dose–response studies by assessing the magnitude of the differences in dose metrics extracted from treatment plans using the new, more realistic approach, and previously used contouring techniques.

Materials and methods

Patients

Treatment plans of 11 head and neck radiotherapy patients treated at our institution between 2006 and 2013 were included in the study. The patients had oral cavity contours (OCC) generated using our previous method [17] (based on the oral mucosa definition described by Eisbruch et al. [19]), and these were used for comparison of the dose distributions extracted using our new technique for obtaining mucosal surface contours (MSC). This cohort incorporated a range of primary disease sites (oropharynx, hypopharynx and nasopharynx), two different CT scanners and included edentulous and dentate patients, eight of whom had dental implants.

* Corresponding author at: Joint Department of Physics at The Institute of Cancer Research and The Royal Marsden NHS Foundation Trust, London SM2 5NG, UK.

E-mail address: jamie.dean@icr.ac.uk (J.A. Dean).

Structure definition

The MSC were defined as a 3 mm thick wall of tissue based on work by Ueno et al. measuring the oral mucosal thickness at multiple sites in five cadavers using a reamer method [20]. They measured a mean thickness of 3.12 ± 1.43 mm. The outlined MSC included the following surfaces: buccal mucosa, buccal gingiva, gingiva proper, lingual gingiva, lingual frenulum, alveolar mucosa, labial mucosa, labial gingiva, labial frenulum, mucosal surface of the floor of mouth, mucosal surface of the tongue anterior to the terminal sulcus, and the mucosal surface of the hard palate. The superior extent was defined to be the superior border of the labial mucosa of the upper lip anteriorly, the roof of the palate posteriorly and the superior extent of the buccal mucosa laterally. The inferior extent was formed by the inferior border of the labial mucosa of the lower lip anteriorly, the surface of the tongue posteriorly and the inferior extents of the floor of mouth mucosa and buccal mucosa laterally. The lateral extents of the buccal mucosa formed the lateral borders. The anterior border followed the alveolar mucosa and the posterior extent of the hard palate formed the posterior border (Fig. 1).

Structure delineation

Structure delineation was performed, by a head and neck radiation oncologist (LW), using the RayStation version 4.0 treatment

planning system (RaySearch Laboratories AB, Stockholm, Sweden). The majority of contouring was performed on coronal slices as the main axis of the structure runs in the anterior–posterior direction. Using the coronal plane is beneficial in being able to capture the arch of the palate and the superior, inferior and lateral extents of the buccal mucosa. Sagittal views were useful in establishing the position of the posterior border and axial views aided in contouring the mucosa of the retromolar trigone. The MSC were initially delineated as a single line and, once complete, expanded to a 3 mm annulus. The delineation process was semi-automated using atlas-based segmentation (described in the [Supplementary Material](#)).

Comparison of geometries

The geometries of the OCC and MSC structures were compared by measuring the volumes of these structures and the volumes of their overlap with the primary planning target volume (PTV). To gain an appreciation of the difference in the surface areas of the OCC and MSC structures, an ‘OCC surface’ was defined as a 3 mm annulus extending inwards from the outer surface of the OCC. The volumes of these ‘surface’ structures were then compared to the MSC volumes.

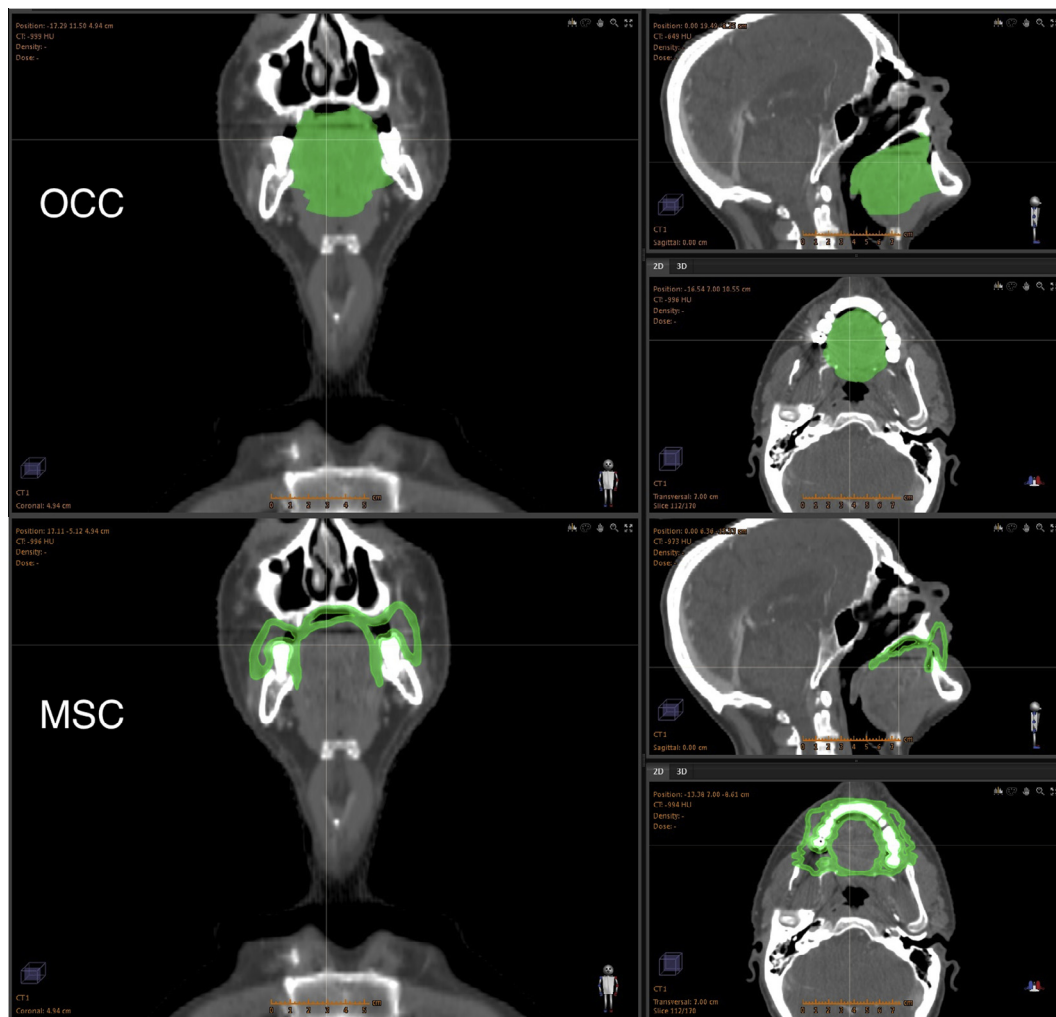


Fig. 1. CT scan of a head and neck radiotherapy patient with the OCC (top) and MSC (bottom) shown in green. The OCC representation reduces the complex shape of the mucosal wall to a simplified solid volume, whereas the MSC structure is represented as a mucosal surface and, as such, represents a more anatomically realistic description of the oral mucosa.

Download English Version:

<https://daneshyari.com/en/article/10918354>

Download Persian Version:

<https://daneshyari.com/article/10918354>

[Daneshyari.com](https://daneshyari.com)