



Case Report

Bromocriptine Treatment for Inappropriate Lactation in Mares: A Case Report

Marcela Gonçalves Meirelles DVM^a, Carina de Fátima Guimarães DVM^a,
 Mariana Baroni Selim DVM^b, Francisco Palma Rennó PhD, DVM^c, Carla Bargi Belli PhD, DVM^d,
 Claudia Barbosa Fernandes PhD, DVM^a

^a Department of Animal Reproduction, College of Veterinary Medicine and Animal Science, University of São Paulo, São Paulo, Brazil

^b Department of Surgery, College of Veterinary Medicine and Animal Science, University of São Paulo, São Paulo, Brazil

^c Department of Nutrition and Animal Production, College of Veterinary Medicine and Animal Science, University of São Paulo, São Paulo, Brazil

^d Department of Internal Medicine, College of Veterinary Medicine and Animal Science, University of São Paulo, São Paulo, Brazil

ARTICLE INFO

Article history:

Received 19 December 2011

Received in revised form

13 March 2012

Accepted 21 March 2012

Available online 8 May 2012

Keywords:

Persistent galactorrhoea

Bromocriptine

Equine

Cushing

Prolactin

ABSTRACT

Transient mammary gland development and lactation can occur eventually in weanling foals, yearlings, and adult mares without previous or recent history of pregnancy. The etiology of this condition has not been well documented, and there is limited information on the occurrence, frequency of episodes, composition, and treatment of galactorrhoea secretion. This article reports a case of Brazilian Sport Horse mare, aged 10 years, with persistent lactation during 5 months. The treatment consisted of bromocriptine 0.04 mg/kg, b.i.d., orally, for 10 days, associated with hydrotherapy for 20 minutes, twice daily. After 20 days of the treatment onset, the mare was reevaluated, and a significant decrease in the volume of the udder and the amount of secretion produced was noted, and its aspect was clearer (serous) and consisted of more fluid compared with the one collected before treatment. No other clinical alterations or associated diseases were identified. Based on these findings, we suggest the diagnosis of idiopathic inappropriate lactation. Although there is no information about pharmacokinetics and description of the oral bromocriptine use in horses, being a therapeutic option for inappropriate lactation treatment in mares, it was effective at the recommended dosage.

© 2012 Elsevier Inc. All rights reserved.

1. Introduction

Galactorrhoea may be defined as secretion of milk or milk-like secretion that occurs in the absence of parturition or after weaning. Two conditions may be defined: premature lactation, when the lactation occurs precociously during pregnancy, or inappropriate lactation, when lactation occurs in the absence of gestation [1].

In humans, galactorrhoea occurs as a result of increased plasma levels of prolactin, a hormone secreted by the

adenohypophysis. Hyperprolactinemia is a common disorder of the hypothalamic-pituitary axis, which usually presents with reproductive abnormalities [2,3]; it may be caused by pituitary tumors, hypothyroidism, or secondary effects of drugs [1,4].

A transient mammary gland development and lactation can occur [5,6] eventually in weanling foals, yearlings, and adult mares without previous or recent history of pregnancy. The etiology of this condition in these animals has not been well documented [1,6]; additionally, there are few reports on the occurrence, frequency of episodes, or composition of the galactorrhoea secretion [7].

The most commonly identified cause of inappropriate lactation in mares is an elevation in prolactin levels, secondary to Cushing disease [5,6,8]. In the literature, two

Corresponding author at: Claudia Barbosa Fernandes, PhD, DVM, Departamento de Reprodução Animal, Av. Prof. Dr. Orlando Marques de Paiva, 87, Cidade Universitária Universidade de São Paulo, 05508-270 São Paulo, Brasil.

E-mail address: fernandescb@usp.br (C.B. Fernandes).

mares were reported having these clinical signs [9]. Thus, this report aims to describe galactorrhea in an animal without clinical signs of Cushing disease and proposes a new treatment option with the use of bromocriptine.

2. Case Report

A Brazilian Sport Horse mare, aged 10 years and weighing 570 kg, kept in a stable and fed coast cross hay and commercial concentrate (12% crude protein [CP]), was presented at the Veterinary Hospital of the College of Veterinary Medicine of the University of São Paulo, São Paulo, Brazil, with a 5-month history of persistent lactation, associated with discomfort caused by the swelling of the udder and spontaneous ejection of milk (Fig. 1).

The mare was nulliparous, and it was never inseminated or given any hormone treatment. The animal had no contact with foals, and there were no data available from previous reproductive examinations. Throughout the period, no drug therapy was performed, and the only procedure was milking daily, resulting in a total volume of approximately 1 L of milk per day.

The inspection of the mare revealed a body condition score equivalent to 5 (scale of 1–6) [10]. There were no alterations in vital parameters during physical examination.

In gynecological evaluation, the uterus had normal wall thickness and absence of free fluid, the left ovary had multiple follicles with diameters smaller than 15 mm, and the right ovary showed presence of corpus luteum. A firm enlargement of the mammary gland was identified, and there was no sensibility or hyperthermia. There was spontaneous secretion and ejection by sphincters on both teats. The collected secretion had milk-like appearance and odor.

The treatment started before obtaining the laboratory tests results. Bromocriptine was prescribed at a dose of 0.04 mg/kg, b.i.d., orally, for 10 days. Local hydrotherapy was also recommended for 20 minutes, twice daily. Milking was only allowed in situations where the mare was in extreme discomfort due to swelling of the mammary gland, without completely draining the secretion.

Samples of mammary gland secretion of both teats were sent to the Laboratory of Milk Production, University of São

Paulo, for fat content analyses by the Gerber method, and CP content by the Kjeldahl method, calculated by multiplying the total nitrogen by a factor of 6.38.

Sample of blood plasma was sent to B.E.T. Laboratories for analyses of cortisol, triiodothyronine (T3), and total and free thyroxine (T4) levels. The level of prolactin, which would be interesting for this case, could not be measured due to an absence of laboratories that perform this analysis in the country.

Twenty days after treatment onset, the mare was reevaluated and a significant decrease in the volume of the udder and the amount of secretion produced was found, and its aspect was clearer (serous) and consisted of more fluid compared with the one collected before treatment.

3. Discussion

The results of the assessment of mammary secretion were fat content between 0.8% and 0.9% and CP content between 1.5% and 1.6%. These results are similar to the values reported for equine milk obtained from Brazilian breeds animals during the lactation period, in which the amount of fat ranged from 0.86% to 1.70% and CP content between 1.48% and 2.40% [11,12].

In hormonal evaluations, the results were 46.0 ng/dL for cortisol, 1.15 ng/dL for total T3, 16.1 ng/dL for total T4, and 0.55 ng/dL for free T4. The value of free T4 (0.55 ng/dL) appeared below the normal range considered for the equine species (1.76 ng/dL until 4 ng/dL) [13–15]. However, hypothyroidism in horses cannot be diagnosed by a single measurement of T3 and T4 and must be based on one of the thyroid gland stimulation tests [16].

The concentration of circulating iodothyronine can be influenced by many factors not related to the thyroid, including food deprivation [16–18], phenylbutazone administration [16,19,20], circadian rhythm [14,16], and dietary composition [16,21,22]. As women [23,24], rats [25], cows, and sheep [26,27] have a state of relative hypothyroidism during lactation, with levels of circulating T3 and T4 significantly lower [28], this condition may explain the decrease in circulating T4 in the mare of this case report.

Thyroid hormones modulate the secretion of other hormones that regulate the mammary function and milk ejection, thus exerting an indirect regulation of the mammary gland. Hypothyroidism is often associated with galactorrhea in nonpregnant women, and in female virgin rats under experimentally induced hypothyroidism, it is known to be related to mammary development. All these phenomena are associated with hyperprolactinemia because of the hypothalamic secretion of thyrotropin-releasing hormone (TRH) induced by hypothyroidism. In addition to stimulating the secretion of pituitary thyroid stimulating hormone, TRH is a potent stimulator of prolactin secretion [25,28].

Prolactin is a single chain peptide hormone secreted by lactotroph cells located in the adenohypophysis [29,30]. It is essential for all stages of mammary gland development and regulates the production and secretion of milk, including protein synthesis, as casein and α -lactalbumin [14,31]. Its secretion is regulated by dopamine, the main prolactin inhibitor factor produced by hypothalamus [1,31]. The stimulatory signal for prolactin secretion may be

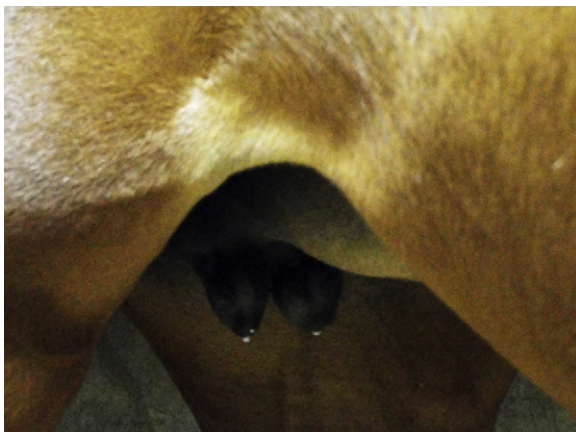


Fig. 1. Swelling of the udder and spontaneous milk ejection.

Download English Version:

<https://daneshyari.com/en/article/10961701>

Download Persian Version:

<https://daneshyari.com/article/10961701>

[Daneshyari.com](https://daneshyari.com)