



African Journal of Urology

Official journal of the Pan African Urological Surgeon's Association
web page of the journal

www.ees.elsevier.com/afju
www.sciencedirect.com



Bladder cancer

Case report

Bladder perivascular epithelioid cell tumors



T. Tricard^{a,*}, S. Lopez^a, V. Lindner^b, J.-L. Jung^a

^a Department of Urology, Hôpitaux Civil de Colmar, 39 Avenue de la liberté, Colmar, France

^b Department of Pathology, Hôpital de Hautepierre, 1 Avenue Molière, Strasbourg, France

Received 23 January 2018; received in revised form 8 February 2018; accepted 29 April 2018; Available online 9 August 2018

KEYWORDS

Bladder;
PEComas;
Perivascular epithelioid
cell sarcoma;
Malignant;
Cystectomy

Abstract

Introduction: Perivascular epithelioid cell tumors (PEComas) of the bladder are infrequent localisation of this mesenchymal cancer with uncertain malignant behavior.

Case report: We report the case of a 74 years old women who was diagnosed a malignant PEComa of the bladder. She necessitated radical cystectomy with orthotopic ileocaecal pouch reconstruction. Histology and immunohistochemistry confirmed the diagnosis of a malignant PEComa of the bladder. We evaluate the literature cases to adjust the prognosis criteria.

Conclusion: Evolution and prognosis evaluation remain hard and could necessitate a radical surgery. Prognosis criteria for the bladder PEComas have to be clarified.

© 2018 Pan African Urological Surgeons Association. Production and hosting by Elsevier B.V. This is an open access article under the CC BY-NC-ND license (<http://creativecommons.org/licenses/by-nc-nd/4.0/>).

Introduction

Perivascular epithelioid cell sarcomas (PEComas) are a rare type of mesenchymal tumors with an unpredictable evolution. PEComas were introduced by Zamboni et al. [1] for mesenchymatous tumors that include angiomyolipoma, clear cell sugar tumor and lymphangiomyomatosis. These lesions have different clinical characteristics and appeared sporadically or in a Bourneville's tuberous sclerosis syndrome [1–3]. PEComas occur frequently in women between 50 and 60 years old. Soft tissues are the most common local-

ization but bones, lung, liver or urogenital organs can be affected [2–8].

PEComas are composed of epithelioid, fusiform, eosinophil or clear cell that express melanocytic or smooth muscular markers [1].

Despite improvement of diagnosis (histological and immunohistochemical criteria), evolution and prognosis evaluation remain hard. Analysis of literature review is difficult because of a small number of cases reported and the short time of follow-up. Most of the cases are benign but few cases of malignant PEComas have been described.

* Corresponding author.

E-mail address: ttricard@msn.com (T. Tricard).

Peer review under responsibility of Pan African Urological Surgeons' Association.

<https://doi.org/10.1016/j.afju.2018.04.005>

1110-5704/© 2018 Pan African Urological Surgeons Association. Production and hosting by Elsevier B.V. This is an open access article under the CC BY-NC-ND license (<http://creativecommons.org/licenses/by-nc-nd/4.0/>).

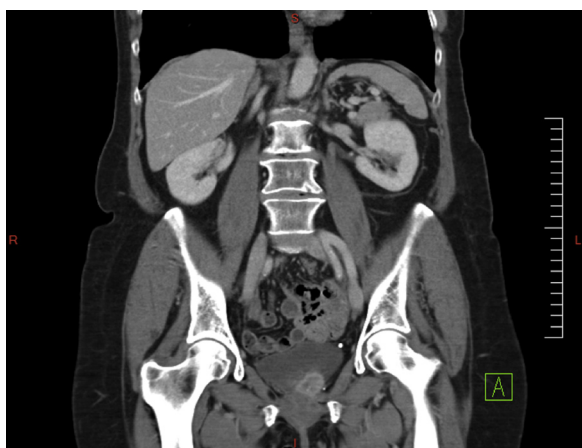

Figure 1 Mass of the left-postero lateral wall of the bladder on CT-scan.

We report a case of a woman of 74 affected by a malignant PEComa of the bladder which was successfully treated by radical cystectomy.

Case report

A 74-year-old woman had a single episode of hematuria, the urological tomodensitometry revealed a mass of the left-postero lateral wall of the bladder (Fig. 1). The cystoscopy confirms the presence of the 2-cm tumor, the cytology was normal. Pelvic MRI showed a 3-cm undefined lesion between vagina and bladder (Fig. 2).

Pathological examination of the bladder's transurethral resection revealed a neoplastic proliferation based on abundant cytoplasmic cells and vesiculous chromatin nucleus without necrosis or angio-invasion. Immunohistochemical studies were performed on formalin-fixed paraffin-embedded tissue using antibodies directed against Melan-A (A103, 1:25, Dako Agilent, Santa Clara, USA), HMB45 (HMB45, Dako, 1:50), smooth muscle α actin (1A4, 1:50; Dako), desmin (NCL-*DER11*, prediluted, Ventana Roche Medical

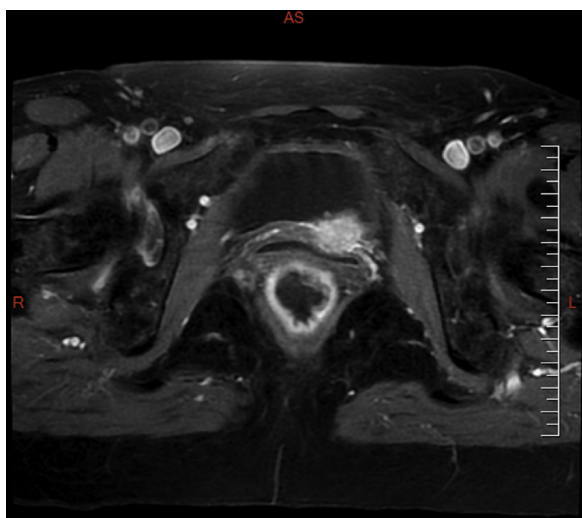


Figure 2 A 3 cm lesion between vagina and bladder on pelvic MRI.

Systems, Tucson, USA), pS-100 (EP-32, 1/400, Clinisciences, Nanterre, France), and TFE3 (MRQ-37, prediluted, Ventana Roche). Appropriate positive and negative controls were employed. This immunohistochemical study was realized on Ventana Roche Benchmark XT with an antigen retrieval process, in a EDTA citrate buffer (pH 8,3) during 30 mn or 60 mn depending of the antibodies (mild or standard cell conditioning, CC1, Ventana Roche), followed by incubation with the different antibody and via the ultraView Universal DAB Detection Kit (Ventana Roche).

These lesion invaded muscle and chorion but bladder mucosa seemed to be respected. Immunohistochemically, the tumor cells demonstrated strong positivity for HMB45 (cytoplasmic), CD68 (cytoplasmic) and TFE3 (nucleus) antibodies, with focal staining by desmin. The neoplastic cells failed to stain with antibodies against vimentin, Melan-A, PS100, smooth muscle actin and epithelial markers: diagnosis of PEComa with uncertain malignant potential was suggested (Fig. 3).

Radical cystectomy with orthotopic ileocaecal pouch reconstruction was performed without any complication and patient was discharged on day 10. Pathological examination confirmed PEComa diagnosis with positivity for HMB45 and TFE3 and negativity for Melan-A and Desmin. Mitotic rate (3/50 HPF) with abnormal mitotic figures, high nuclear grade and hyper cellularity were in favor of a malignant potential of this PEComa (Fig. 4).

Discussion

The World Health Organization defines PEComas as mesenchymal tumors composed of histologically and immunohistochemically distinctive perivascular epithelioid cells [2]. Main differential diagnosis are renal carcinoma metastasis, adrenocortical carcinoma and epithelioid sarcomas.

While PEComas have been described many times in gynecologic tract, retroperitoneum, gastrointestinal tract, pancreas, liver, gallbladder, bones and soft tissues, oro-nasopharyngeal tract, pericardium, few publications reported it for urologic localization.

In the genitourinary tract, PEComas have been described in the kidney [9–13], bladder [7,13–25] (Table 1), prostate [7,25]. Clinical presentation of bladder PEComas are variable in the literature from abdominal pain to hematuria mimicking an urothelial carcinoma. Due to the lack of evidence proof and limited follow-up, it's hard to assess the prognosis of the bladder PEComa. While majority of the reported cases seemed to have benign behavior, some of them were aggressive tumors leading to local recurrences, metastasis and death of the patient, attesting the necessity of an accurate identification and therapeutic strategy.

Diagnosis of bladder PEComas is rare and may be underestimated because of a lack of awareness of both urologist and pathologist community. We think that this pathology has to be known as a differential diagnosis of urothelial carcinoma to allow a much more accurate treatment for the patient.

Patients' follow-up remains critical even after complete resection or benign tumor. In our opinion, bi-annual examination and thoracic-abdominal-pelvic computed tomography scan, associated with annual fibroscopy in case of conservative treatment, should be

Download English Version:

<https://daneshyari.com/en/article/11008246>

Download Persian Version:

<https://daneshyari.com/article/11008246>

[Daneshyari.com](https://daneshyari.com)