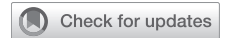

Pirfenidone-Induced Sarcoid-Like Reaction

A Novel Complication



Nicholas A. Kolaitis, MD; Jasleen Kukreja, MD; Kirk D. Jones, MD; Steven R. Hays, MD; and Lorriana E. Leard, MD

Idiopathic pulmonary fibrosis is the most common idiopathic interstitial pneumonia. Prognosis is poor with a median survival <3 years. Pirfenidone is one of two US Food and Drug Administration–approved medications that slow disease progression. We describe the development of lymphadenopathy or a sarcoid-like reaction following initiation of pirfenidone, a complication not previously reported. CHEST 2018; 154(4):e89-e92

KEY WORDS: drug toxicity; idiopathic pulmonary fibrosis; lung transplant; pirfenidone (Esbrit); sarcoid-like reaction

Case Report

A 65-year-old, nonsmoking male developed a chronic cough. In October 2012, a chest CT scan demonstrated traction bronchiectasis with subpleural and basilar predominant reticulation. There was no honeycombing, air trapping, or lymphadenopathy. The patient had no occupational or environmental risk factors for granulomatous disease. He underwent a surgical lung biopsy and pathology was consistent with usual interstitial pneumonia. No granulomas were present. The patient was given a diagnosis of idiopathic pulmonary fibrosis (IPF) on the basis of his clinical presentation and pathology.^{1,2} The patient's functional status continued to decline, and he was referred for lung transplant evaluation.

In April 2015, he was started on pirfenidone, one of the two medications approved to slow disease progression in IPF.³ He tolerated the maximum dose of 801 mg three times per

day; however, his disease continued to progress and he became dependent on supplemental oxygen. A repeat CT scan in January 2016 demonstrated progression of the fibrosis and new diffuse mediastinal and abdominal lymphadenopathy. The subcarinal lymph node measured 2.0 cm in short axis (Fig 1). A PET-CT scan demonstrated hypermetabolism in the lymph nodes, with a maximum standardized uptake value of 16.9.

To evaluate the lymphadenopathy, the patient underwent an endobronchial ultrasound-guided transbronchial needle aspiration of the station 7 subcarinal lymph node. This demonstrated benign lymph node tissue. Chest CT scan in July 2016 demonstrated further increase in adenopathy, with his subcarinal lymph node measuring 2.7 cm. A mediastinoscopy with excisional biopsy of station 2R and 4R lymph nodes demonstrated benign lymph nodes with multiple non-necrotizing granulomas (Fig 2).

ABBREVIATIONS: IPF = idiopathic pulmonary fibrosis

AFFILIATIONS: From the Department of Medicine (Drs Kolaitis, Hays, and Leard), Department of Surgery (Dr Kukreja), and the Department of Pathology (Dr Jones), University of California, San Francisco, School of Medicine, San Francisco, CA.

CORRESPONDENCE TO: Nicholas A. Kolaitis, MD, Department of Medicine, University of California, San Francisco, UCSF Box 0359, 400

Parnassus Ave, San Francisco, CA 94143; e-mail: nicholas.kolaitis@ucsf.edu

Published by Elsevier Inc. under license from the American College of Chest Physicians.

DOI: <https://doi.org/10.1016/j.chest.2018.03.048>

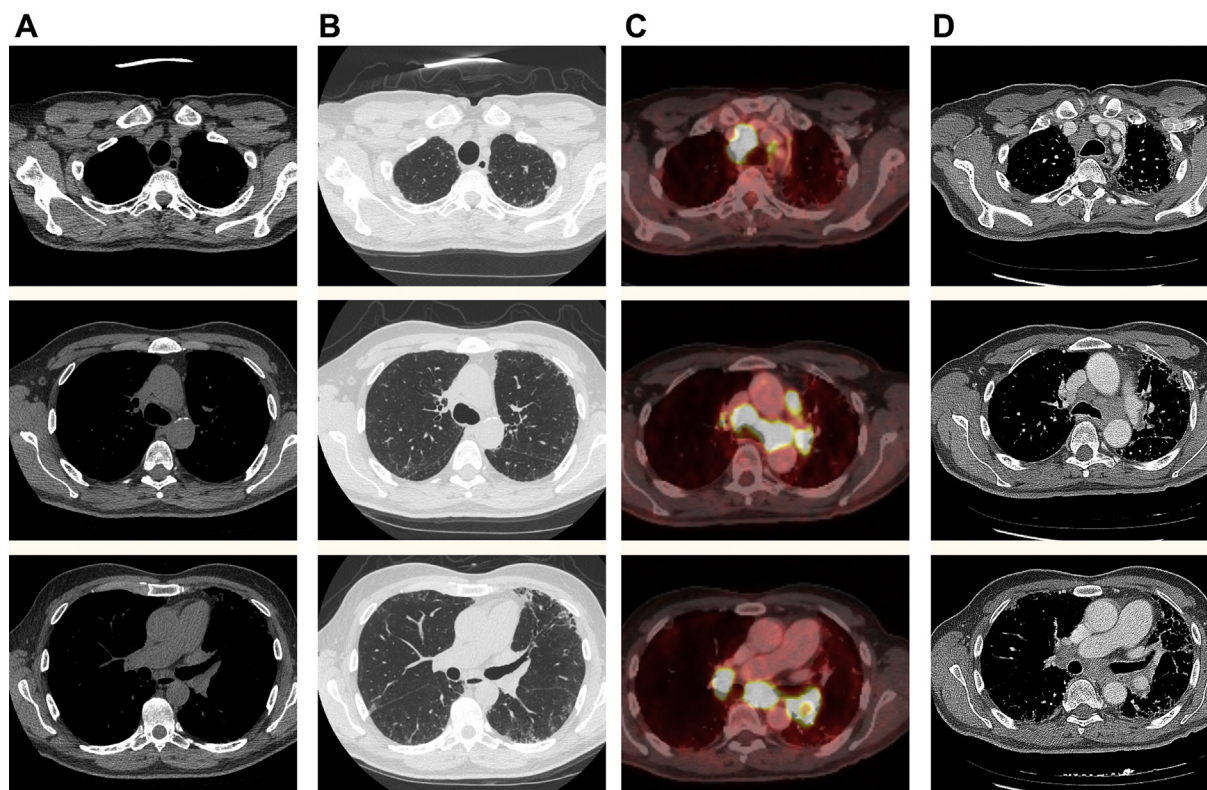


Figure 1 – CT and PET CT scans showing development of diffuse hypermetabolic lymphadenopathy after starting pirfenidone. A, Soft tissue window prior to starting pirfenidone. B, Lung window prior to starting pirfenidone. C, PET-CT after starting pirfenidone. D, Soft tissue window after starting pirfenidone.

The differential diagnosis included sarcoidosis, a sarcoid-like reaction, and infection. Multidisciplinary discussion led to the conclusion that this was most likely a sarcoid-like reaction given the development of lymphadenopathy after initiating pirfenidone; however, sarcoidosis as a new diagnosis could not be ruled out. Evaluation for infectious etiologies was negative. Pirfenidone was discontinued and the patient was listed for lung transplantation.

Follow-up chest CT scan four months after discontinuation of pirfenidone demonstrated stable lymphadenopathy, further strengthening the suspicion of a sarcoid-like reaction. The patient underwent successful bilateral lung transplantation in January 2017. As part of the transplant immunosuppression, the patient received methylprednisolone at a dose of 1,000 mg at the time of transplant and was started on 20 mg of prednisone per day, which was weaned to 10 mg over the course of 1 year. Explant pathology demonstrated a usual interstitial pneumonia pattern of fibrosis with fibroblastic foci as well as scattered non-necrotizing granulomas with a lymphangitic distribution (Fig 2). The lymph nodes demonstrated

fibrosis and non-necrotizing granulomas. Follow-up chest CT scans in the year after lung transplant demonstrated resolution of lymphadenopathy, with all lymph nodes measuring < 1 cm in short axis (Fig 3).

Discussion

We describe the first known case of a sarcoid-like reaction developing after initiation of pirfenidone for IPF. In October 2014, treatment in IPF changed when pirfenidone was approved to slow disease progression in IPF. An integrated analysis of cumulative data from five clinical trials demonstrated high rates of GI discomfort and rash.⁴ There were no reports of hypermetabolic lymphadenopathy or sarcoid-like reactions.

Sarcoidosis is a multisystem granulomatous disease. The initial presentation varies; however, it commonly includes mediastinal lymphadenopathy.⁵ The diagnosis is established with histologic evidence of non-necrotizing granulomas without another explanation.⁶ Sarcoid-like reactions are characterized by the presence of clinical features of sarcoidosis after an inciting event

Download English Version:

<https://daneshyari.com/en/article/11015126>

Download Persian Version:

<https://daneshyari.com/article/11015126>

[Daneshyari.com](https://daneshyari.com)