

Available online at www.sciencedirect.com

ScienceDirect

journal homepage: www.elsevier.com/locate/radcr

Case Report

Perihepatic abscesses caused by dropped appendicoliths in a child

Suprit C. Singh, BS^a, Fabiola Weber, MD^{a,b}, Arthur B. Meyers, MD^{a,b}, Cynthia Reyes, MD^c,
Monica Epelman, MD^{a,b,*}

^aUniversity of Central Florida, College of Medicine, 6850 Lake Nona Blvd., Orlando, FL 32827, USA

^bDepartment of Medical Imaging/Radiology, Nemours Children's Health System/Nemours Children's Hospital, 13535 Nemours Parkway, Orlando, FL 32827, USA

^cDepartment of Pediatric Surgery, Nemours Children's Health System/Nemours Children's Hospital, 13535 Nemours Parkway, Orlando, FL 32827, USA

ARTICLE INFO

Article history:

Received 16 August 2018

Revised 1 September 2018

Accepted 3 September 2018

Keywords:

Appendicitis

CT

Dropped appendicolith

Abscess

ABSTRACT

A dropped appendicolith is a well-known complication of laparoscopic appendectomy that may occur because of stone expulsion from the appendix, before or during surgery, and typically manifests as a focal, subcentimeter area of high attenuation with or without associated abscess. Dropped appendicoliths may act as niduses for infection and may result in the future development of abscess formation. We report the case of a 10-year-old pediatric patient who developed 2 perihepatic abscesses caused by 2 appendicoliths that were inadvertently dropped during laparoscopic surgery.

© 2018 The Authors. Published by Elsevier Inc. on behalf of University of Washington.

This is an open access article under the CC BY-NC-ND license.

(<http://creativecommons.org/licenses/by-nc-nd/4.0/>)

Introduction

Acute appendicitis is a pediatric surgical emergency with a lifetime risk of 9% in males and 7% percent in females [1]. Laparoscopic appendectomy is gaining broader acceptance and is currently the treatment of choice for acute appendicitis in many institutions in North America [2]. When compared to open appendectomy, laparoscopic appendectomy is superior with regard to incidence of readmission, reoperation, and wound infection [3]. Retained or dropped appendicoliths are

an uncommon complication that may occur as a consequence of stone expulsion from the appendix, before or during laparoscopic appendectomies, and typically manifest as a focal, subcentimeter area of high attenuation with or without an associated abscess close to the cecum or Morison's pouch [4]. However, only a handful of cases of perihepatic abscess formation as a result of dropped appendicoliths have been reported [5–9]. To the best of our knowledge, this is the first reported case with 2 concomitant perihepatic abscesses in a pediatric patient.

* Corresponding author.

E-mail address: mepelman@nemours.org (M. Epelman).

<https://doi.org/10.1016/j.radcr.2018.09.003>

1930-0433/© 2018 The Authors. Published by Elsevier Inc. on behalf of University of Washington. This is an open access article under the CC BY-NC-ND license. (<http://creativecommons.org/licenses/by-nc-nd/4.0/>)

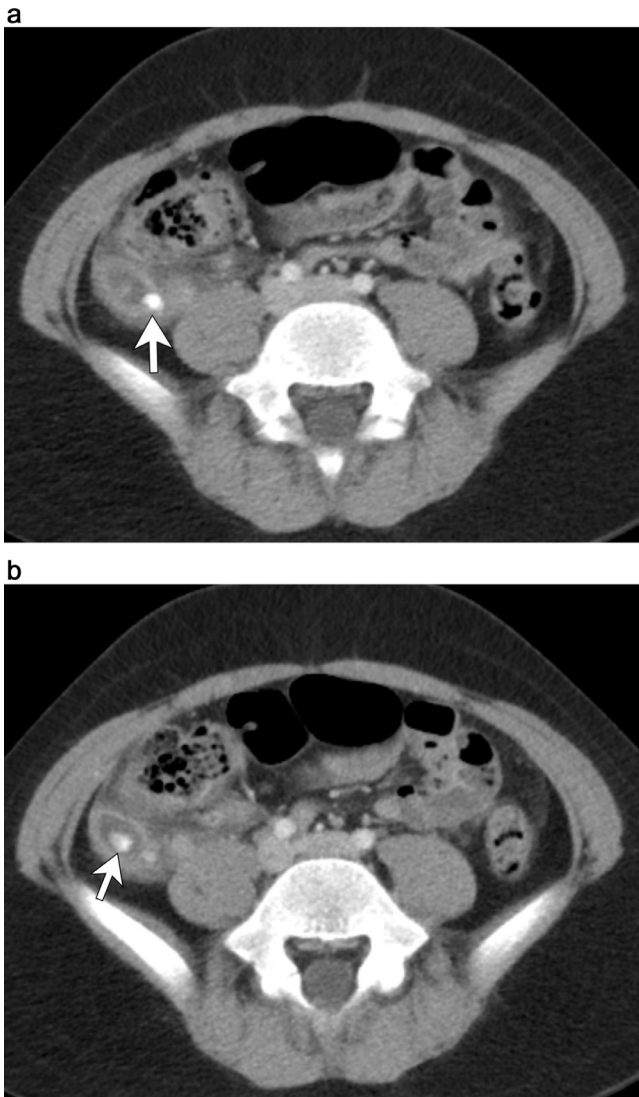


Fig. 1 – A 10-year-old boy with acute appendicitis. a, b. Initial, contrast-enhanced axial CT images of the pelvis demonstrate 2 calcified appendicoliths (arrows) within an enlarged, fluid-filled appendix with surrounding inflammatory changes.

Case report

A 10-year-old male presented to the emergency department as a transfer patient with moderate right lower quadrant (RLQ) tenderness, abdominal pain with no associated nausea or vomiting for 4 days. On examination, he was in acute distress, tachycardic, tachypneic, and there was guarding of the RLQ of the abdomen. Blood tests revealed elevation of the white blood cell count. A contrast-enhanced CT scan of the abdomen and pelvis was performed and confirmed the diagnosis of acute appendicitis (Fig. 1). CT showed inflammatory changes in the RLQ in association to a dilated and fluid-filled appendix. Two appendicoliths were present within the appendix with the appendix measuring up to 13 mm in diameter. A small amount

of free fluid was noted in the pelvis, but no free air or drainable collection was present. Reactive lymph nodes were found in the RLQ.

This patient was then referred for laparoscopic appendectomy. During his appendectomy, the appendix was found to be gangrenous and necrotic as well as densely adherent to the cecum. The appendix broke into 2 pieces during the procedure, and the 2 appendicoliths were not recovered during the initial surgery. No complications were reported perioperatively. He was subsequently discharged the next day.

Three days after surgery, he complained of centralized abdominal pain with slight pyrexia (37.5°C), tachypnea, and tachycardia, which resolved over the next few days.

On postop day 18, he began to have a fever of 39.4°C, elevated white blood cell count, and worsening abdominal pain localized to the right upper quadrant. Temperatures spiked to 40.5°C during hospital admission. The region of pain was under the costal margin in the anterolateral and flank area. He also experienced nausea and vomiting. On physical examination, he was slightly tachycardic and tachypneic. Laboratory values revealed leukocytosis, neutrophilia, and elevated absolute neutrophil count. Contrast-enhanced CT imaging of the abdomen and pelvis revealed 2 small, complex fluid collections measuring approximately 3 cm in diameter in the periphery of the posterior right hepatic lobe with surrounding inflammatory changes. Calcified foci in dependent position were noted within these collections corresponding to the dropped appendicoliths (Fig. 2). There was a minimal amount of perihepatic free fluid. The patient was started on IV antibiotics and underwent diagnostic laparoscopy for appendicolith removal and drainage of the perihepatic abscesses. Drainage of the abscesses was successful but only one of the 2 appendicoliths was successfully removed. The second appendicolith could not be found, despite various documented attempts.

Postoperative, repeat contrast-enhanced CT and ultrasound studies of the abdomen (Fig. 3) confirmed the presence of the retained appendicolith. An additional laparoscopic surgery, which included an ultrasound-guided incision was performed for successful removal of the second retained appendicolith (Fig. 4). After this procedure, the patient remained in the hospital until postop day #8. He was then discharged and after 2 months from his initial appendicitis, he was able to return to normal activity with no further complications.

Discussion

Laparoscopic surgery for appendicitis is a minimally invasive technique resulting in quicker recovery times, fewer wound complications and less pain when compared to open appendectomy [3,10]. Comparatively, laparoscopic surgery and open appendectomy have similar rates for postoperative intraabdominal abscess [3]. Dropped or retained appendicoliths are a well-known complication of laparoscopic appendectomy [10,11]. The incidence of appendicoliths in pediatric patients is higher than that of the adult, and appendicoliths may be found in as many as 50% of appendectomy specimens [10]. Calcified appendicoliths may be seen in imaging studies in up to 30% of the cases of acute appendicitis [12]. Recognition of

Download English Version:

<https://daneshyari.com/en/article/11016824>

Download Persian Version:

<https://daneshyari.com/article/11016824>

[Daneshyari.com](https://daneshyari.com)