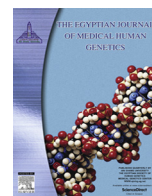


HOSTED BY



Contents lists available at ScienceDirect

# The Egyptian Journal of Medical Human Genetics

journal homepage: [www.sciencedirect.com](http://www.sciencedirect.com)

## Case Report

# Cantu syndrome in an Egyptian child

Rabah M. Shawky\*, Radwa Gamal

Pediatric Department, Genetics Unit, Ain Shams University, Egypt

## ARTICLE INFO

### Article history:

Received 3 January 2018  
Accepted 14 January 2018  
Available online 13 February 2018

### Keywords:

Cantu syndrome  
Hypertrichosis  
Coarse features

## ABSTRACT

We report a 3 month old female, third in order of birth of non consanguineous Egyptian parents with the typical features of Cantu syndrome including coarse features, low frontal hairline, hairy forehead, broad flat nasal bridge, anteverted nares, long philtrum, small low set ears, high arched palate, excess hair on the cheeks, short neck and excess hair over extremities and back. The patient had patent ductus arteriosus ligation, and mild pulmonary hypertension. Our patient has an affected mother which is consistent with autosomal dominant inheritance.

© 2018 Ain Shams University. Production and hosting by Elsevier B.V. This is an open access article under the CC BY-NC-ND license (<http://creativecommons.org/licenses/by-nc-nd/4.0/>).

## 1. Introduction

Cantu syndrome (CS) is a rare congenital systemic disease characterized by congenital hypertrichosis, a distinctive facial appearance, osteochondrodysplasia and cardiomegaly [1]. Affected individuals show great variability in clinical manifestations and severity. Cantú syndrome was first recognized in Mexico in 1982. It is an extremely rare genetic disease and only about 50 cases have been reported worldwide [2].

We report a case with the typical features of Cantú syndrome after taking consent of the parents.

## 2. Case report

A 3 month old female, third in order of birth of non consanguineous Egyptian parents. The patient was delivered at full term by cesarean section. Her birth weight was 3.850 kg. No problems were noted by the mother during pregnancy. The patient was referred to the Genetics Clinic, Pediatric Hospital, Ain Shams University complaining of abnormal features.

At birth, the patient had jaundice which necessitated admission to neonatal intensive care unit (NICU). Congenital heart disease was discovered by echocardiography during admission. At the age of 1.5 months, she had operation to correct patent ductus arteriosus (PDA). The patient had repeated chest infections and was admitted to hospital at the age of 2 months with pneumonia.

The mother had similar coarse features. Family history showed a previous sib death at the age of 40 days with congenital heart disease and the same features.

On examination, her weight was 6 kg (75th percentile), her height was 60 cm (50th percentile), her span was 60 cm and her skull circumference was 41 cm (75th percentile).

The patient had coarse features, low frontal hairline, hairy forehead, broad flat nasal bridge, anteverted nares, long philtrum, small low set ears, high arched palate, excess hair on the cheeks and short neck (Figs. 1 and 2).

She also had excess hair over extremities and back (Fig. 3). The patient had left posterolateral thoracotomy incision scar for PDA ligation (Fig. 4).

Cardiac examination was apparently normal. Abdominal examination revealed umbilical hernia. Neurologic examination and genital examination were apparently normal.

Abdomino-pelvic ultrasonography was normal. ECHO cardiography revealed PDA ligation, patent foramen ovale (PFO), and mild pulmonary hypertension. Skeletal survey was normal.

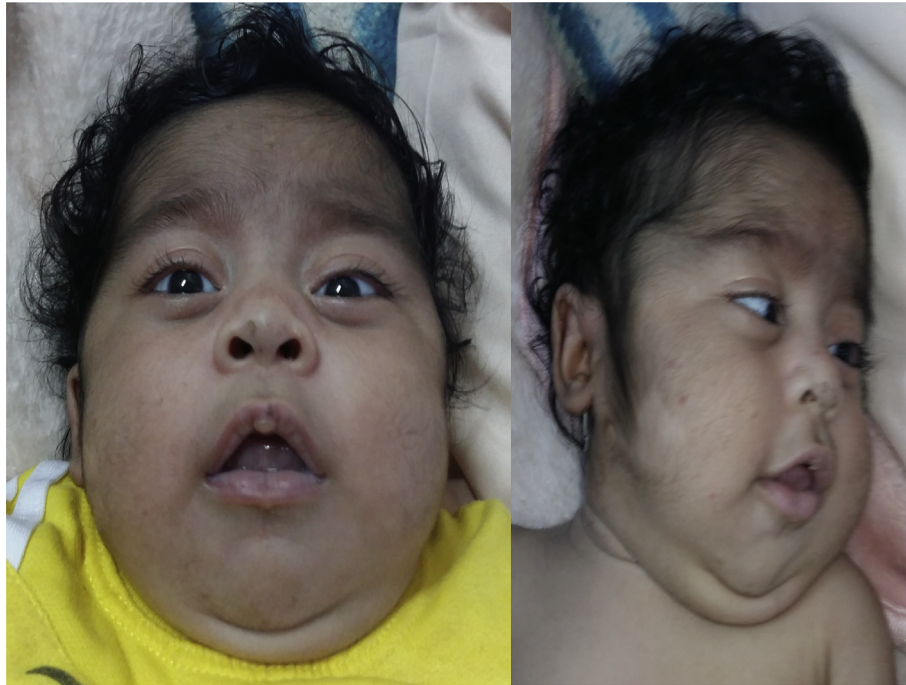## 3. Discussion

Cantú syndrome is a rare condition. About 50 individuals have been reported previously [2]. Cantú syndrome is characterized by congenital hypertrichosis; distinctive coarse facial features; enlarged heart; additional cardiovascular abnormalities that may include patent ductus arteriosus, pericardial effusion, aortic aneurysm and skeletal abnormalities [2].

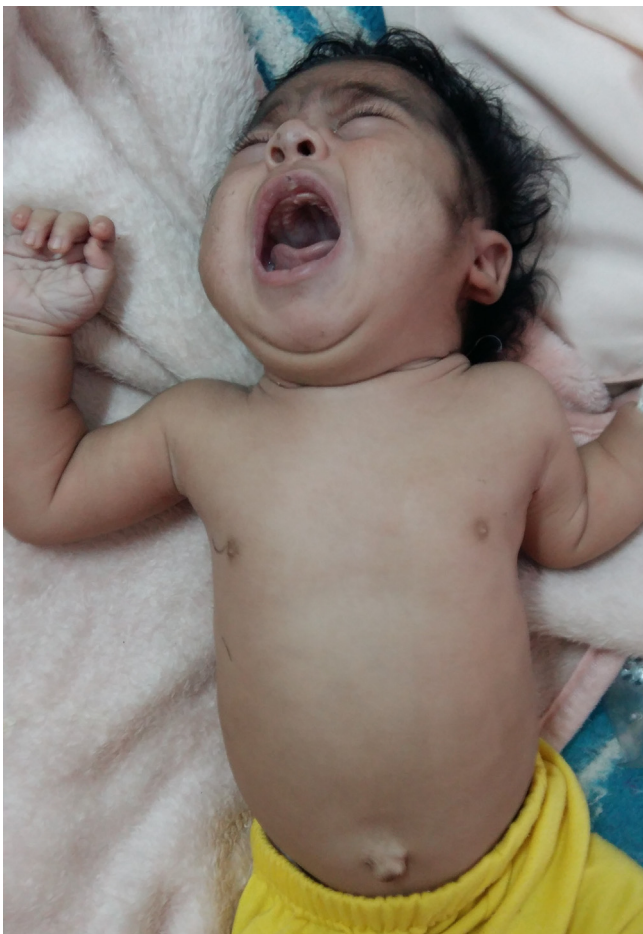We report a 3 month old female with the typical facial features of Cantú syndrome including coarse features, low frontal hairline, hairy forehead, broad nasal bridge, anteverted nares, long phil-

Peer review under responsibility of Ain Shams University.

\* Corresponding author.



**Fig. 1.** Coarse features, low frontal hairline, hairy forehead, broad flat nasal bridge, anteverted nares, long philtrum, small low set ears, excess hair on the cheeks and short neck.



**Fig. 2.** High arched palate and umbilical hernia.

trum, small low set ears, high arched palate, short neck and excess hair on the forehead, face, extremities and back.

All newborns with Cantú syndrome have hypertrichosis with thick scalp hair and excessive hair growth on the forehead that grows down onto the cheeks in front of the ears, back, and extremities as detected in our patient. The hypertrichosis usually persists over time [2].

The facial changes of Cantu syndrome are consistent and evolve over time (broad nasal bridge, epicanthal folds and full mouth). With age the face lengthens, the forehead becoming tall, and the chin prominent [3]. The mother of our patient had similar features.

Many newborns have macrosomia. Ultimate adult height is usually within the normal range; however, short stature has been seen in few individuals [2].

Macrocephaly, often present at birth, typically persists throughout life as detected in our patient. Some individuals who do not have macrocephaly at birth have developed progressive macrocephaly in childhood [2].

Characteristic skeletal abnormalities include thickening of the calvaria, broad ribs, platyspondyly, ovoid vertebral bodies, scoliosis, narrow thorax and shoulders, pectus carinatum, hypoplastic ischium and pubic bones, Erlenmeyer-flask-like long bones with metaphyseal flaring, narrow obturator foramen, and coxa vara. Generalized osteopenia, delayed bone age, and craniosynostosis have also been described [4]. Our patient had normal skeletal survey.

Many infants with Cantu syndrome are born with heart defects. Onset and severity of each heart problem is quite variable among affected individuals [5]. Cardiac manifestations such as patent ductus arteriosus, ventricular hypertrophy, pulmonary hypertension, and pericardial effusions are present in approximately 80% of cases [4]. Our patient had PDA ligation, PFO, mild pulmonary hypertension. Vascular abnormalities reported in this syndrome and which were not detected in our patient include tortuous retinal vessels and multiple tortuous pulmonary arteriovenous communications [3]. Abnormal vasculature in the brain

Download English Version:

<https://daneshyari.com/en/article/11019503>

Download Persian Version:

<https://daneshyari.com/article/11019503>

[Daneshyari.com](https://daneshyari.com)