# Subglottic Extramedullary Plasmacytoma With Light Chain Multiple Myeloma Masquerading as Adult-Onset Asthma

*Yijin Jereme Gan, †Akhil Chopra, and *Jeevendra Kanagalingam, *†*Singapore*

**Summary:** Extramedullary plasmacytoma (EMP) arises outside the bone marrow and can be associated with multiple myeloma (MM). A 55-year-old gentleman, who presented with dyspnea and expiratory wheeze, was diagnosed and treated for asthma. A subsequent relapse 6 months later prompted an Otolaryngology consult. Preliminary findings showed a benign-looking nodular lesion at the subglottis. Work-up at our institution revealed an Fludeoxyglucose (FDG) avid left subglottic lesion with multiple bone metastases on a Positron Emission Tomography / Computed Tomography (PET/CT). The patient underwent a panendoscopy and laser excision of the subglottic lesion with subglottic jet ventilation. Histology showed an EMP. Further work-up revealed the presence of kappa light chain MM with adverse cytogenetics. Patient was treated systemically with lenalidomide, bortezomib, and dexamethasone for four cycles with rapid improvement in his symptoms. We review the literature about EMP of the subglottis with MM. We present the first case of subglottic laryngeal EMP with MM managed via $CO_2$ laser excision.

**Key Words:** Multiple myeloma–Extramedullary plasmacytoma–Laser–Subglottis–Lenalidomide.

## INTRODUCTION

Plasmacytoma is a frequent complication of multiple myeloma (MM) either at diagnosis or with disease progression. Plasmacytoma is defined as a tumor mass, which is composed of aberrant monoclonal neoplastic plasma cells. When these lesions are isolated with no other evidence of MM, they are called solitary plasmacytomas. When a solitary plasmacytoma is present in bone marrow, it is termed medullary and when it is present in soft tissue, it is termed extramedullary. Plasmacytoma is present at the time of initial diagnosis in 7–17% of patients with MM and appears during the course of the disease in 6–20% of the patients.[1–3] Extramedullary plasmacytoma (EMP) represents less than 1% of head and neck malignancies; however, more than 90% of EMPs are diagnosed in the head and neck.[4] The majority of these lesions are found in the aerodigestive tract, with the nasal cavity and paranasal sinuses, the most common sites of presentation.[5]

It is important to distinguish EMP from other plasma cell dyscrasias such as MM for the purposes of prognosis and treatment.

## CASE REPORT

A 55-year-old gentleman initially presented in Myanmar with shortness of breath and intermittent expiratory wheeze. He was diagnosed and treated with presumptive diagnosis of asthma for about 6 months. Treatment included inhalers and steroids. His symptoms did improve with therapy but then recurred. His past medical history included a recent diagnosis of diabetes mellitus, which was being managed with diet control. There was no other relevant medical, surgical, or family history. He was an ex-smoker with a 6 pack-year smoking history.

He was referred to a local ear, nose, and throat (ENT) specialist for further evaluation. The patient underwent a computed tomographic (CT) scan of the neck that showed irregular soft tissue mass in the larynx, which was occluding the airway causing stridor. A CT scan of the chest on the same day was essentially normal. A bronchoscopy done locally in June 2011 apparently revealed a benign-looking nodular lesion at the subglottic level. Bronchial washings were suspicious for invasive squamous cell carcinoma. Laboratory blood testing was essentially unremarkable.

This patient was referred in August 2011 to the head and neck unit at a tertiary hospital in Singapore for a second opinion. On further questioning, he described dysphonia for 4 months and weight loss of 20 kg over the past year. On examination, we noted a soft stridor. Also, no neck nodes were noted. Flexible nasopharyngolaryngoscopy showed a significant left subglottic lesion and a small contact ulcer at the left arytenoid process, with mobile vocal folds (Figure 1) The patient underwent a Positron Emission Tomography/Computed Tomography (PET/CT) scan (Figure 2) for the presumptive diagnosis of a head and neck cancer. This showed a Fludeoxyglucose (FDG) avid lesion in the left subglottis (max SUV 3.8) crossing midline posteriorly, increased activity in bilateral cricoarytenoid joints (maxSUV 5.2) and multiple low grade to mildy FDG avid skeletal metastases. These findings were thought to be somewhat inconsistent with the presentation of a squamous cell carcinoma of the head and neck region. A panendoscopy was done in August 2011 with subglottic jet ventilation and showed a submucosal mass in the subglottis involving the posterior and left lateral aspects, extending superiorly to the true folds. The airway was patent (Figure 3). This tumor was excised with a $CO_2$ laser at setting of 5 W (Figure 4). No other lesions were seen. The histology of this specimen showed EMP. Immunochemistry showed atypical plasmacytoid cells to be positive for CD138 and CD79. In Situ Hybridization confirmed light chain restriction with positive reaction with kappa and negative with lambda. The patient was then

Accepted for publication October 21, 2013.

From the *Department of Otorhinolaryngology, Tan Tock Seng Hospital, Singapore; and the †Medical Oncology, Johns Hopkins Singapore International Medical Centre, Singapore.

Address correspondence and reprint requests to Jeevendra Kanagalingam, Department of Otolaryngology, Tan Tock Seng Hospital, 11 Jalan Tan Tock Seng, Singapore 308433. E-mail: jeevekana@gmail.com

Journal of Voice, Vol. 28, No. 3, pp. 394.e1-394.e4
0892-1997/$36.00
© 2014 The Voice Foundation
http://dx.doi.org/10.1016/j.jvoice.2013.10.016

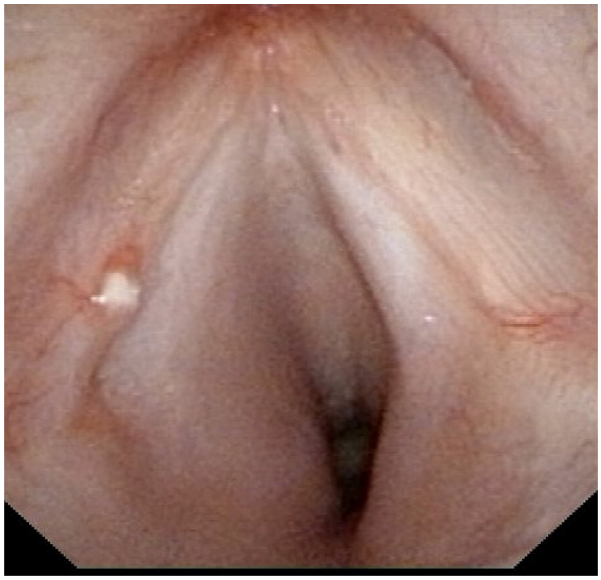

**FIGURE 1.** Initial consult, photo taken in clinic.

referred to a medical oncologist for further work-up and management.

Serum protein electrophoresis did not reveal a paraprotein band. However, serum immunofixation showed a free kappa light chain band. IgG, IgA, and IgM levels were all below normal limits. Urine protein electrophoresis showed two bands in the levels in the alpha and beta region. Urine immunofixation revealed these bands to be free kappa light chains. Beta-2 microglobulin was exactly at the higher limit of cutoff at 1900. A serum kappa lambda light chain assay was performed that showed extremely elevated serum kappa free light chains at 1281 mg/L (higher limits 20), normal serum lambda free light chain, and extremely abnormal kappa lambda ratio at 220.90 (normal range 0.26–1.65). A diagnostic bone marrow aspirate and biopsy including flow cytometry and cytogenetic analysis confirmed the presence of a clonal plasma cell population consistent with the diagnosis of MM. A 24-hour quantitative Bence Jones (BJ) protein of the urine revealed that 2.9 g of BJ proteinuria per day was positive for BJ proteinuria. Fluorescence in situ hybridization testing revealed the presence of only one copy of *IGH* gene at 14q32 indicating either monosomy or loss of gene segment and gain of CCND1 gene at chromosome 11, monosomy 14, and monosomy 17.

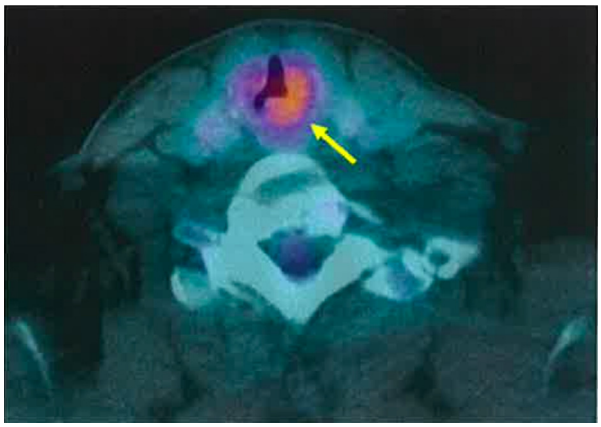

**FIGURE 2.** PET/CT axial cut.

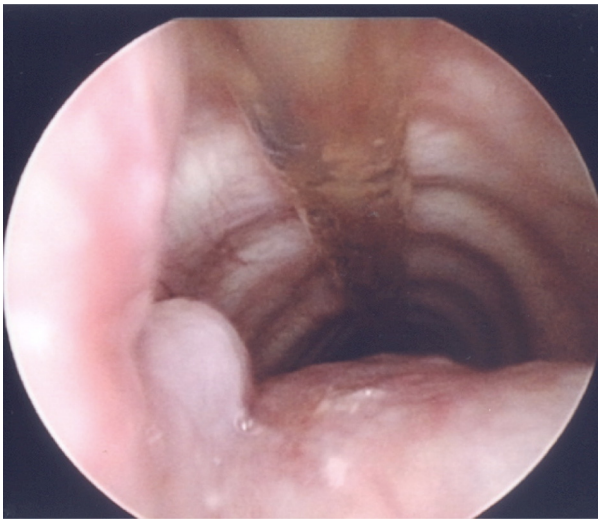

**FIGURE 3.** Prelaser excision, photo taken intraoperatively.

In summary, the patient was diagnosed with high-risk kappa light chain MM along with a solitary EMP. Based on the presence of adverse cytogenic features, induction therapy with lenalidomide, bortezomib, and dexamethasone was initiated. The myeloma responded well to four cycles of the induction regimen with achievement of a very good partial response. In addition, a repeat endoscopy 4 months later and, subsequently, 2 years later revealed an excellent response as well with a much more patent airway as shown (Figures 5 and 6 correspondingly). We will be seeing the patient at six monthly intervals for a long duration.

## DISCUSSION

Solitary EMP of the larynx with associated MM is rare but has been reported previously. Werner in 1991 reported a total of

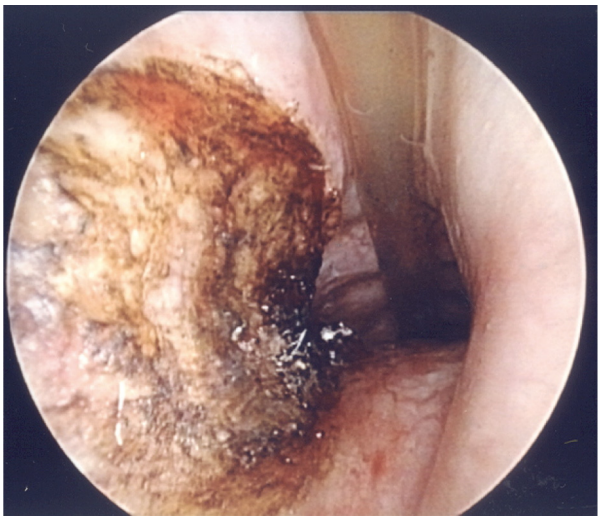

**FIGURE 4.** Postlaser excision, photo taken intraoperatively.

Download English Version:

https://daneshyari.com/en/article/1101971

Download Persian Version:

https://daneshyari.com/article/1101971

Daneshyari.com