



Contents lists available at ScienceDirect

International Journal of Surgery Case Reports

journal homepage: www.casereports.com

Adductor magnus muscle primary hydatid cyst rare unusual site: A case report

Samer Makki Mohamed Al-Hakkak

Department of surgery, Faculty of medicine, Jabir Ibn Hayyan Medical University, Iraq

ARTICLE INFO

Article history:

Received 23 August 2018
 Received in revised form 6 September 2018
 Accepted 12 September 2018
 Available online 21 September 2018

Keywords:

Hydatid cyst
 Intramuscular
 Adductor magnus muscle
 Thigh
 Unusual site
 Primary

ABSTRACT

INTRODUCTION: The preferred localization of human echinococcosis is the liver and lungs, which account for 85% of cases. Primary musculoskeletal hydatidosis are seldom reported in literature and their incidence is unknown. Primary solitary intramuscular hydatid disease is rare, even in countries in which echinococcosis is endemic and accounts for 1% of all human echinococcosis sites.

CASE PRESENTATION: 37-year-old male farmer presented with primary hydatid cyst of the upper medial side of right thigh (Inside adductor magnus muscle) who was managed successfully by preoperative and postoperative dual treatment of albendazole together with surgery.

DISCUSSION: This site of localization has not been reported previously. It is essential to establish definitive preoperative diagnosis of skeletal muscle hydatid cysts. This contraindicates certain treatment options like marginal excision or incisional biopsy due to the likelihood of dissemination and anaphylactic shock on spillage. Pericystectomy remains treatment of choice in musculoskeletal hydatid cysts.

CONCLUSION: Hydatid disease should be included in the differential diagnosis of muscular masses, regardless of its location, especially in endemic areas.

© 2018 The Author(s). Published by Elsevier Ltd on behalf of IJS Publishing Group Ltd. This is an open access article under the CC BY-NC-ND license (<http://creativecommons.org/licenses/by-nc-nd/4.0/>).

1. Introduction

Hydatid disease (HC) is a parasitic infestation caused by Echinococcus species. Species mainly involved include granulosus, multilocularis, and oligarthrus, with granulosus commonly responsible for cysts in predators such as dogs, wolves, and foxes as well as intermediate hosts such as sheep, goats, and cattle [1]. Humans are a coincidental intermediate host. The disease is more frequent in the Middle East, Central Europe, Australia, South America and the Mediterranean basin, where livestock breeding is very rampant. Several strains of granulosus appear to be commonly found in North America, Morocco, Tunisia, Kenya, Iraq, Iran, Kazakhstan, western China, and Argentina. Parasite larvae can develop in any part of the human body with the liver (68.8–80%) and lungs (10–22.4%), representing the most frequent localizations. Other rare localizations reported in the literature include the spleen, peritoneum, skeleton, kidney, brain, cardiac muscle and even subcutaneous [2,3]. Muscular hydatid cysts are usually secondary in nature, resulting from migration of larvae from a primary site after spontaneous or trauma-induced cyst rupture or could even be iatrogenic after the release of parasite material during invasive treatment procedures. Primary musculoskeletal hydatid cysts are rare not to mention adductor magnus muscle hydatid cysts even in countries endemic

to Echinococcus. Voluntary muscles are a very rare site of infection, counting for less than 1% of the total [4]. In line with SCARE guideline, we reported a case of adductor magnus HC [5].

2. Case presentation

A 37-year-old man, Iraqi origin, living in the rural area was admitted to our unit complaining of a slight painful swelling of the right thigh. The patient notices the swelling over about 3 weeks and was associated with recent discomfort and when he compares both thighs he notices that the right one tenses and slightly larger in diameter without fever or rigors, and pruritus. The patient did not reveal any history of trauma to his thigh or prior medication. He was afebrile on admission with good general conditions, and physical examination revealed a slight tender right upper medial side of the thigh with slight distension without any features of acute inflammation overlying skin, the overlying skin was normal. No bruit or venous hum was heard as in Fig. 1a and b.

Patient sends for an ultrasound which shows cystic lesion deep intramuscular upper medial aspect of right thigh inside the muscle as shown in Fig. 2. Routine blood investigations, we also performed abdominal US, chest X-ray, and cranial MRI in order to rule out any involvement of the body. All imaging studies detected no other cyst in other parts of the body. So the hydatid cyst in the adductor magnus muscle in our patient assumed to be primer muscle hydatidosis. Then Magnetic resonance Imaging (MRI) depicted a unilocular cyst without septations deep inside adductor magnus

E-mail address: sammerhakak1971@yahoo.com

<https://doi.org/10.1016/j.ijscr.2018.09.026>

2210-2612/© 2018 The Author(s). Published by Elsevier Ltd on behalf of IJS Publishing Group Ltd. This is an open access article under the CC BY-NC-ND license (<http://creativecommons.org/licenses/by-nc-nd/4.0/>).

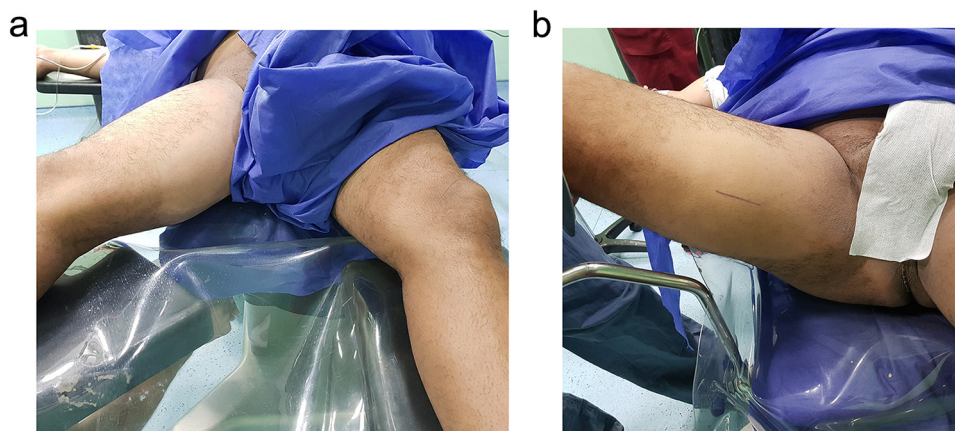


Fig. 1. (a) Comparison between thighs, deep intramuscular, slight difference appear, (b) Marked skin incision over right thigh.

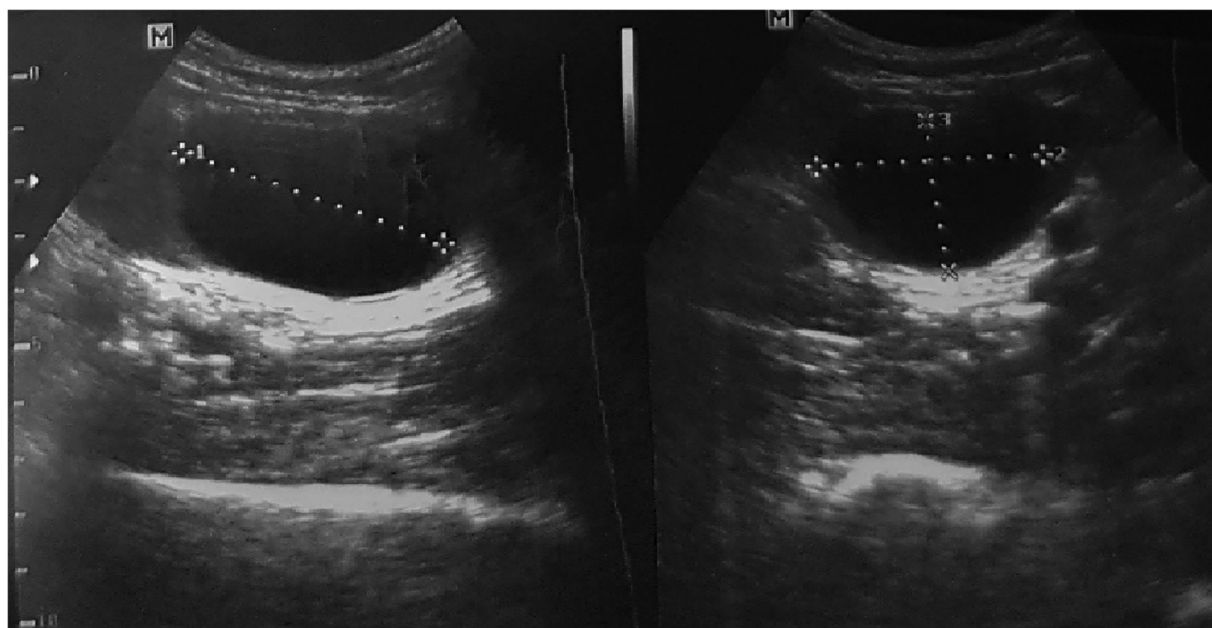


Fig. 2. Ultrasound picture show cystic mass deep intramuscular.

muscle about 100×65 mm, Serology for Echinococcus by ELISA (Ridascreen Echinococcus IgG; R-Biopharm, Darmstadt, Germany) was positive, measuring 2.5 IU (cut-off >1.1). Based on these findings, a diagnosis of hydatid cyst was performed. MRI features were suggestive of hydatid cystic mass without infiltrating bone nor surrounding neurovascular structures as in Figs. 3a, b and 4). Patient was prepared for elective surgery with consent and anthelmintic therapy was initiated preoperatively for 5 days, Incision done over site of location of the cyst until reach the adductor magnus muscle the care was taken to avoid spillage, 10% Betadine soaked mops were placed around the cyst suction tube nearby and needle aspiration of clear fluid then the injection of scolicalid agent cetrimide (1.5%) instilled in it as in Fig. 5. Wait 5 min then incision on cyst did, through meticulous pericystectomy along surrounding muscle fibers Fig. 5a and b. The cyst was unilocular containing clear fluid, after the aspiration process, cetrimide solution was applied into the cavity and irrigation was performed with isotonic saline. Finally, the drain was fixed and the tissues were repaired. The diagnosis of a hydatid cyst was confirmed with macroscopic and microscopic histopathological examinations after removal of the

mass as in Figs. 6 and 7. Albendazole treatment was continued for three months postoperatively with 15 mg/kg/d.

3. Discussion

Primary skeletal muscle hydatid cyst is very rare because implantations at this site require passage through the filters of the liver and lung. In addition, the intramuscular growth of cysts is hindered by muscle's contractility and lactic acid content [6]. The patient with muscular echinococcosis should

be evaluated in order to determine whether there is another focus of dissemination since the disease is generally located in other parts of the body especially hepatic and pulmonary regions [6,7]. We excluded the other organ involvement by the careful clinical and radiological examination of the patient, and the localization in the adductor magnus muscle was therefore assumed to be primer muscle hydatidosis. Diagnosis of human echinococcosis remains highly dependent on imaging techniques to detect the cystic space occupying lesion [7]. US is particularly useful in the diagnosis of hydatid cyst when the daughter cysts and hydatid

Download English Version:

<https://daneshyari.com/en/article/11032671>

Download Persian Version:

<https://daneshyari.com/article/11032671>

[Daneshyari.com](https://daneshyari.com)