



Case report

Case series: Use of stromal lenticule as patch graft

Yong Ju Song^a, Sumi Kim^b, Gil Joong Yoon^{c,*}^a Department of Ophthalmology, Chosun University College of Medicine, Gwangju, South Korea^b Department of Dentistry, Hallym University Gangnam Sacred Heart Hospital, Seoul, South Korea^c Happy Eye21 Hospital, Gwangju, South Korea

ARTICLE INFO

Keywords:

Stromal lenticule

Patch graft

Ahmed valve tube exposure

Bullous keratopathy

ABSTRACT

Purpose: To introduce cases of the use, as patch grafts, of stromal lenticules obtained by small incision lenticule extraction (SMILE) surgery.

Observations: Case 1 was a 79-year-old man who presented with Ahmed-valve-tube exposure in his left eye. His uncorrected visual acuity (UCVA) was 20/40, best-corrected visual acuity (BCVA) 20/32, and intraocular pressure (IOP) 11 mmHg. He was treated with stromal lenticule patch that had been extracted by SMILE surgery. The patch was positioned underneath of the conjunctiva and sutured to it. At postoperative 8 months, the graft site was well maintained without Ahmed valve-tube exposure, the UCVA was 20/32, BCVA 20/20, and IOP 12 mmHg.

Case 2 was a 60-year-old man who presented with Ahmed-valve-tube exposure in his right eye. His UCVA was finger-count (FC) 30 cm, his BCVA 20/125, and his IOP 14 mmHg. He was treated with stromal lenticule patch by the same method as employed in case 1. At postoperative 10 days, tube re-exposure and displacement of the Ahmed valve external plate toward the limbus area occurred due to loosening of the anchoring suture. So, we removed the Ahmed valve device, which had been implanted in the supero-temporal area, and performed new Ahmed valve implantation, with a stromal lenticule flap instead of a partial scleral flap, in the supero-nasal area. As of 6 months post-reoperation, the patient was stable, with UCVA 20/200, BCVA 20/40 and IOP 13 mmHg.

Case 3 was a 74-year-old man who presented with bullous keratopathy in his right eye, which was blind. Due to severe adhesions, his conjunctiva could not cover the entire cornea. Therefore, we performed a stromal lenticule patch graft with conjunctival advance flap. At postoperative 3 months, the patient's right eye was stable, without displacement or melting of the lenticule graft.

Conclusions & importance: It is suggested that the stromal lenticule, with its biocompatibility, sufficient strength, ease of handling and low cost, is a useful patch graft for various therapeutic purposes in the ophthalmic field.

1. Introduction

Various types of patch grafts have been used in the treatment of various diseases in the field of ophthalmology. Patch grafts have been used with the cornea, sclera, pericardium, fascia lata, dura mater and amniotic membrane.¹ Recently, there was a report on the patch-graft treatment of corneal perforation by SMILE surgery-extracted stromal lenticules with the amniotic membrane.²

The utility of the stromal lenticule as an alternative tissue to the corneal stroma for autologous future re-implantation or allogenic donor implantation has been reported. There have been studies on stromal expansion with a lenticule for ultrathin-cornea crosslinking and lenticule implantation for keratoconus, hyperopia and presbyopia.^{3–7} The utility of the stromal lenticule as a patch graft in the treatment of other

ocular diseases, however, has not been explored, the one exception being the above-noted study on corneal perforation.

We herein report the application of the stromal lenticule as a patch graft for the treatment of 2 patients with Ahmed valve exposure and 1 patient with bullous keratopathy.

2. Case reports

2.1. Case 1

A 79-year-old Asian man visited our clinic due to ocular pain and foreign-body sensation in the left eye. His uncorrected visual acuity (UCVA) was 20/40, best-corrected visual acuity (BCVA) 20/32, and intraocular pressure (IOP) 11 mmHg. The patient had undergone

* Corresponding author. Happy Eye21 Hospital, 950, Mujin-daero, Seo-gu, Gwangju, 61932, Republic of Korea.

E-mail address: yoonalpha@gmail.com (G.J. Yoon).

<https://doi.org/10.1016/j.ajoc.2018.09.009>

Received 15 June 2018; Received in revised form 20 September 2018; Accepted 25 September 2018

Available online 27 September 2018

2451-9936/© 2018 The Authors. Published by Elsevier Inc. This is an open access article under the CC BY-NC-ND license

(<http://creativecommons.org/licenses/by-nc-nd/4.0/>).

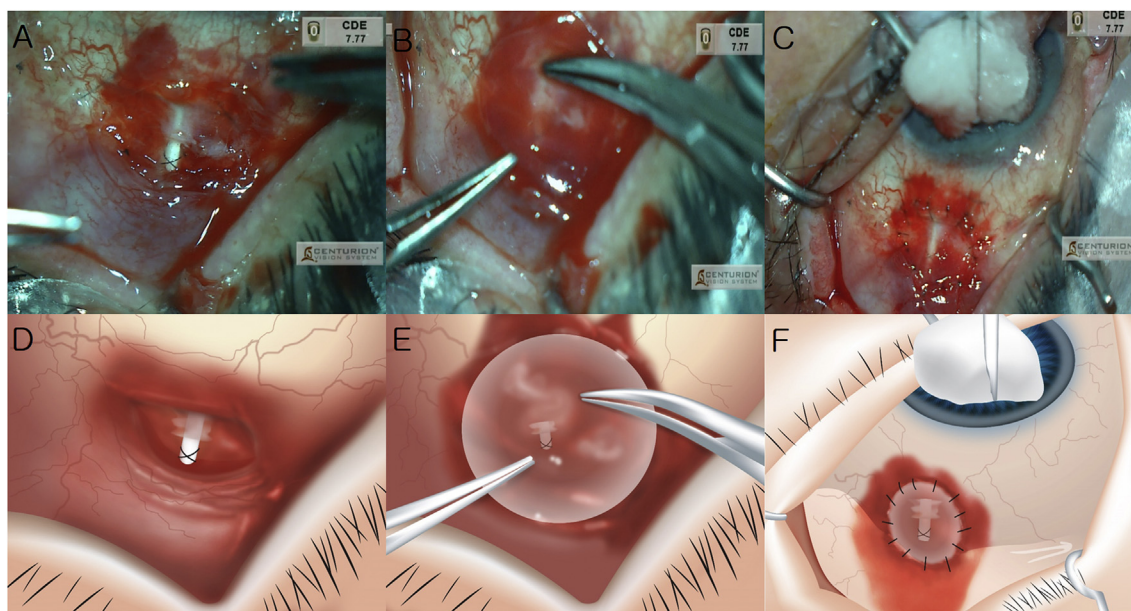


Fig. 1. Treatment procedure of Ahmed valve tube exposure using lenticule in case 1.

(A) Ahmed valve tube was exposed at supero-temporal area.

(B) Stromal lenticule was placed over the Ahmed valve-exposure area.

(C) Stromal lenticule was placed underneath the conjunctiva and sutured with surrounding conjunctiva.

(D) Illustration of fig.(A)

(E) Illustration of fig.(B)

(F) Illustration of fig.(C).

cataract surgery in both eyes 6 years previously and Ahmed valve implantation with partial scleral flap for uveitic glaucoma in the left eye 1 month previously. His left eye was being treated with 1 anti-glaucoma medication. On slit lamp examination, the Ahmed valve tube, which was fixed to the sclera with sutures, was exposed. We determined to repair the exposure site using a stromal lenticule.

The stromal lenticule was extracted by SMILE surgery on the day of Ahmed valve-exposure repair surgery. The surgery was performed using a 120 μm cap thickness, a 7.9 mm cap diameter, a 6.5 mm lenticule diameter and a 120° side-cut angle. Lenticule donors with corrected spherical equivalents of 6 diopters or more had been selected in order to be able to obtain a stromal lenticule thickness of more than 100 μm . Testing for human immunodeficiency virus, syphilis, herpes virus and hepatitis was performed. The lenticule donor did not have any history of corneal disease, infections, immune deficiency or ocular surgery.

In performing the graft surgery, first, debridement of the surrounding conjunctiva was performed at the site of Ahmed valve exposure (Fig. 1A). Then, the stromal lenticule (thickness: 100 μm ; diameter: 6.5 mm) was placed underneath the conjunctiva and centered over the Ahmed valve-exposure area (Fig. 1B). Using nylon 10-0 with spatula needle, 16 interrupted sutures were performed to connect the lenticule to the surrounding conjunctiva (including tenon) tissue (Fig. 1C). We made a watertight suture to prevent leakage of aqueous humor. This is the one of reasons of tube re-exposure. The operation was completed by confirming the proper tension of the sutures.

At postoperative 8 months, the suture site was well maintained without Ahmed valve-tube exposure (Fig. 3A), the UCVA was 20/32, the BCVA 20/20, and the IOP 12 mmHg.

2.2. Case 2

A 60-year-old Asian man visited our clinic due to ocular pain and foreign-body sensation in the right eye. His UCVA was finger-count (FC) 30 cm, his BCVA 20/125, and his IOP 14 mmHg. He had undergone cataract surgery, pars plana vitrectomy and silicone oil infusion for

diabetic tractional retinal detachment in the right eye 6 months previously. Five months previously, the silicone oil had been removed, but it was determined that he required glaucoma surgery and Ahmed valve implantation with partial scleral flap for neovascular glaucoma (NVG) in the supero-temporal area. His right eye was being treated with 2 anti-glaucoma medications. After 5 months of glaucoma surgery, on slit lamp examination, the distal portion of the Ahmed valve tube was exposed (i.e., it was not covered by the scleral flap). We treated the patient by stromal lenticule graft, following the same procedure as in case 1.

The stromal lenticule was extracted by SMILE surgery on the day of Ahmed valve-exposure repair surgery. Then, the stromal lenticule (thickness: 100 μm ; diameter: 6.5 mm) was placed underneath the conjunctiva and centered over the Ahmed valve-exposure area. Using nylon 10-0 with spatula needle, 10 interrupted sutures were performed to connect the lenticule to the surrounding conjunctiva (including tenon) tissue.

At postoperative 1 week, the suture site was well maintained without Ahmed valve tube exposure. However, at postoperative 8 days, lenticule melting was observed in the supero-temporal area of the recipient site. At postoperative 10 days, tube re-exposure and displacement of the Ahmed valve external plate toward the limbus area occurred due to loosening of the anchoring suture. So, at postoperative 12 days, we removed the Ahmed valve device, which had been implanted in the supero-temporal area, and performed new Ahmed valve implantation, with a stromal lenticule flap instead of a partial scleral flap, in the supero-nasal area. The tube put into sulcus to avoid further corneal damage.

As of 6 months post-reoperation, the patient was stable with UCVA 20/200, BCVA 20/40 and IOP 13 mmHg (Fig. 3B).

2.3. Case 3

A 74-year-old Asian man visited our clinic due to bullous keratopathy in the right eye, which required routine exchange of a therapeutic

Download English Version:

<https://daneshyari.com/en/article/11033563>

Download Persian Version:

<https://daneshyari.com/article/11033563>

[Daneshyari.com](https://daneshyari.com)