



## Case report

## Trigeminal hypertrophic interstitial neuropathy presenting as unilateral proptosis, ptosis, tearing, and facial neuralgia



Elizabeth R. Duvall<sup>a</sup>, Jennifer Pan<sup>a</sup>, Kim Tien T. Dinh<sup>a</sup>, Majd Al Shaarani<sup>b</sup>, Golden Pan<sup>c</sup>,  
Marlyn P. Langford<sup>a</sup>, William A. Byrd<sup>a,\*</sup>

<sup>a</sup> Department of Ophthalmology, Louisiana State University Health Sciences Center, Shreveport, LA, 71130, USA

<sup>b</sup> Department of Pathology, Louisiana State University Health Sciences Center, Shreveport, LA, 71130, USA

<sup>c</sup> Medical Imaging Diagnostic Associates, Laredo Medical Center, Laredo, TX, 78045, USA

## ARTICLE INFO

## Keywords:

Exophthalmos  
Onion bulb  
Schwann cell  
Trigeminal nerve  
Cranial nerve

## ABSTRACT

**Purpose:** To show the utility of MRI and histology in diagnosing rare cases of trigeminal hypertrophic interstitial neuropathy (HIN).

**Observations:** A 57-year-old African-American woman presented with a 4-year history of right eye proptosis with tearing, headaches, and worsening right-sided trigeminal neuralgia symptoms and jaw pain. HIV and diabetes tests were negative and thyroid function was normal. MRI identified abnormal thickening of all trigeminal nerve divisions and proptosis secondary to right trigeminal nerve V1 division enlargement. The excised tissue contained S-100 positive Schwann cells in an onion-bulb pattern. Headaches resolved, but proptosis and mild trigeminal neuralgia remained 1 year post-surgery.

**Conclusions and importance:** Trigeminal HIN is very rare, but presents as chronic progressive ocular symptoms with trigeminal neuralgia. Trigeminal nerve hypertrophy is identified by MRI and confirmed histopathologically by detection of Schwann cells in an onion bulb formation.

## 1. Introduction

The list of differential diagnoses for unilateral proptosis is extensive. The most common cause of proptosis in adults is thyroid orbitopathy, but other etiologies should be considered including inflammatory orbital disorders, vascular orbital disorders, intraorbital neoplasms, metastatic orbital tumors, retrobulbar hemorrhage, Cushing's syndrome, and orbital fracture.<sup>1</sup>

Unilateral proptosis caused by hypertrophic interstitial neuropathy (HIN) of a retro-orbital nerve has not been reported, to our knowledge. Thirty-seven years ago the first case of focal trigeminal HIN presenting with facial trigeminal analgesia with no ocular involvement was reported.<sup>2</sup> The first histologically documented case of focal trigeminal HIN with ocular symptoms was reported a little over 25 years ago.<sup>3</sup> Neuroimaging utilizing CT and MRI clearly displayed the unilateral hypertrophic trigeminal nerve and the neuro-pathological evaluation of the excised tissue was significant for concentric rings of hypertrophic Schwann cells in an "onion bulb" formation; pathognomonic for HIN.<sup>4–6</sup> Thus, we present the third case of focal trigeminal HIN, and the second case to present with ocular symptoms, be detected by MRI, and be confirmed by histopathological detection of Schwann cells in an onion

bulb formation. Based upon current cases, the diagnosis of trigeminal HIN in a patient with unilateral proptosis can be aided significantly by careful medical history and a comprehensive neuro-exam with MRI studies.

## 2. Case report

A 57-year-old African-American woman presented to the Eye Clinic at Louisiana State University Health Sciences Center in Shreveport, LA in late February 2015 with a 4-year history of right eye proptosis and excessive tearing. She complained of generalized headaches and was seen by neurology, diagnosed with migraine headaches, and given to-piramate without improvement of symptoms. A careful review of systems revealed pain triggered by chewing, speaking, and brushing her teeth, as well as numbness, burning, and tingling in the trigeminal V1 and V2 dermatomal distributions. She reported right-sided facial muscle spasms and hyperesthesia to external stimuli. There was no history of periorbital lesions, herpetic keratitis, trauma to the head, or infection. Her past medical history was negative for diabetes, thyroid disease, cancer, oral herpes, recent infection, and recent head trauma. Her family history was negative for autoimmune disorders and

\* Corresponding author. Department of Ophthalmology, Louisiana State University Health Sciences Center, Shreveport, LA, 71130-3932, USA.

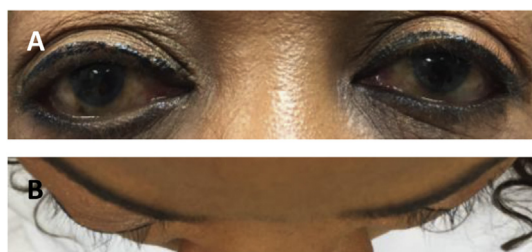
E-mail address: [wbyrd1@lsuhsc.edu](mailto:wbyrd1@lsuhsc.edu) (W.A. Byrd).

<https://doi.org/10.1016/j.ajoc.2018.09.010>

Received 12 March 2018; Received in revised form 26 July 2018; Accepted 28 September 2018

Available online 01 October 2018

2451-9936/© 2018 Published by Elsevier Inc. This is an open access article under the CC BY-NC-ND license (<http://creativecommons.org/licenses/by-nc-nd/4.0/>).



**Fig. 1. Ocular photos.** (A) Frontal and (B) overhead photos, taken at initial presentation, demonstrating 4 mm right eye proptosis.

neurological disease.

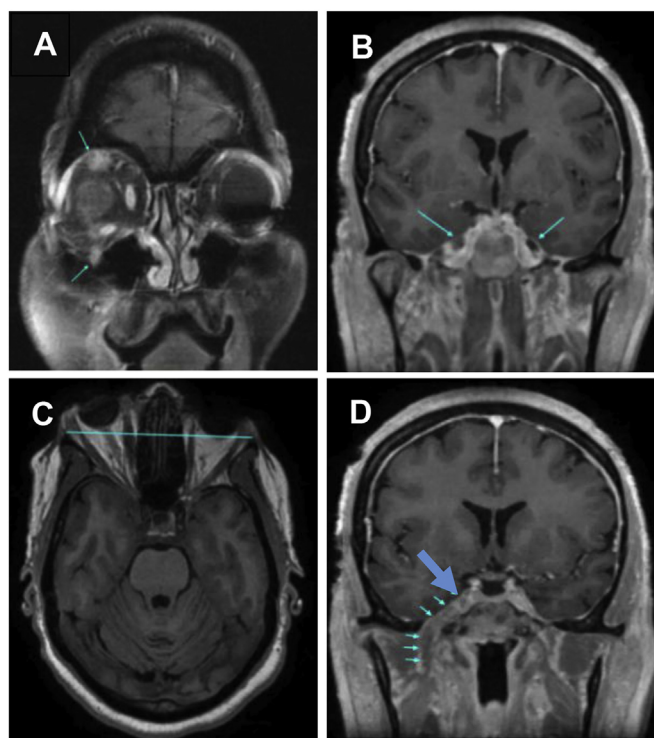
On physical examination, her pupils were equally round and reactive to light, extraocular muscles were intact, and the dilated fundus exam was normal. The right eye was actively tearing (Fig. 1A) and visibly proptotic (Fig. 1B). Hertel exophthalmometer measurement of the right eye showed a 25 mm proptosis compared to a 21 mm proptosis of the left eye. The patient had a mild right eye ptosis with dermatochalasis that was more pronounced in appearance due to the proptosis of the other eye. Right eyelid closure weakness was noted. There were no other neurological abnormalities. The remainder of the physical exam was within normal limits.

Screening tests for diabetes and thyroid disease were within normal limits and HIV testing was negative. MRI of the orbit, face, and neck with and without contrast performed a month after presentation showed enlargement and enhancement of the trigeminal nerve in the right cavernous sinus continuing through the right superior orbital fissure, foramen rotundum, and foramen ovale (Fig. 2). The right eye proptosis appeared to be due to the thickened nerve pushing forward on the orbit. A 17 × 16 mm, well-circumscribed, solid and cystic mass arising from the V2 division of the trigeminal nerve was situated in the right pterygopalatine space. A nasal endoscopy performed 2 months after initial presentation showed a left mid-septal deviation/spur, but was otherwise a normal nasopharynx.

A right frontotemporal craniotomy was performed 5 months post-presentation for biopsy and de-bulking of the known right pterygopalatine mass. Dissection of the extradural middle fossa revealed the 2nd and 3rd divisions of the trigeminal nerve. A mass was detected that extended through the foramen rotundum into the pterygopalatine fossa. The mass was dissected away from the middle fossa, the foramen rotundum was enlarged, and the tumor was dissected and removed along the distribution of V2 through the foramen rotundum and in the pterygopalatine fossa. Multiple excised fragments of soft tan colored tissue were submitted for complete pathological analysis. Analysis of an intraoperative frozen section yielded a preliminary diagnosis of spindle cell neoplasm consistent with schwannoma. The patient tolerated the procedure well with no intra- or post-operative complications.

Sections of the resected tissue fragments were of myelinated nerve and ganglion tissue (Fig. 3A). Microscopic evaluation revealed fibrotic endoneurium containing copious amounts of dense collagen. Myxoid debris and collagen were found in varying amounts scattered throughout the stroma. Examination of the endoneurium showed proliferation of S-100 positive (Fig. 3B) and neurofilament positive axons (Fig. 3C), CD34 (tumor antigen) negative (not shown), and narrow spindle cells with wavy nuclei consistent with the appearance of Schwann cells.<sup>7,8</sup> The Schwann cells were arranged both haphazardly in the endoneurium and in concentric rings, i.e., onion bulb formations, of varying sizes around axons (Fig. 3A).

The patient's headaches resolved following surgery in July 2015, but a feeling of right-sided eye pressure remained. The patient continued to have a measurable proptosis of the right eye, but no visual complaints. Her 1-year follow-up MRI showed a decrease in lesion size in comparison to the preoperative MRI consistent with the tumor de-bulking procedure. Unfortunately, there was not a significant resolution



**Fig. 2. MRI scans at one month post presentation.** (A) Post contrast coronal T1 with fat saturation. The upper blue arrow demonstrates the enlarged ophthalmic nerve (V1) and the lower blue arrow shows the enlarged maxillary nerve (V2) as they exit the orbit. (B) Post contrast coronal T1 with fat saturation. The blue arrows point to bilateral Meckel's cave. The right Meckel's cave (large blue arrow) enhances with contrast and is larger than the left Meckel's cave, which is normal and does not enhance with contrast. (C) Axial T1W. The blue line represents the interzygomatic line and demonstrates the proptosis of the right eye. (D) Post contrast coronal T1 weighted images with fat saturation. The bottom five small arrows demonstrate the abnormally thickened and contrast enhancing mandibular nerve V3 as it exits through the foramen ovale. The top large blue arrow points to the two upper branches of the trigeminal nerve, V1 and V2. (For interpretation of the references to color in this figure legend, the reader is referred to the Web version of this article.)

of her trigeminal neuralgia symptoms. However, she reports having learned to avoid many of her known triggers and is satisfied with her course of treatment thus far. Based upon her persistent symptoms of trigeminal neuralgia, a neurology consult was requested to evaluation her for therapy to gain further symptomatic relief.

A review of the clinical presentation, diagnosis, treatment and clinical outcomes of the reported<sup>2,3,6</sup> and current trigeminal HIN cases (Table 1) revealed a diverse demographics that includes a 41 year-old Native American male, a 61 year-old Hispanic female, and a 57 year-old African-American female. Notably, all cases presented with a > 3 year past medical history of unilateral facial neuralgia and pain. Two cases presented with 4–5 year history of orbital symptoms; unilateral ptosis with diplopia or unilateral proptosis, ptosis, and tearing. The results of neuroimaging studies (CT and MRI) supported a preliminary diagnosis of hypertrophic neuropathy involving the trigeminal nerve. All cases were confirmed as trigeminal HIN by the detection of Schwann cell “onion bulb” formations in the pathology sections of the resected hypertrophic trigeminal nerve tissue. Symptoms persisted in 2 cases post surgery, while one died from surgical complications.

### 3. Discussion

Similarities were noted regarding the clinical course, neuroimaging, and pathologic findings in the cases of HIN of the trigeminal nerve.

Download English Version:

<https://daneshyari.com/en/article/11033564>

Download Persian Version:

<https://daneshyari.com/article/11033564>

[Daneshyari.com](https://daneshyari.com)