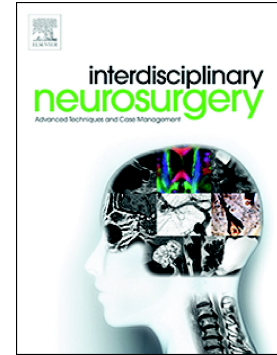


## Accepted Manuscript

Delayed diagnosis of a fractured anterior arch of the atlas in a child

Catherine Peterson, Richard J. Garling, Emre Yilmaz, Abilash Haridas, R. Shane Tubbs, Marc Moisi



PII: S2214-7519(18)30193-2  
DOI: doi:[10.1016/j.inat.2018.09.002](https://doi.org/10.1016/j.inat.2018.09.002)  
Reference: INAT 365

To appear in: *Interdisciplinary Neurosurgery: Advanced Techniques and Case Management*

Received date: 30 August 2018  
Revised date: 7 September 2018  
Accepted date: 15 September 2018

Please cite this article as: Catherine Peterson, Richard J. Garling, Emre Yilmaz, Abilash Haridas, R. Shane Tubbs, Marc Moisi, Delayed diagnosis of a fractured anterior arch of the atlas in a child. *Inat* (2018), doi:[10.1016/j.inat.2018.09.002](https://doi.org/10.1016/j.inat.2018.09.002)

This is a PDF file of an unedited manuscript that has been accepted for publication. As a service to our customers we are providing this early version of the manuscript. The manuscript will undergo copyediting, typesetting, and review of the resulting proof before it is published in its final form. Please note that during the production process errors may be discovered which could affect the content, and all legal disclaimers that apply to the journal pertain.

**Delayed Diagnosis of a Fractured Anterior Arch of the Atlas in a Child**

Catherine Peterson MD<sup>1</sup>, Richard J Garling MD<sup>1</sup>, Emre Yilmaz MD<sup>2</sup>, Abilash Haridas MD<sup>3</sup>, R

Shane Tubbs PhD<sup>2</sup>, Marc Moisi MD<sup>1</sup>

<sup>1</sup>Department of Neurosurgery, Wayne State University, 4201 St. Antoine St., 6E, Detroit, MI  
48201, USA

<sup>2</sup>Swedish Neuroscience Institute, Swedish Medical Center, 550 17<sup>th</sup> Ave, Seattle, WA 98122,  
USA

<sup>3</sup>Department of Pediatric Neurosurgery, St Joseph's Children's Hospital, 3001 W MLK Jr Blvd,  
Tampa, FL 33607, USA

**Email addresses:**

Catherine Peterson: catherine.peterson@wayne.edu; Richard J Garling:  
jgarling@med.wayne.edu; Emre Yilmaz: emre.yilmaz@gmx.de; Abilash Haridas:  
abilash.haridas@baycare.org; R Shane Tubbs: shanet@seattle-science-foundation.org; Marc  
Moisi: mmoisi@wayne.edu

**Corresponding Author:** Dr. Catherine Peterson, MD

Department of Neurosurgery, Wayne State University, 4201 St. Antoine St. 6E, Detroit, MI  
48201, USA

Email: catherine.peterson@wayne.edu / Phone: (313) 745-4767 / Fax (313) 745-4099

**Abbreviations list:** C-1, cervical 1; CT, computed tomography; MRI, magnetic resonance  
imaging; STIR, short T1 inversion recovery

**Declarations of interest:** None.

Download English Version:

<https://daneshyari.com/en/article/11033671>

Download Persian Version:

<https://daneshyari.com/article/11033671>

[Daneshyari.com](https://daneshyari.com)