

available at www.sciencedirect.comjournal homepage: <http://www.rpor.eu/>

Original article

Primary mucosal sinonasal melanoma—Case report and review of the literature. The role of complex treatment-surgery and adjuvant radiotherapy

Lena Marinova^a, Kaloyan Yordanov^{a,*}, Nikolay Sapundgiev^b

^a Radiotherapy Department, Oncology Hospital, Medical University – Varna, Varna, Bulgaria

^b Oto-rhyno-laryngology Department, University Hospital “Sveta Marina”, Medical University – Varna, Varna, Bulgaria

ARTICLE INFO

Article history:

Received 1 September 2010

Accepted 15 November 2010

Keywords:

Sinonasal melanoma

Complex treatment

Mucosal melanoma

Surgery

Radiotherapy

ABSTRACT

Aim: The place of adjuvant radiotherapy in the treatment of sinonasal melanoma.

Background: Sinonasal mucosal melanoma is a rare disease with poor prognosis and requires a complex treatment. Elective neck dissection in patients with N0 and adjuvant radiotherapy has been a source of controversy. High late regional recurrence rates rise questions about elective irradiation of the neck nodes in patients with N0 stage disease.

Methods: We present our two years' follow up in a case of locally advanced sinonasal melanoma and literature review of the treatment options for mucosal melanoma.

Results: In locally advanced sinonasal melanoma treated with surgical resection, postoperative radiotherapy and chemotherapy we had local tumor control. Two years later, a regional contralateral recurrence without distant metastasis occurred.

Conclusions: Literature data for frequent neck lymph nodes recurrences justify elective neck dissection. Postoperative elective neck radiotherapy for patients with locally advanced sinonasal melanoma and clinically N0 appears to decrease the rate of late regional recurrences.

© 2010 Greater Poland Cancer Centre, Poland. Published by Elsevier Urban & Partner Sp. z.o.o. All rights reserved.

1. Introduction

Malignant melanoma affecting the nasal cavity and paranasal sinuses is a rare disease^{1–5} with a poor prognosis.^{3,12–16} Optimal complex treatment and the role of adjuvant radiotherapy for sinonasal melanoma remains an open issue.¹³

2. Case reports

A 65-years-old male with locally advanced paranasal malignant melanoma. According to Tanaka et al. the types of melanoma are histologically subdivided into nonpigmented

mixed type.^{17,18} Immunohistochemistry – the tumor cells strongly expressed S-100 protein and HMB-45 monoclonal antibody microstaging as described by Prasad et al. Level III, deep invasion into surrounding tissue.^{2,3,9,10}

CT scan-head and neck – tumor, involving right nasal cavity, right paranasal sinuses-maxillary, ethmoidal, frontal and retrobulbar space. There is no evidence for positive cervical lymph nodes (Fig. 1). The stage was defined according to the Union International Centre le Cancer stage I (confined to the primary site without positive cervical lymph nodes).⁹

Surgery – a mediofascial resection with positive excision margins R₂ was done. Postoperative CT scan demonstrates residual tumor in all paranasal sinuses (Fig. 2).

* Corresponding author at: Radiotherapy Department, Medical University – Varna, 100 Tsar Osvoboditel Str., Varna, Bulgaria.

E-mail address: koko.yord@abv.bg (K. Yordanov).

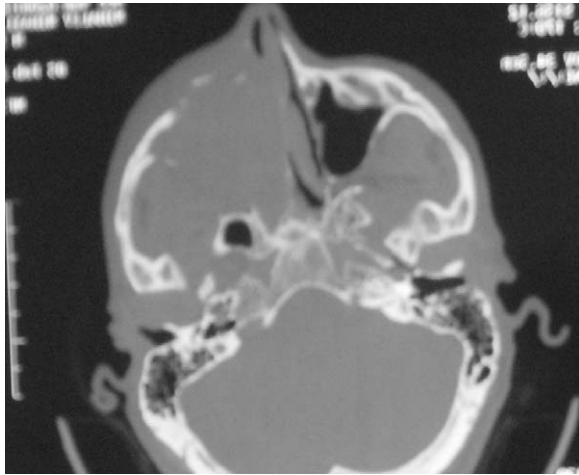


Fig. 1 – Preoperative CT scan – locally advanced sinonasal melanoma.

CT scans of the brain, thorax and abdomen were negative. Bone scan showed no metastases. Postoperative external beam radiation therapy to total dose of 70 Gy was performed. Conventional radiotherapy was prescribed. CTV covered also the right eye and retrobulbar space, due to tumor infiltration. CT scan (one month after radiotherapy) – tumor reduction around 80%, tumor size – 15–20 mm, localized in the right frontal and ethmoidal sinuses (Fig. 3).

Five cycles of chemotherapy with Vinblastin – 1.2 mg/m for 1–4 days, Cisplatin – 25–50 mg/m for 1–4 days, DTIC – 800 mg/m for 1 day were applied. MRI imaging after the fourth cycle showed poor response to systemic treatment (Fig. 4).

Second surgical excision was performed. Surgical margins were macroscopic and microscopic clear – R₀. MRI imaging six months after the re-surgery showed no evidence of disease – local tumor control (Fig. 5).

Two years after the treatment, PET/CT was performed. The results revealed metastatic contralateral neck lymph nodes (25–27 mm). Selective left neck dissection was done. Pathologic examination showed lymph nodes with metastases from malignant melanoma with pigmentation.

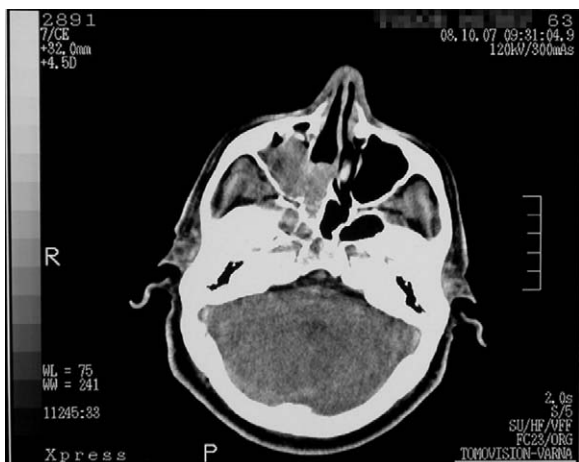

Fig. 2 – Postoperative CT scan – residual tumor.

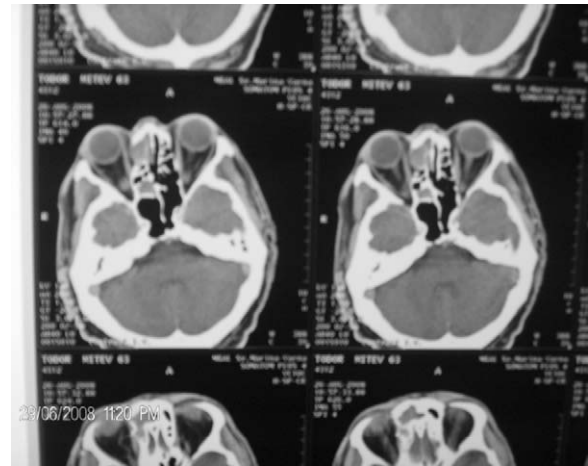


Fig. 3 – CT scan – one month after postoperative radiotherapy – residual tumor.

3. Discussion

Our observations rise a number of questions: (1) What is the optimal complex treatment according to local tumor control and disease free survival? (2) What is the benefit from adjuvant radiotherapy in locally advanced sinonasal melanoma? (3) What is the role of elective neck irradiation (in patients with N0 disease)?

At the time of diagnosis, sinonasal melanoma is often locally advanced⁵ with all paranasal sinuses affected, including retrobulbar infiltration (our case). Treatment of choice for mucosal melanoma is radical surgical excision with clear margins.^{1,14–16} This is possible for early stage melanomas, without infiltration in adjacent structures. The literature data for incidence of lymph node metastases is controversial – rare (below 6%)¹⁶ or frequent.⁸ Metastatic neck lymph nodes worsen the prognosis and require neck dissection.^{17,18} It is curative only for 30% of cases, because the others already have occult distant metastases.¹⁹

Despite high rates of local and regional recurrences in patients with N0, elective neck dissection is still controversial.⁵ It seems that the dissection is beneficial in selective group of patients – with deep infiltration and high risk of occult lymph node metastases.^{16,19} Elective neck dissection will probably improve the rates of local neck metastases and disease free survival.

In our case we have a contralateral late regional recurrence two years after treatment, without local relapse and distant metastases. According to McMasters et al., in the neck region, drainage patterns vary and tend to be a higher number of sentinel lymph nodes.²¹ Lymph drainage is unpredictable and it is mandatory to perform preoperative lymphoscintigraphy.^{5,22} If interval sentinel lymph nodes are negative, there is no place for lymphadenectomy. In stage 3 disease (without palpable neck nodes), we should suggest elective neck dissection.⁵

Postoperative radiotherapy in patients with R₁–R₂ resection is indicated, although melanoma has always been considered as a radioresistant tumor.^{14,23–25} Irradiation is more often used in the sinonasal melanoma because of the difficulty in obtaining satisfactory clear surgical margins in this region.⁸ We

Download English Version:

<https://daneshyari.com/en/article/1857136>

Download Persian Version:

<https://daneshyari.com/article/1857136>

[Daneshyari.com](https://daneshyari.com)