



Short communication

Combination therapy of gamma-aminobutyric acid derivative promotes proton pump inhibitor based healing of reflux esophagitis in animal model

Pradeep Khinchi, Sudipta Saha, Shubhini A. Saraf, Gaurav Kaithwas *

Department of Pharmaceutical Sciences, Babasaheb Bhimrao Ambedkar University (A Central University), Lucknow, India

ARTICLE INFO

Article history:

Received 15 November 2012
 Received in revised form 14 June 2013
 Accepted 25 June 2013
 Available online 1 February 2014

Keywords:

Antisecretory
 Baclofen
 Esophagitis
 Gamma-aminobutyric acid
 Omeprazole

ABSTRACT

Background: The present study was undertaken to elucidate the effect of omeprazole and baclofen on experimental esophagitis in albino rats.

Methods: Groups of rats, fasted overnight received normal saline (3 ml/kg, *ip*; sham control) or toxic control (3 ml/kg, *ip*) or omeprazole (30 mg/kg, *ip*) or baclofen (20 mg/kg, *ip*) or their combinations, were subjected to the pylorus and forestomach ligation.

Animals were sacrificed after 6 h and evaluated for the gastric pH, volume of gastric juices, total acidity, esophagitis index and free acidity. Esophageal tissues were further subjected to estimations of TBARS, GSH, catalase and SOD.

Results: Treatment with omeprazole and baclofen significantly inhibited the gastric secretion, total acidity and esophagitis index. The treatment also helped to restore the altered level's oxidative stress parameters to normal.

Conclusion: The beneficial effect of omeprazole and baclofen against GERD could be conglomerately attributed to the antisecretory action of omeprazole and reduction in the tracheal lower esophageal sphincter release rate by baclofen.

© 2014 Institute of Pharmacology, Polish Academy of Sciences. Published by Elsevier Urban & Partner Sp. z o.o. All rights reserved.

Introduction

Gastroesophageal reflux disease (GERD)/gastric reflux disease or acid reflux disease is apparently the most frequently occurring functional foregut disorder and accounts for approximately 75% of esophageal pathology in the industrial countries. GERD is the most common outpatient gastroenterological diagnosis in the USA, with a prevalence rate of 10–20% and an annual incidence of 0.38–0.45% in the western world [1]. GERD significantly reduces health-related quality of life and intrude a marked economic dead weight on the healthcare system [19]. Recent investigations have reported that the mucosal damage in GERD is due to several causative agents in the refluxate [12] that stimulate mucosal and sub-mucosal cells to release mediators, eliciting an inflammatory reaction and leading to visceral hypersensitivity and other symptoms of GERD. Inflammatory process seems to play a key role in the underlying mechanisms of the symptoms and pathogenesis of other gastrointestinal

conditions as well, such as functional dyspepsia and irritable bowel syndrome [2].

Omeprazole is a proton pump inhibitor (PPI) used in the treatment of dyspepsia, peptic ulcer disease, gastroesophageal reflux disease, laryngopharyngeal reflux and Zollinger–Ellison syndrome. It is most acknowledged antisecretory agent in terms of symptomatic relief and mucosal healing in GERD [6]. Baclofen is a derivative of gamma-aminobutyric acid (GABA) and a recent study has divulged that baclofen reduces the tracheal lower esophageal sphincter release rate (TLESR) by 40–60% and reflux episode up to 48% (by increasing esophageal sphincter basal pressure and accelerating gastric emptying) [7,9]. The recidivating nature of GERD requires long term maintenance therapy and none of the currently available medications provides long term cure [15]. Tiberiu and Fass [19] in their report has estimated that 10–40% of patients with GERD fail to reciprocate symptomatically, either partially or completely, to a standard dose of PPI. About 90% of PPI treated GERD patient are partially or completely unresponsive to standard dose/duration of PPI therapy, for such patients either increased dose/duration of the same therapy or using amalgamation therapies can provide more symptomatic relief for long duration [5,11]. In view of above, the present study was ventured to inquest the effect of monotherapy and combination therapy of baclofen and omeprazole on experimentally induced esophageal lesions in animal model.

Abbreviations: GERD, gastroesophageal reflux disease; GSH, glutathione; PPI, proton pump inhibitor; TBARS, thiobarbituric acid reactive substances; TLESR, tracheal lower esophageal sphincter release rate; SOD, superoxide dismutase.

* Corresponding author.

E-mail address: gauravpharm@gmail.com (G. Kaithwas).

Materials and methods

Drugs and chemicals

Baclofen and omeprazole were procured from Sun Pharma Ltd., Mumbai, Maharashtra, India and Dr. Reddys Laboratories Ltd., Hyderabad, Andhra Pradesh, India respectively. All other chemicals were purchased from S.D. Fine Chemicals, Mumbai, India.

Animals

Wistar strain albino rats (175–200 g) were obtained from Indian Veterinary Research Institute, Izatnagar, Bareilly (UP). Animals were housed under standard conditions of temperature ($25 \pm 1^\circ\text{C}$) with 12 h light/dark cycle and had a free access to commercial pellet diet and water ad libitum. The animals were given a week's time to get acclimatized with the laboratory condition, before experimentation. The study was approved by the Institutional Animal Ethics Committee (Ref: 43/1279/ac/SU/IAEC/2012).

Induction of esophagitis

Animals were randomized and divided into five groups of six animals each. Groups of rats, fasted overnight received normal saline (3 ml/kg, *ip*; sham control) or toxic control (3 ml/kg, *ip*) (forestomach and pylorus ligated) or omeprazole (30 mg/kg, *ip*) or baclofen (20 mg/kg, *ip*) or their combinations. After 1 h, coeliotomy was performed and esophagitis was induced by ligating the forestomach and pylorus with 2–0 silk suture under pentobarbitalone (50 mg/kg, *ip*) anesthesia. After 6 h, animals were sacrificed by cervical dislocation and the chest was opened with a median incision, the tissue esophagus and stomach were removed. The stomach was opened along the greater curvature, and the esophagus was dissected out by extending the dissection line along the major axis. The tissue was washed with normal saline and examined for lesions. The severity of the erosions was scored and the index was calculated by dividing the total score by ten, which was designated as esophagitis index [14].

Erosion (mm)	Score
1 or less	1
1–2	2
>2	3

The volume of gastric juice, total acidity and pH were measured as described subsequently under “gastric secretion in pylorus ligated rats” [8].

Estimation of free radical generation

Esophageal tissue was minced well, homogenized in ice-cold 0.01 M Tris–HCl buffer, pH 7.4 and subjected to the estimations of thiobarbituric acid reactive substances (TBARS) [10], tissue glutathione (GSH) [16], catalase [3] and superoxide dismutase (SOD) [1].

Statistical analysis

All data were presented as mean \pm SD and analyzed by one way ANOVA followed by Student–Newmans–Keuls test for the possible significance identification between the various groups. Statistical significance was compared to control [(a) $p < 0.05$, (b) $p < 0.01$, (c) $p < 0.001$] and toxic control [(x) $p < 0.05$, (y) $p < 0.01$, (z) $p < 0.001$]. Statistical analysis was carried out using Graph Pad Prism 3.0 (Graph Pad Software, San Diego, CA).

Results

Ligating the forestomach and pylorus augmented reflux esophagitis in all the animals marked by macroscopically visible necrosis and cogent ulceration in the esophagus. Treatment with monotherapy of omeprazole and baclofen significantly constrained the lesion formation in esophagus. Omeprazole significantly inhibited the esophagitis index (1.24 ± 0.14) in comparison with toxic control (4.32 ± 0.24) (Fig. 1). The unification therapy of omeprazole and baclofen produced 74.31% inhibition of esophagitis index respectively. The combination of omeprazole and baclofen, inhibited the esophagitis index, decreased the volume of gastric juices, total acidity and increased the gastric pH to a sentientious level, suggesting the possible synergistic effect (Fig. 2). There was a momentous increase in the TBARS generation (7.44 ± 0.48 nmol of MDA/mg of protein) in toxic control in collation to normal control (0.92 ± 0.18 nmol of MDA/mg of protein) indicating reactive oxygen species (ROS) generation and oxidative stress. Our results suggest that the reflux esophagitis produces free radical species that attack lipid components, leading to lipid peroxidation. Concomitant administration of the omeprazole and baclofen as a monotherapy significantly repressed the lipid peroxidation manifested by decreased TBARS levels, i.e. 3.21 ± 0.30 , 3.25 ± 0.27 and 4.92 ± 0.50 respectively.

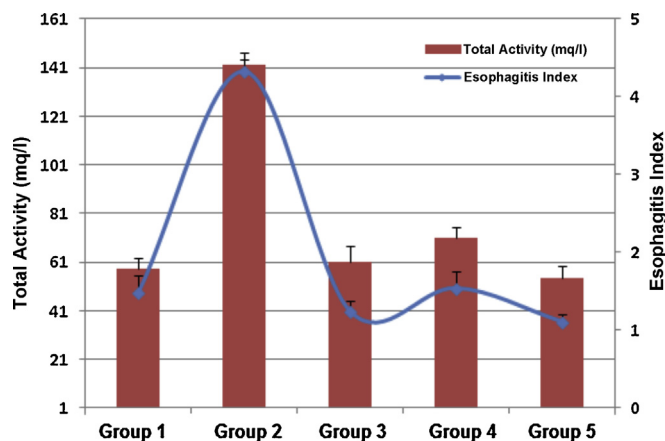


Fig. 1. Effect of omeprazole and baclofen on total acidity and esophagitis index in experimental animals subjected to pylorus and forestomach ligation (please refer Table 1 for treatment schedule of a particular group) (values are mean \pm SD), each group contains 6 animals.

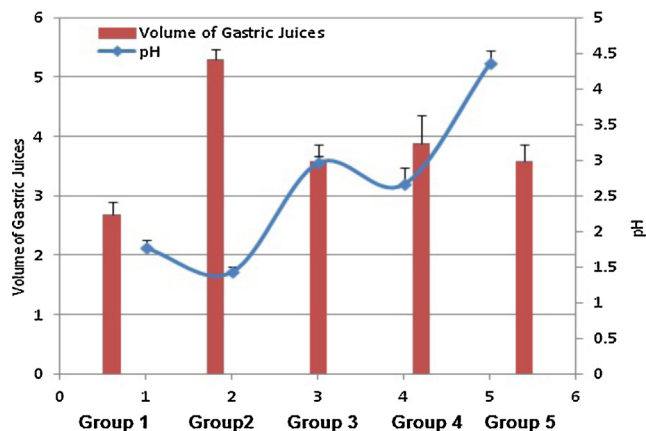


Fig. 2. Effect of omeprazole and baclofen on volume of gastric juices and pH in experimental animals subjected to pylorus and forestomach ligation (please refer Table 1 for treatment schedule of a particular group) (values are mean \pm SD), each group contains 6 animals.

Download English Version:

<https://daneshyari.com/en/article/2010635>

Download Persian Version:

<https://daneshyari.com/article/2010635>

[Daneshyari.com](https://daneshyari.com)