



Case Report

Enzyme replacement therapy in Hurler syndrome after failure of hematopoietic transplant

Leonor Arranz^{a,b,*}, Luis Aldamiz-Echevarria^{b,c}^a Pediatrics Department, Donostia University Hospital, San Sebastian, Spain^b Pediatrics Department, Faculty of Medicine, Basque Country University (UPV/EHU), San Sebastian, Spain^c Metabolism Unit, Cruces University Hospital, Bilbao, Spain

ARTICLE INFO

Article history:

Received 2 March 2015

Received in revised form 22 April 2015

Accepted 23 April 2015

Keywords:

Hurler syndrome

Enzyme replacement therapy

Hematopoietic transplant

Mucopolysaccharidosis type I

Laronidase

Anti-laronidase antibodies

ABSTRACT

The most severe form of Mucopolysaccharidosis type I (MPS-I), Hurler syndrome, presents with progressive respiratory, cardiac and musculoskeletal symptoms and cognitive deterioration.

Treatment includes enzyme replacement therapy (ERT) and/or hematopoietic stem cell transplantation (HSCT). We describe the case of an 8-year old boy with MPS-I, homozygous for W402X, treated at 10 months of age with HSCT and after failure of the transplant, with ERT during 2 years showing good results, including a positive neuropsychological development.

© 2015 Published by Elsevier Inc. This is an open access article under the CC BY-NC-ND license (<http://creativecommons.org/licenses/by-nc-nd/4.0/>).

1. Introduction

Mucopolysaccharidosis type I (MPS-I) is a rare, hereditary autosomal recessive disease due to a deficiency of α -L-iduronidase (IDUA), which is required for degradation of glycosaminoglycans (GAGs), resulting, thus, in their lysosomal accumulation and their increased urinary excretion [1,2].

MPS-I shows great phenotypic variability, depending on existing enzymatic activity. Out of the 110 mutations described in the IDUA gene [3], W402X and Q70X result in an inactive truncated protein, which causes early onset of the disease and death [4]. This phenotype corresponds to the most severe form of the disease or Hurler syndrome, which is characterized by multisystemic clinical manifestations, including growth delay, hepatosplenomegaly, skeletal deformities, increase in urinary GAGs, cornea opacity, respiratory disease, cardiac symptoms,

hydrocephaly and cognitive disorder, which progress since the first year of life and lead to death within that year in untreated patients.

Hematopoietic stem cell transplantation (HSCT) has been used to treat MPS-I, resulting in a slower evolution of the disease and improved overall survival [5–7].

In 2003, laronidase, recombinant human α -L-iduronidase (Aldurazyme®), was authorized as ERT for MPS-I treatment, administered in weekly infusions [8]. This treatment reduces the abnormal accumulation of GAGs in different tissues, decreasing their urinary excretion [9]. However, IV ERT cannot cross the blood–brain barrier in an amount equivalent to the recommended dose (100 IU/kg/week) [10]; thus, it is not efficient to prevent cognitive impairment.

The association of ERT and HSCT has provided the best benefit/risk ratio for these patients [11–14].

We report the case of an 8-year old boy suffering from Hurler syndrome, treated at 10 months of age with HSCT and 4 years later with ERT during a period of 2 years and 4 months.

2. Case report

The patient is a boy of 7 years and 11 months of age, diagnosed with MPS-I, Hurler syndrome, at 4 months, presenting with coarse facies, and with severe kyphosis, due to vertebral malformation at L2. Genetic analysis reported the homozygous mutation W402X.

At 10 months, he was treated with HSCT from cord blood from an HLA-identical match (6/6) unrelated donor. Four months prior to

Abbreviations: ERT, Enzyme replacement therapy; FEV0.5, forced expiratory volume in 0.5 s; FVC, forced vital capacity; GAGs, glycosaminoglycans; HSCT, hematopoietic stem cell transplantation; IV, intravenous; MMEF, maximum midexpiratory flow; MPS-I, mucopolysaccharidosis type I; MRI, magnetic Resonance Imaging; MSCA, McCarthy Scales of Children's Abilities; 6MWT, 6-minute walk test; ORL, otorhinolaryngology; OSAHS, Obstructive Sleep Apnea–Hypopnea Syndrome; TMT (A), Trail Making Test Part A; WISC-IV, Wechsler Intelligence Scale for Children – IV; X-ray, radiograph.

* Corresponding author at: Pediatrics Unit, Donostia University Hospital, San Sebastian, Spain.

E-mail address: leonor.arranz.arana@osakidetza.net (L. Arranz).

transplant, the child started ERT with laronidase 100 IU/kg/week up to six months after the transplant, with good tolerability. The initial evolution was satisfactory. However, after 4 years from the transplant, the patient developed important mixed chimerism (85%) and low enzymatic activity (2%). Later on, an analysis showed a mixed chimerism of 10%. No suitable donor for a second transplant was located; thus, ERT was again reinitiated. Up to date, the patient has received treatment for 110 weeks with excellent tolerability, good clinical response and no secondary reactions.

Anti-laronidase antibodies (IgG) were initially negative but became positive and progressively higher, reaching a maximum titer of 25,600 at week 28, and then decreasing down to 800 at week 110 (Fig. 1). The appearance of antibodies had no clinical manifestation.

Serial controls of urinary GAGs were performed every 4 and 6 months during the first and second year, respectively, showing always levels below 50 mg/mmol creatinine, which reached the lowest at weeks 28 and 110 from ERT initiation (Fig. 1).

Currently, the patient presents with overall good status, with a weight of 25.5 kg (P75), height of 111.5 cm (<P3; $-2.75SD$) and cephalic perimeter of 52 cm (P90). Cardiac and pulmonary auscultations were normal. Abdomen was prominent with umbilical hernia and no visceromegaly. Flexion and extension of the shoulders were moderately limited, as well as total extension of the elbows, knees and wrists. Bilateral Achilles retraction with normal arch support and bilateral *genu valgum* were observed. He could walk independently and on toes and heels, and walked 430 m in the 6-minute walk test (6MWT).

At neurological examination, slight symptoms of bilateral carpal tunnel syndrome were observed.

Bone X-ray showed multiple dysostosis. Ophthalmologic examination showed bilateral slight cornea opacity and convergent strabismus, which required correcting eyeglasses but ophthalmic MRI showed no alterations. MRI of the spine showed anterior vertebral wedging of L1 and L2, with posterior disk prominence and associated lumbar canal stenosis; and dorsal syringomyelia (D5–D8).

Along the patient's evolution, he presented clinical manifestations and respiratory polygraphy results compatible with severe Obstructive Sleep Apnea–Hypopnea Syndrome (OSAHS), which required surgical intervention (adenotonsillectomy). Currently, he presents with mild OSAHS.

Current respiratory parameters are: FVC: 0.95 L (79%), FEV 0.5: 0.87 L (85%), and MMEF 75/25: 1.21 L/s (84%).

The neuropsychological evaluation performed by using the McCarthy Scales of Children's Abilities (MSCA) [15], in March 2012 and September 2014, plus the Wechsler Intelligence Scale for Children–IV (WISC–IV)

[16], subtest symbol search, and the Trail Making Test [17] Part A [TMT (A)] in September 2014 showed an adequate evolution, despite a mild distance with respect to children of his age in relation to attention problems and motor difficulties. The neuropsychological evolution was positive and overall maturity was observed, as compared with the previous assessment (Fig. 2).

Overall, neuropsychological development was within low normality for his chronological age; there was a mild delay regarding cognitive development but the child was in the school grade corresponding to his age with extra-scholar support.

3. Discussion

After failure of HTSC, the patient was treated with ERT for two years. Initially, anti-laronidase IgG antibody determination was negative but the patient seroconverted showing the highest antibody titer at week 28 from treatment initiation, and decreasing thereafter down to the 110th infusion. These data agree with those of previous published studies showing that the great majority of patients developing antibodies during the first months of treatment evolve towards tolerability phenomena with IgG reduction at two years of treatment [18,19].

The study of the evolution of urinary GAGs showed a pattern, which followed, with a delay, that of the antibodies. This parallel pattern disagrees with previous results showing that ERT causes a decrease in GAGs levels, which is maintained independently from antibody levels [20].

It seems that ERT treatment has prevented the appearance of visceromegaly, cardiac, neurologic and ophthalmologic involvement, and progression of bone dysplasia and phenotype. No significant modifications were appreciated in respiratory function; and after the tonsillectomy, the previous severe OSAHS became mild. Another important fact is that the patient has not developed infections, neither renal complications nor thrombotic events, as it has been described in the literature [21,22].

The distance walked in the 6MWT test (430 m) was lower than the lower limit of the median range corresponding to children of his age according to Geiger [584 m (455.0–692.0)] [23].

There was no significant neurocognitive impairment. Since the enzyme does not cross the blood–brain barrier in significant amounts, an explanation might be that the overall maintenance of the quality of life of the child has positively influenced on the neuropsychological evolution.

After the transplant, the patient behaved as if he had a mild form of the disease, showing clinical manifestations similar to the patients described by Kakkis et al. [9].

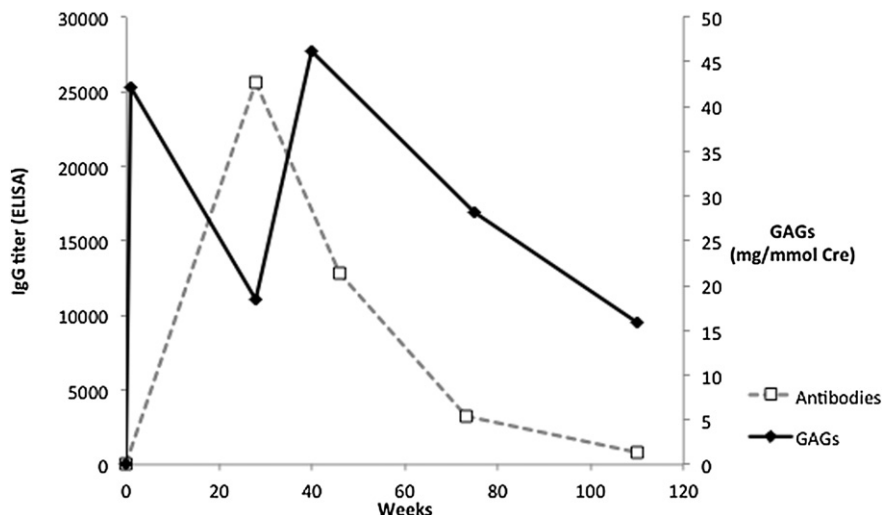


Fig. 1. GAGs (mg/mmol Cre) and anti-laronidase antibodies (IgG titer) evolution during 110 weeks of enzyme replacement therapy.

Download English Version:

<https://daneshyari.com/en/article/2058805>

Download Persian Version:

<https://daneshyari.com/article/2058805>

[Daneshyari.com](https://daneshyari.com)