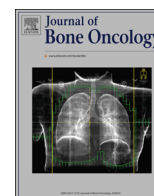



ELSEVIER

Contents lists available at ScienceDirect

## Journal of Bone Oncology

journal homepage: [www.elsevier.com/locate/jbo](http://www.elsevier.com/locate/jbo)

## Case Report

## Two cases with fatal outcome following total lung irradiation for metastatic bone sarcoma

K. Lia <sup>a,\*</sup>, Ø.S. Bruland <sup>a,b</sup>, H.L. Randem <sup>c</sup>, L.H. Aksnes <sup>a</sup>, J.P. Poulsen <sup>a</sup>, I. Taksdal <sup>d</sup>, K. Sundby Hall <sup>a</sup><sup>a</sup> Department of Oncology, Norwegian Radium Hospital, Oslo University Hospital, P.O. Box 4953, Nydalen, 0424 Oslo, Norway<sup>b</sup> Institute of Clinical Medicine, University of Oslo, 0310 Oslo, Norway<sup>c</sup> Department of Medical Physics, Norwegian Radium Hospital, Oslo University Hospital, P.O. Box 4953, Nydalen, 0424 Oslo, Norway<sup>d</sup> Department of Radiology, Norwegian Radium Hospital, Oslo University Hospital, P.O. Box 4953, Nydalen, 0424 Oslo, Norway

## ARTICLE INFO

## Article history:

Received 10 July 2013

Received in revised form

19 September 2013

Accepted 27 September 2013

Available online 11 October 2013

## Keywords:

Osteosarcoma

Ewing's sarcoma

Pulmonary metastasis

Pulmonary irradiation

Lung toxicity

## ABSTRACT

We report a single institution experience with total lung irradiation in 53 metastatic bone sarcoma patients in the context of two young female patients who died from treatment-induced pulmonary toxicity. A radiation dose of 19.5 Gy in 1.5 Gy daily fractions was given as two opposing fields with a conventional technique. Both patients succumbed within 3 months following radiotherapy. One patient had osteosarcoma whereas the other advanced Ewing's sarcoma; both with widespread metastases to the lungs at primary diagnosis. In retrospect, most likely high dose methotrexate lung toxicity observed in the osteosarcoma patient, and the GI-toxicity following pelvic radiotherapy in Ewing's case, both observed during the initial phase of their multimodal treatment, might indicate an increased individual radiosensitivity.

In view of this, a review of our experience in 53 bone sarcoma patients (19 with Ewing's sarcoma and 34 with osteosarcoma) treated at our institution was conducted. We have not previously experienced significant toxicity following total lung irradiation. Among these, 42% (8/19) with Ewing's sarcoma and 9% (3/34) with osteosarcoma are long-term survivors and without clinically significant lung toxicity.

© 2013 Elsevier GmbH. This is an open access article under the CC BY-NC-ND license (<http://creativecommons.org/licenses/by-nc-nd/4.0/>).

## 1. Introduction

Two comprehensive reviews have addressed total lung irradiation (TLI) in patients with metastases from osteo- and Ewing's sarcoma [1,2]; a technique that has been used for decades and presented in textbooks [3,4]. Such radiotherapy involves parallel opposing anteroposterior/posterioranterior fields encompassing the apices and distal costo-phrenic sinuses of both thoracic cavities. The two lungs may be treated simultaneously or sequentially. Several non-randomized studies have been reported [5–7]. Bilateral lung irradiation might, theoretically, combat micrometastases within the lungs and subsequently prevent overt metastases to develop. We have not identified studies adequately addressing whether TLI might benefit patients with macroscopic metastases.

Radiation pneumonitis was first described in 1922 by Groover et al. [8]. To our knowledge, the literature lacks information about lethal toxicity following such treatment. The tolerance of the lungs to radiation depends on the volume treated, total dose and dose

per fraction [9,10]. Lung tissues poorly tolerate high-dose irradiation [11]. The fundamental problem with TLI is that pulmonary parenchymal tolerance to radiation is exceeded before sound tumoricidal doses are achieved [1]. During treatment planning, the general recommendation is to not exceed a total dose of 18–20 Gy in 1.5–2.0 Gy daily fractions administered over 2 weeks in order to respect lung tolerance [1]. For children and young adults under the age of 15 the standard total dose is 15 Gy.

Here we present two clinical cases demonstrating that even lethal lung toxicity may occur after TLI. A brief synopsis of the literature is also presented. We have also, retrospectively, reviewed our single institution experiences involving 53 bone sarcoma patients treated with TLI from 1980 to 2012.

## 2. Clinical material

## 2.1. Case 1

A female patient, 17 years of age, was admitted for pain in her left calf, and x-ray revealed a sclerotic lesion in the proximal tibia. Biopsy was performed and histology showed an osteoblastic osteosarcoma of high-grade malignancy. At the time of primary

\* Corresponding author. Tel.: +47 92229597.

E-mail address: [kjersti.lia@gmail.com](mailto:kjersti.lia@gmail.com) (K. Lia).

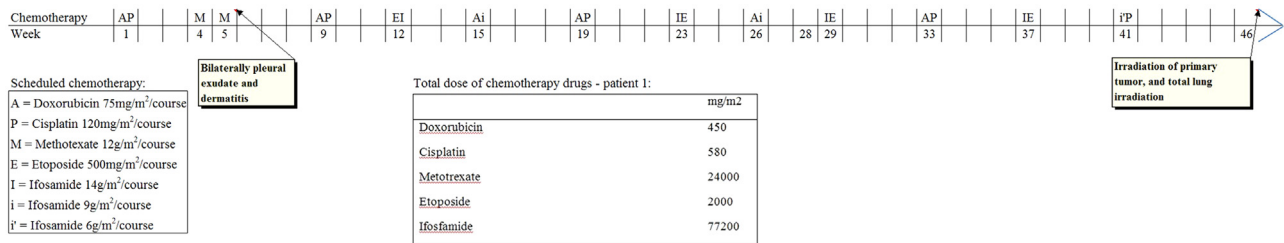


Fig. 1. Chemotherapy given to patient 1 – modified EURAMOS-1 regime.

diagnosis, CT scans of the lungs showed multiple and bilateral lung metastases; about 25 lesions in the right lung and 14 in the left. She had an allergic reaction with breathing-difficulties following intravenous contrast medium administration during the first CT scan.

**Chemotherapy:** The first cycle with doxorubicin/cisplatin and the subsequent high dose methotrexate (MTX) were given without complications. However, during the next high dose MTX cycle, she experienced right-sided thoracic pain at inspiration and bilateral pleural exudates, as well as skin rash. Pleural drainage was necessary to prevent serious atelectasis and MTX was eliminated normally as evaluated by serum measurements. During the following weeks the lung impairment continued. The next cycle of doxorubicin/cisplatin had to be postponed 3 weeks due to lung toxicity. Hence MTX was omitted from further treatment. She received a total of 13 chemotherapy cycles (Fig. 1) based on the schedule in the EURAMOS-1 protocol [12]. She developed neutropenic fever and thrombocytopenia after most cycles. At week 28, a new MRI and CT scan showed progression of her primary tumor as well as the lung metastases. However, her subjective lung function had improved.

**Radiotherapy:** Five weeks after the last chemotherapy cycle TLI was started. She received 1.5 Gy × 13 – total dose 19.5 Gy (5 fractions per week). She also had irradiation of her primary tumor in the left tibia, 2.0 Gy × 30 – total dose 60.0 Gy (5 fractions per week). To boost the dose from external radiotherapy she received the bone-seeking radiopharmaceutical <sup>153</sup>Sm-EDTMP [13–18]. This was based on bone-scintigraphy showing that her primary tumor displayed an avid phenotype. The approved dose of 1 mCi/kg used for pain palliation of osteoblastic skeletal metastases was infused intravenously. Only one dose was administered – given at day 2 of the TLI.

**Clinical course:** On day 11 she developed shortness of breath. CT revealed extensive ground-glass opacities, progressing to involve the entire lung parenchyma. Underlying infection was ruled out. She developed severe dyspnea diagnosed as radiation-induced lung pneumonitis, that progressed over two months following lung irradiation (Fig. 2). Despite ventilator support with high oxygen supply at an intensive care unit and high doses of solucortef, 100 mg three times a day, the situation did not improve. She died about 3 weeks later. Autopsy was not performed.

## 2.2. Case 2

The other patient, 18 year old female, presented with a 5 × 8 cm tumor located in the right ala ossis ilii, with infiltrating growth into the iliopsoas and gluteus minimus muscles. She had small metastases in both lungs; about 13 lesions in her right and seven in her left. Biopsy showed a typical Ewing's sarcoma that was confirmed by the presence of EWS-FL11 fusion transcript. She had a previous history of mild asthma symptoms, but without the need for medication. The intended treatment plan was ISG/SSG IV – an

Italian Sarcoma Group/Scandinavian Sarcoma Group Ewing's protocol [19].

**Chemotherapy:** She received seven cycles in total (Fig. 3). After six cycles without complications, she was operated with a pelvic resection. The pathological examination of the removed tumor showed a histologically necrotic tumor. A marginal tumor response was poor (grade I, Picci grading system) [20]. Postoperatively, she had pain in the right pelvis and leg. An abscess was diagnosed in relation to the operation cavity, successfully treated with drainage and antibiotics.

**Radiotherapy:** One month after surgery she had recovered and commenced iliac field radiotherapy including the tumor bed with 2 cm margins. Hyperfractionated radiotherapy was given, 1.5 Gy twice daily to a total dose of 40.5 Gy (of planned 42 Gy, 10 fractions per week), employing a three-field technique. Concomitant with radiotherapy the seventh cycle was given according to the protocol mentioned above (Fig. 3). Seven days after radiotherapy she became neutropenic and developed symptoms of ileus. Surgery was necessary and demonstrated a perforation most likely based on radiation induced changes in the small intestine. Repeated surgical interventions during the next months were necessary to stabilize the situation with abscesses; resulting in an ileostomy and weeks with intensive treatment. She had a severe and protracted postoperative course, necessitating 5 weeks with ventilator support. Due to the serious toxicity, further cytostatic treatment was omitted.

**Clinical course:** Nineteen weeks after the last surgery, her general condition had recovered. The lung metastases were not visible by chest CT at this point, but due to overt metastases at primary diagnosis, we decided to give TLI as consolidation treatment, 19.5 Gy (1.5 Gy × 13).

Two months after total lung irradiation she was admitted to the intensive care unit for pneumonia which progressed rapidly despite various antibiotics. She developed acute respiratory distress syndrome with typical ground-glass opacities and pleural effusions on chest CT. Her lung problems progressed, resulting in the need for ventilator support and high doses of steroids, albeit with no effect. She died 2 months after total lung irradiation. Autopsy was not performed.

## 2.3. Radiotherapy treatment technique for Cases 1 and 2

Both patients were treated with TLI using parallel opposing fields. Both treatment plans also included additional smaller field segments to improve dose homogeneity (Figs. 4 and 5).

Beam energy was 15 MV on all fields for the 18 year old patient, while the 17 year old patient was treated using 6 MV on the main opposing fields, and 15 MV for the segments.

The dose was calculated in Masterplan v.3.3 (Nucletron – an Elekta company, Veenendaal, The Netherlands) using the collapsed cone algorithm on CT images with 2.5 mm slice thickness. Mean bilateral lung dose was normalized to 19.5 Gy in 13 fractions, treated

Download English Version:

<https://daneshyari.com/en/article/2136234>

Download Persian Version:

<https://daneshyari.com/article/2136234>

[Daneshyari.com](https://daneshyari.com)