



Congenital B-lymphoblastic leukemia with a cryptic MLL rearrangement and post-treatment evolution to mixed phenotype acute leukemia



Elizabeth Moschiano^a, Gordana Raca^b, Cecilia Fu^c, Paul K. Pattengale^b, Mathew J. Oberley^{b,*}

^a Veteran Administration Greater Los Angeles Healthcare, West Los Angeles Medical Center, 11301 Wilshire Blvd., Los Angeles, CA 90073, USA

^b Department of Pathology and Laboratory Medicine, Children's Hospital Los Angeles, Keck School of Medicine, University of Southern California, 4650 Sunset Blvd., Los Angeles, CA 90027, USA

^c Children's Center for Cancer and Blood Diseases, Children's Hospital Los Angeles, Keck School of Medicine, University of Southern California, 4650 Sunset Blvd., Los Angeles, CA 90027, USA

ARTICLE INFO

Article history:

Received 10 February 2016

Accepted 24 July 2016

Available online 2 August 2016

Keywords:

Congenital leukemia

MLL rearrangement

Lineage switch

MPAL

ABSTRACT

Congenital leukemia is a rare event with a poor prognosis. We report a case of congenital leukemia with a cryptic rearrangement of MLL demonstrable only with RT-PCR. Interestingly, with treatment, the patient showed lineage plasticity of the leukemia with the development of monocytic lineage blasts after presenting with B-cell lineage blasts. This was heralded by the development of a new clonal cytogenetic abnormality. This case highlights the primitive nature of the leukemic cells in congenital leukemia, and emphasizes that RT-PCR for MLL rearrangements may identify a subset of cases which are otherwise negative by karyotyping, FISH, and chromosomal microarrays.

© 2016 The Authors. Published by Elsevier Ltd. This is an open access article under the CC BY-NC-ND license (<http://creativecommons.org/licenses/by-nc-nd/4.0/>).

1. Introduction

Leukemia which occurs in the first month of life (congenital leukemia) is a rare event, with an estimated incidence of 1 in 5 million births [1]. Congenital leukemias constitute a subset of infant leukemia where a significant percentage of cases show rearrangements involving the MLL (KMT2A) oncogene [2]. These rearrangements presumably arise in utero, and this leukemia subtype is notable for having the lowest somatic mutation burden of any human malignancy measured thus far [3]. Despite this, outcomes remain poor, and novel approaches to the treatment of this leukemia are needed. We describe an unusual case of congenital leukemia with lineage switch following treatment, CNS involvement, and a cryptic MLL rearrangement detectable only by RT-PCR.

2. Case study

A full term male was born to a 29-year-old G2P2 mother with an unremarkable prenatal course. He was 7 pounds 14 ounces at birth with normal APGAR scores at 1 and 5 min. On physical exam, he was noted to have nodular purpuric lesions on his trunk and

face, despite a non-traumatic delivery, and marked hepatosplenomegaly. A complete blood count showed a white blood cell count (WBC) of 126 K/ μ L, hemoglobin of 16.7 g/dL, platelet count of 23 K/ μ L, and 47% circulating lymphoblasts (Fig. 1A).

Flow cytometric immunophenotyping showed the circulating blasts expressed CD19, CD20, CD22, CD24 partial, HLA -DR, CD34, and TdT. There was variable expression of the myeloid markers CD15 and CD33. The blasts were negative for CD3, CD10, MPO, and all other T-cell, myeloid, and monocytic markers evaluated, including CD14, CD64, and CD7 (Fig. 1C). A diagnosis of B-lymphoblastic leukemia was made. Cytogenetics testing did not reveal any karyotypic abnormalities, and FISH studies were negative for MLL rearrangement (break apart probes), BCR-ABL fusion, ETV6-RUNX1 fusion, and showed disomy for chromosomes 4, 10 and 17. A cerebrospinal fluid sample taken at diagnosis was positive for lymphoblasts (700 WBC/mm³, 39% blasts; 64,000 RBC/mm³). Because the lumbar puncture was traumatic, the patient did not meet criteria for CNS3 disease based on the Steinherz/Bleyer algorithm where the CSF WBC/RBC needs to be greater than 2 times blood WBC/RBC. Therefore, the patient was classified as CNS2c.

The patient received induction chemotherapy per modified Children's Oncology Group (COG) infant ALL protocol AALL01P1 with dexamethasone, vincristine, and daunomycin at 50% of age-adjusted infant doses; PEG-asparaginase, and intrathecal methotrexate.

While induction chemotherapy resulted in clearance of the peripheral lymphoblasts, a post-induction bone marrow evaluation showed only a partial response with 15% residual

* Correspondence to: Children's Hospital Los Angeles, 4650 Sunset Blvd., Los Angeles, CA 90027, USA.

E-mail address: moberley@chla.usc.edu (M.J. Oberley).

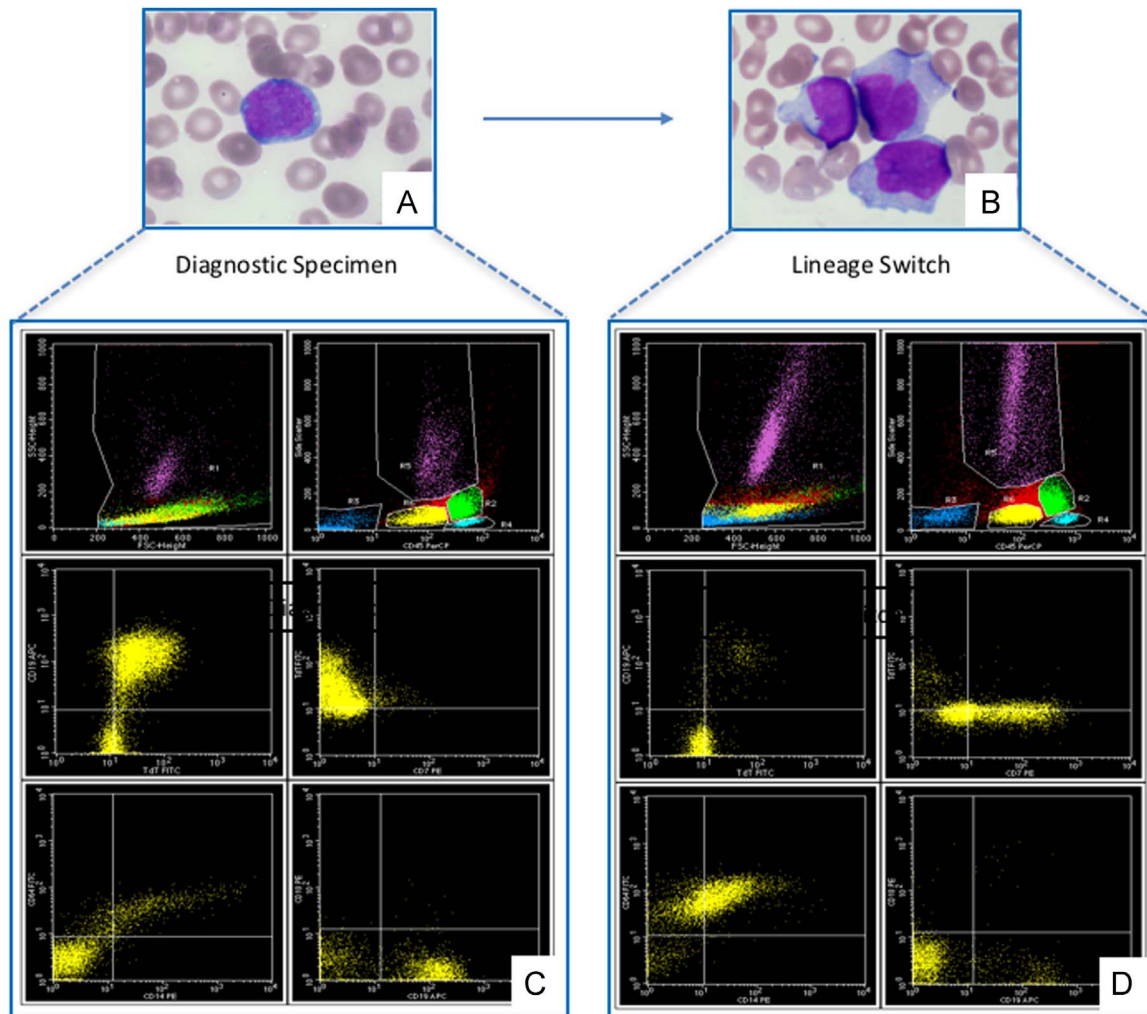


Fig. 1. **A.** Photomicrograph showing diagnostic specimen with lymphoblast morphology (Giemsa stain, 600X). **B.** Photomicrograph showing lineage switch specimen with monoblast morphology (Giemsa stain, 600X). **C.** At diagnosis, the CD45 dim blasts (yellow) were CD19+ (shown), CD22+, CD34+, CD10- (shown), CD14- (shown), CD64- (shown), CD7- (shown) and TdT+ (shown). **D.** With lineage shift, the blasts were CD19- (shown), CD34-, CD14+ (shown), CD64+ (shown), TdT- (shown), and CD7 partial (shown; see text for details).

lymphoblasts (day +35). Extended induction chemotherapy was given for an additional month (per St. Jude Infant Total XVI) which included cyclophosphamide, cytarabine, and oral mercaptopurine.

The post-extended induction bone marrow evaluation still showed 12% residual lymphoblasts (day +66). Evaluation of the blasts by flow cytometry at both time points (+35 and +66) showed an immunophenotype that was unchanged from the original diagnostic specimen.

Due to the suggestive immunophenotype and presentation, the bone marrow was sent at the day +66 time point for RT-PCR evaluation of various MLL fusion transcripts. A positive result was obtained for the presence of a MLL-MLL1 t(11;19)(q23;q13) fusion transcript. Despite the negative karyotyping and FISH results for MLL rearrangements, the RT-PCR results suggested that a cryptic MLL rearrangement was a driver in this neoplastic process.

He was then started on consolidation therapy per modified St. Jude Infant Total XVI with vincristine, high dose methotrexate (MTX) IV, and IT triples (MTX/ara-C/Hydrocortisone) with oral 6MP.

One month later the patient developed leukocytosis (WBC 46 K/ μ L) with 70% blasts and was re-induced to treat the persistent B-lymphoblastic leukemia. A post re-induction bone marrow performed at day +130 found 6% lymphoblasts with the same flow cytometric immunophenotype found at diagnosis. However,

karyotyping demonstrated a subset of cells with clonal evolution: 46, XY, +6[2]/46, XY[18].

The chemotherapy was then modified to a regimen of vinorelbine, mitoxanthrone, dexamethasone and Bortezomib[4]. A bone marrow evaluation following re-induction with the modified regimen (day +180) revealed 33% blasts, this time with monocytic features by morphology (Fig. 1B). Rare lymphoblasts were also present; cytochemical staining for MPO was negative in all blasts. A repeat RT-PCR for t(11;19)(q23;p13) was again positive.

Flow cytometric immunophenotyping confirmed the morphologic impression of blast monocytic lineage; there was a small subset of blasts with an immunophenotype consistent with the original B-ALL, and a much larger subset of blasts expressing CD2 dim, CD4 partial, CD7, CD56, CD22 dim, CD13 partial, CD15, CD33, CD117 partial, CD14, CD64, and CD38 bright. These blasts were negative for CD19, CD10, CD24, and TdT, and expressed dim MPO, an immunophenotype consistent with monocytic blasts (Fig. 1D). A subsequent cerebrospinal fluid (CSF) specimen demonstrated significant leukocytosis (36 WBC/ mm^3 ; 1 RBC/ mm^3) with 96% promonocytes with atypical morphologic features, suggesting CNS involvement by the lineage switched leukemia.

We performed chromosomal microarray analysis (CMA) analysis using CytoScan HD arrays from Affymetrics (Affymetrics, Santa Clara, CA) on the patient's sample obtained at the time of

Download English Version:

<https://daneshyari.com/en/article/2140274>

Download Persian Version:

<https://daneshyari.com/article/2140274>

[Daneshyari.com](https://daneshyari.com)