Cellular Immunology 287 (2014) 36–45

Contents lists available at ScienceDirect

Cellular Immunology

journal homepage: www.elsevier.com/locate/ycimm

Exploring the role of short-course cyclosporin a therapy in preventing homograft valve calcification after transplantation

Qing Chang [a,*], Hui Jing [a], Mingshu Sun [b], Ping Xu [a]

[a] Cardiovascular Surgery Department, The Affiliated Hospital of Medical College, Qingdao University, 266003 Qingdao, China
[b] Rheumatology Department, The Affiliated Hospital of Medical College, Qingdao University, 266003 Qingdao, China

ARTICLE INFO

Article history:
Received 12 September 2013
Accepted 27 November 2013
Available online 8 December 2013

Keywords:
Homograft valve
Transplantation
Cyclosporine A
Rat
Immunology
Calcification
Degeneration

ABSTRACT

This study was designed to explore the role of short-course cyclosporin A therapy in preventing calcification. Homograft valves heterotopically allografted onto abdominal aorta from SD to Wistar rats. The expression of CD25, CD40L, CD71, calcium content and morphological change were observed. In control group, expression of immune indices got maximal at early stage postoperatively, and then gradually declined, remained at low level 12 weeks afterwards. In test group with Cyclosporin A, the expression of immune indices were lower than that of control group at 2–4 weeks postoperatively, but no significant difference was found 8 weeks afterwards. The calcification began from 4 weeks postoperatively, increased gradually and reached highest level at 12 weeks. In test group calcium content was much lower from 4 to 16 weeks postoperatively. It is concluded that cyclosporine A treatment can prevent calcification of homograft valves because it inhibited immune response at early stage after transplantation.

1. Introduction

Homograft valves have many advantages over commercially available mechanical and bioprosthetic valves including excellent hemodynamic function, very low thrombotic event rates, less susceptibility to infection and convenience of application. They are widely used in the treatment of congenital heart disease and valve disease. However, homograft valves have a high incidence of calcification and degeneration long-term after transplantation, which severely limits its clinical application. Consequently, a lot of researches have focused on this issue for a long time [1–4].

In this study, homograft valves were transplanted into abdominal aorta heterotopically in the rat model. The calcium content and immune indices in the samples are measured at different time points postoperatively and the morphological change was observed meanwhile.

This study was aimed to evaluate the immunosuppressive effect of short-course cyclosporin A therapy at early stage after transplantation and explore the mechanism of preventing homograft valves calcification. So, the results and the analysis report will be shown as follows.

2. Materials and methods

2.1. Homograft valve transplantation and grouping

The healthy inbreeding line adult female SD rats weighing 200–260 g, purchased from Beijing Vital River Laboratory Animal Technology Limited Company, served as the donor; while the healthy inbreeding line adult male Wistar rats weighing 200–260 g, purchased from Laboratory Animal Center of Shandong University, served as the recipient. All the rats were housed in a standard 12 h on/off light cycle with food and water ad libitum in the home cage and they were allowed to acclimate to their new surroundings for 10 days before experimental manipulation. The experimental protocols were approved by the local ethic committee. All efforts were made to minimize animals suffering and to reduce the number of animals used.

The monoclonal antibody of CD40L (Catalog number: 0103002-H1), CD25-FITC and CD71-FITC (Catalog number: QAH-ISO-1) were purchased from Jingmei Biotech Limited Company. The hemolysin was supplied by BECTON–DICKINSON Company.

The recipient rats were randomly divided into three groups: the test group treated with cyclosporine A for 2 weeks continuously after operation in a dose of 0.15 mg/kg d; the isogenic group consisted of the isogenic donors and recipients; while the control group received no any treatment except the valve homograft transplantation. All of them underwent the same transplantation procedure.

* Corresponding author.
E-mail address: changqing20671@163.com (Q. Chang).

0008-8749/$ - see front matter © 2013 Elsevier Inc. All rights reserved.
http://dx.doi.org/10.1016/j.cellimm.2013.11.008

The donor rats were fixed in the supine position and disinfected after general anesthesia. Then the heart was exposed through median sternotomy. Then we dissociated the ascending aorta and ligated left and right coronary arteries near their opening with the 8 ~ 0 prolene. The ascending aorta was cut near the opening of innominate artery and the heart was separated with two aortic valve leaflets and relevant aortic wall remained. All the homograft valves were preserved for 60 days by cryopreservation before transplantation.

The recipient rats were also fixed in the supine position and disinfected after general anesthesia. Then the abdominal aorta was exposed through abdominal median incision after general anesthesia. We freed the abdominal aorta from left renal vein to iliac artery crotch. After crossclamp abdominal aorta bloodstream, the front wall of abdominal aorta was incised longitudinally and then homograft was continuously sutured onto the front wall of the abdominal aorta with 8 ~ 0 prolene. The distal artery should pulsate well after reopening of the abdominal aorta. The abdominal incision was closed with a low dose of gentamycin left inside the abdominal cavity. The criterion of successful operations was that the rats revived well postoperatively and no paralysis of lower limbs was found the day after operation.

In each group, the rats were randomly separated into 5 subgroups, each of which contains eight rats. The subgroups were sacrificed respectively in the batches at 2, 4, 8, 12, 16 weeks postoperatively. The blood samples were obtained for assessing the expression of CD25, CD71, and homografts were taken for assessing the content of calcium and the expression of CD40L. At the sametime, morphological change was observed through light microscope and electron microscopy.

2.2. Observation of homografts through light microscope

The samples obtained from homografts were fixed with formaldehyde, cut into tissue slices (3 μm). Then the slices were observed and photographed through light microscope after hematoxylin and eosin (H&E) staining.

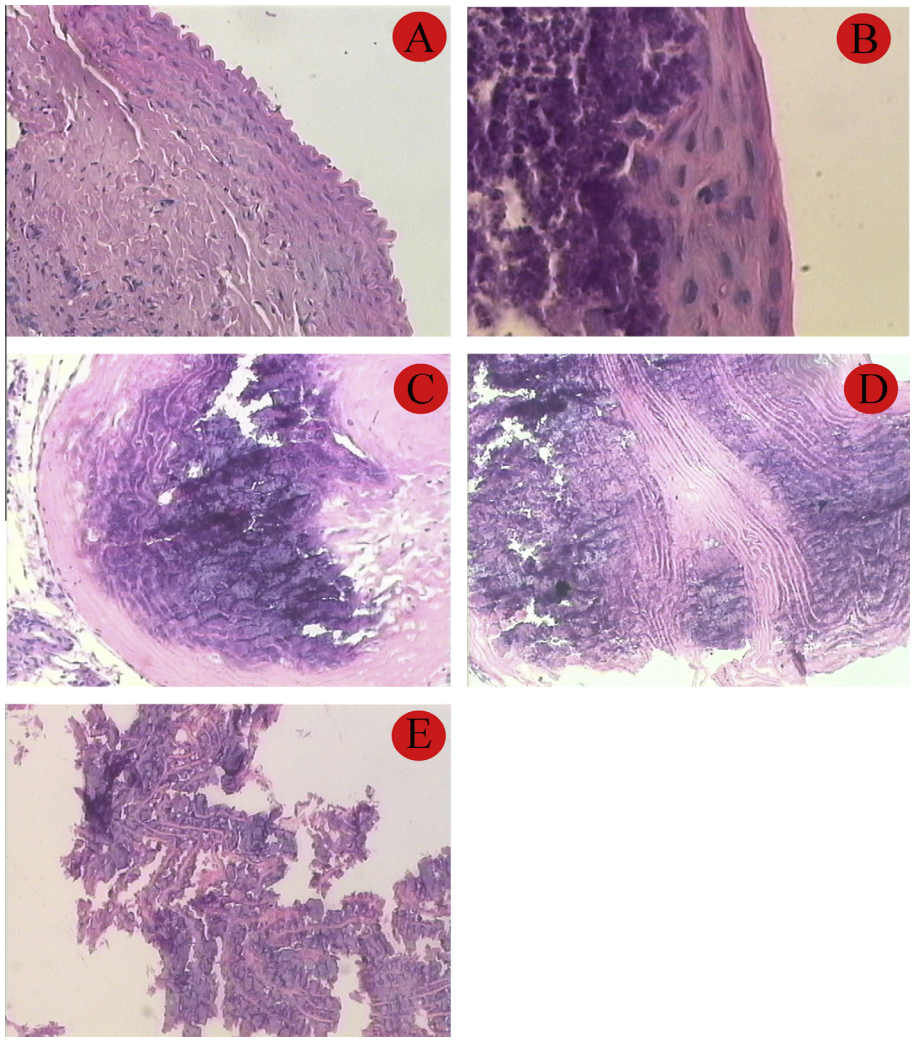

Fig. 1. Homograft valve in control group at different time points after transplantation. (A) Homograft valve in control group 2 weeks after transplantation: Representative light micrograph of homograft valve, showing the complete desquamation of endotheliocyte versus intact and normal smooth muscle cell and internal elastic lamina. (magnification 100×). (B) Homograft valve in control group 4 weeks after transplantation: Representative light micrograph of homograft valve, showing the large pieces of necrosis and calcification of smooth muscle cells. (magnification 400×). (C) Homograft valve in control group 8 weeks after transplantation: Representative light micrograph of homograft valve, showing the calcification of smooth muscle cells was much more ingravescent than before. (magnification 100×). (D) Homograft valve in control group 12 weeks after transplantation: Representative light micrograph of homograft valve, showing the calcification of smooth muscle cells reached the highest level (magnification 100×). (E) Homograft valve in control group 16 weeks after transplantation: Representative light micrograph of homograft valve, showing the calcification of smooth muscle cells reached the highest level (magnification 100×).