

Contents lists available at [ScienceDirect](http://www.elsevier.com/locate/TJEM)

Turkish Journal of Emergency Medicine

journal homepage: <http://www.elsevier.com/locate/TJEM>

Original article

Correlation of ischemia-modified albumin levels and histopathologic findings in experimental ovarian torsion



Ahmet Yildirim ^{a,*}, Sule Yildirim ^b, Naci Topaloglu ^b, Mustafa Tekin ^b, Adem Kucuk ^c,
Havva Erdem ^d, Mesut Erbas ^e, Dilek Ulker Cakir ^f

^a Department of Emergency Medicine, Faculty of Medicine, Canakkale Onsekiz Mart University, Canakkale, Turkey

^b Department of Pediatrics, Faculty of Medicine, Canakkale Onsekiz Mart University, Canakkale, Turkey

^c Department of Pediatric Surgery, Duzce Ataturk State Hospital, Duzce, Turkey

^d Department of Pathology, Faculty of Medicine, Duzce University, Duzce, Turkey

^e Department of Anaesthesiology, Faculty of Medicine, Canakkale Onsekiz Mart University, Canakkale, Turkey

^f Department of Biochemistry, Faculty of Medicine, Canakkale Onsekiz Mart University, Canakkale, Turkey

ARTICLE INFO

Article history:

Received 16 May 2015

Received in revised form

11 July 2015

Accepted 23 July 2015

Available online 10 March 2016

Keywords:

Ischemia-modified albumin

Ovary

Pathology

Rats

ABSTRACT

Objectives: Ischemia modified albumin (IMA) levels significantly increased and may be used as a diagnostic marker in ovarian torsion. The aim of this study is to investigate whether there was any correlation between IMA levels and histopathologic changes in experimental ovarian torsion.

Material and methods: Fourteen Sprague-Dawley rats, each weighing 220–250 g were divided randomly into 2 groups; in Group 1, the control group (n = 7), only laparotomy was performed and in Group 2, the experimental group (n = 7), ovarian torsion was performed. Ischemia was performed for 3 h; following the ischemia period, the torsion was relieved by detwisting the adnexa and then the ovarian I/R protocol was applied for 3 h. Blood samples were taken from all of the rats to measure the IMA levels and the ovaries were surgically removed for histologic examination. A blinded pathologist examined and scored the samples.

Results: The median (minimum–maximum) IMA values were 921.00 (870.00–966.00) ABSUs in the ovarian torsion group and 853.00 (782.00–869.00) ABSUs in the control group. The difference was statistically significant. In the correlation analysis, a significant and strong correlation was found between IMA levels and histopathologic changes (Spearman's rho = +0.987, p < 0.001).

Conclusion: Positive correlation was found between the IMA levels and the histopathologic severity of the disease. This finding is important for both diagnosis of the disease and patient follow-up. As a new marker in ovarian torsion, IMA may also indicate the severity of the ovarian histopathology.

Copyright © 2016 The Emergency Medicine Association of Turkey. Production and hosting by Elsevier B.V. on behalf of the Owner. This is an open access article under the CC BY-NC-ND license (<http://creativecommons.org/licenses/by-nc-nd/4.0/>).

1. Introduction

Ovarian torsion is a kind of emergent state which is rotation of the ovarian peduncle partially or completely around its own axis. It can be seen at any stage of a woman's life, including the newborn period, but it mostly occurs during a female's premenarchal and

reproductive years. Therefore, early diagnosis of ovarian torsion is very important for a woman's reproductive health. The intervention may delay because of nonspecific clinical findings of the disease.^{1,2} The usual presentation is the sudden onset of unilateral lower quadrant pain, but episodic pelvic pain may also develop in the intermittent torsion. Pathological and radiological findings vary in terms of the degree to which the vascular structure is involved. In the early stage of the torsion, only venous return is reduced from the ovary and ovarian enlargement, edema and interstitial hemorrhage occur. Ovarian necrosis begins when the arterial flow is disrupted.³

During the period of ischemia free oxygen radicals are produced in the tissues. Endothelial damage, tissue edema and increasing microvascular permeability can be seen to a greater extent in the

* Corresponding author. Canakkale Onsekiz Mart University, Faculty of Medicine, Department of Emergency Medicine, 17000 Canakkale, Turkiye. Tel.: +90 5059063338, +90 2862635651x1099, +90 5059063333.

E-mail address: ahmetyildirim@comu.edu.tr (A. Yildirim).

Peer review under responsibility of The Emergency Medicine Association of Turkey.

reperfusion state than in the ischemic period.^{4,5} It is thought that, in ischemia reperfusion (I/R) states, reactive oxygen radicals and acidosis can cause some structural changes in the albumin. Due to these modifications, the albumin's ability to bind to some metal ions, particularly copper, nickel and cobalt, decreases and it can no longer bind to those ions as well as the newly formed ion called ischemia modified albumin (IMA).⁶

IMA is accepted as one of the non-specific biochemical markers in ischemic tissues.⁷ While there are many studies related to ovarian torsion in the literature, there is only one experimental study about ovarian torsion and IMA, conducted by Aran et al⁸ and it showed that the IMA levels significantly increased and may be used as an early diagnostic marker in ovarian torsion.

In the current study, we aimed to investigate whether or not there was any correlation between a likely increase in IMA levels and histopathologic findings in experimental ovarian torsion in rats.

2. Material and methods

Fourteen Sprague-Dawley rats, each weighing 220–250 g were studied. During the study, all rats were housed in special cages and underwent appropriate feeding conditions at Experimental Research Center. Animal care and all procedures were approved by the Animal Care Committee (30.05.2013/2013-05-01/) of the university.

2.1. Experimental model

The 14 rats divided randomly into 2 groups; in Group 1, the control group (n = 7), only laparotomy was performed and in Group 2, experimental group (n = 7), ovarian torsion was performed. All rats were anesthetized with intramuscular 50 mg/kg ketamine hydrochloride (KetalarR, Eczacıbası, Istanbul, Turkey) and 10 mg/kg xylazine hydrochloride (10 mg/kg, Rompun, Bayer, Istanbul, Turkey) and then a 2.5 cm longitudinal incision was made in the lower abdominal region where the adnexa are located. In the experimental group, right adnexa was rotated by 1080° in a counter-clockwise direction and the twisted adnexa was fixed to anterior abdominal wall using 4/0 silk suture and the anterior wall was sutured in two layers using 3/0 silk. In group 1, the adnexa were palpated and left in their own anatomical position without rotation and the rats underwent only laparotomy. In Group 2, ischemia was performed for 3 h; following the ischemia period, the torsion was relieved by detwisting the adnexa and then the ovarian I/R protocol was applied for 3 h.⁹ Intracardiac blood samples were taken from all of the rats and the ovaries were surgically removed for histologic examination.

2.2. IMA measurement

Once the blood samples were taken, serum and plasma specimens were prepared with 10 min centrifugation at 1800 g. The specimens were pipetted into Eppendorf tubes and stored at –80 °C until the analysis was conducted. The reduced cobalt to albumin binding capacity (the IMA level) was analyzed using the rapid colorimetric method.¹⁰ The results are reported as absorbance units (ABSUs).

2.3. Histopathologic examination

The ovaries were fixed in 10% formalin solution. The tissues were dehydrated and embedded in paraffin and pieces of the ovarian tissue (5 µm thick) were stained with hematoxylin and eosin. The sections were examined and photographed with a light microscope. A blinded pathologist examined and scored the

samples. Congestion, hemorrhage, leukocyte infiltration, follicular degeneration, and interstitial edema were scored ranging from 0 to 3 according to the injury severity, where 0 represented no pathologic findings and 1, 2 and 3 represented pathologic findings of less than 33%, 33%–66%, and more than 66% of the ovarian section, respectively.¹¹

2.4. Statistical analysis

Statistical analyses were performed using the Statistical Package for the Social Sciences (19.00 SPSS Inc., IBM, Corp., Chicago, Illinois, USA). Normality tests were done using the Kolmogorov–Smirnov test. The tissue damage scores were compared by nonparametric analysis, and statistical significance was determined by the Kruskal–Wallis test. The Mann–Whitney U test was used to compare the two groups. A p value < 0.05 was considered significant.

3. Results

The median (minimum–maximum) IMA values were 921.00 (870.00–966.00) ABSUs in the ovarian torsion group and 853.00 (782.00–869.00) ABSUs in the control group (Fig. 1). There was a significant statistical difference between groups (p = 0.001).

In the histopathologic sections, no pathologic changes were found in the control group. In Group 2, marked hemorrhage, congestion and inflammation were found (Fig. 2). The findings and scores were significantly different between the groups. The histopathologic scores of both groups are summarized in Table 1.

In the correlation analysis, a significant and strong correlation between the IMA levels and the histopathologic changes (Spearman's rho = +0.987, p < 0.001).

4. Discussion

The IMA values of the I/R models (the experimental group) were significantly higher than the control group. In addition, a strong positive correlation was found between the IMA levels and the histopathologic findings in the experimental group.

There are no specific laboratory, radiologic, ultrasonographic, or doppler flow findings for adnexal torsion.¹² Therefore, the diagnosis of ovarian torsion could be missed or delayed. Peripheral follicles, free fluid in the abdomen and ovarian mass image in

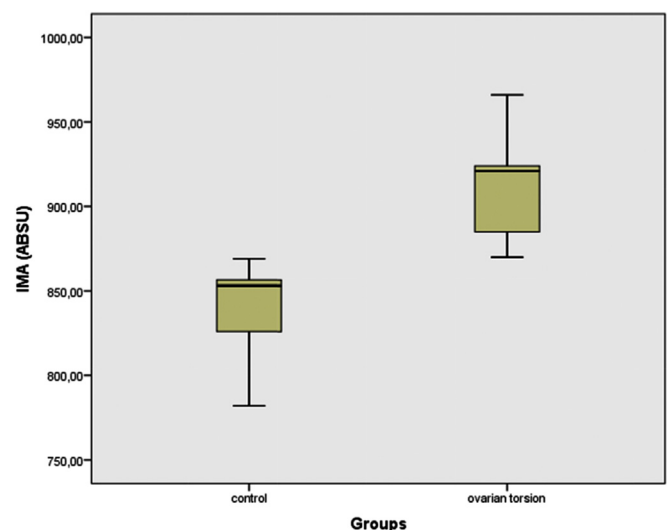


Fig. 1. IMA values of experimental groups.

Download English Version:

<https://daneshyari.com/en/article/2604068>

Download Persian Version:

<https://daneshyari.com/article/2604068>

[Daneshyari.com](https://daneshyari.com)