



Pulmonary toxicity associated with the use of lenalidomide: Case report of late-onset acute respiratory distress syndrome and literature review

J. Mankikian^{a,*}, B. Lioger^b, E. Diot^b, P. D'Halluin^b, S. Lissandre^c, S. Marchand Adam^a, E. Mercier^d, F. Beau Salinas^e

^aService de Pneumologie et Explorations Fonctionnelles Respiratoires, CHRU de Tours, France

^bService de Médecine Interne, CHRU de Tours, France

^cService d'Hématologie et Thérapie Cellulaire, CHRU de Tours, France

^dService de Réanimation Polyvalente, CHRU de Tours, France

^eService de Pharmacologie Clinique Centre Régional de Pharmacovigilance, CHRU de Tours, France

ARTICLE INFO

Article history:

Received 19 September 2013

Received in revised form

14 November 2013

Accepted 20 November 2013

Available online 19 December 2013

Keywords:

ARDS

Lenalidomide

Drug toxicity

ABSTRACT

Lenalidomide is an immunomodulating drug structurally similar to thalidomide. It is indicated for patients with relapsing or refractory multiple myeloma in combination with dexamethasone, and for patients with myelodysplastic syndromes associated with a deletion 5q cytogenetic abnormality. It is also used to treat other myelodysplastic syndromes such as myelofibrosis and lymphoma. We report a case of organizing pneumonia leading to acute respiratory distress syndrome (ARDS) after long-term administration of lenalidomide, along with a review of the literature.

© 2014 Elsevier Inc. All rights reserved.

Introduction

Lenalidomide is an immunomodulating drug structurally similar to thalidomide, which increases T-cell proliferation and NK-cell-mediated killing of tumor cells (Fig. 1). It is indicated for patients with relapsing or refractory multiple myeloma in combination with dexamethasone, and for patients with myelodysplastic syndromes associated with a deletion 5q cytogenetic abnormality. It is also used to treat other myelodysplastic syndromes such as myelofibrosis and lymphoma. Many adverse events have been reported,¹ such as bone marrow suppression with severe neutropenia associated with infection, venous and/or arterial thrombosis, peripheral neuropathy, cardiac toxicity, and the specific tumor flare reaction associated with chronic lymphocytic leukemia.² Lenalidomide-induced pulmonary disease is rare. Since the first report by Thornburg et al, in 2007,³ a few cases have been published highlighting potential lung toxicity,^{4–16} often occurring after a short course of administration, and inducing moderate and occasionally more severe respiratory symptoms. We report a case of

organizing pneumonia leading to acute respiratory distress syndrome (ARDS) after long-term administration of lenalidomide.

Case report

A 60 year-old Asian man with a previous history of myelofibrosis without JAK 2 mutation was admitted to the intensive care unit (ICU) with ARDS in January 2011. He had lived in France for 30 years, working as a leather worker, did not have any pulmonary conditions and had never smoked. He had been taking lenalidomide since April 2010 for an anemia refractory to iterative transfusion, with a scheduled dose adapted to his hematopoiesis, initially 10 mg followed by 15 mg every other day. His condition had remained stable over the previous 6 months. Two weeks prior to admission, he presented with dry cough, dyspnea, fever and flu symptoms, with no improvement despite first-line antibiotic treatment with cefixime 400 mg per day. The initial clinical and radiological assessments revealed hypoxemic pneumonia with diffuse and nodular alveolar opacities. Laboratory findings revealed an inflammatory syndrome (CRP 121 mg/L [normal < 6 mg/L]) and pancytopenia (hemoglobin 5.5 g/dL [normal 13–17 g/dL], platelets 55,000/μL [normal 150,000–400,000/μL], white blood cell count 700/μL [normal 4000–10,000/μL], absolute neutrophil count 470/μL [normal 1500–7500/μL]). All

No conflict of interest.

* Corresponding author.

E-mail address: karoun@orange.fr (J. Mankikian).

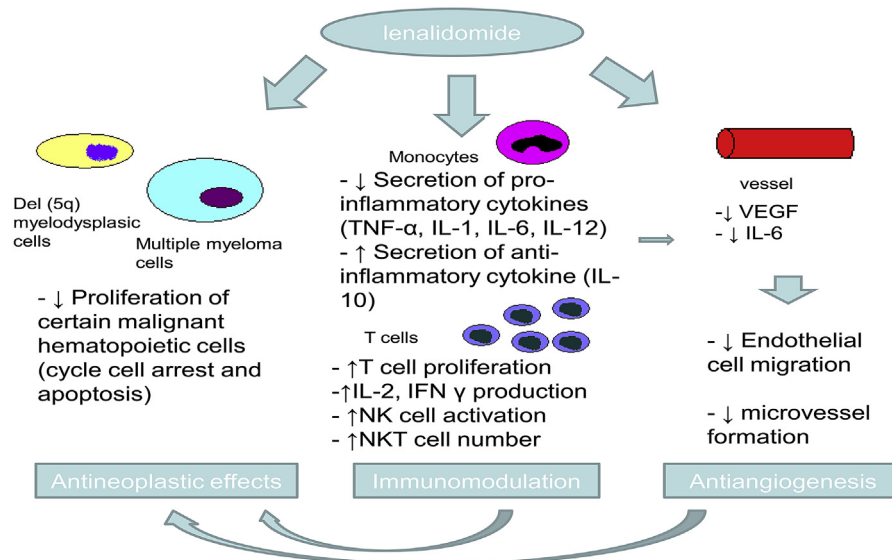


Fig. 1. Lenalidomide's main mechanisms of action. Lenalidomide has direct antiproliferative effects (cycle cell arrest and apoptosis; other mechanisms such as inhibition of COX-2 and PGE2 production may be involved) and also immunomodulatory and antiangiogenic properties.

bacteriological cultures (blood, urine) and urine pneumococcal and legionella antigens remained negative.

Despite treatment with ceftriaxone, ofloxacin, oxygen 2L/min, blood transfusion and lenograstim injection, the patient's condition deteriorated and he was transferred to ICU.

He was intubated due to severe ARDS defined by bilateral alveolar opacities on chest X-ray, PaO₂/FiO₂ ratio < 100 mm Hg, with PEEP = 10 mm Hg and no cardiac failure in echocardiography. He received broad-spectrum anti-infectious therapy, with piperacillin-tazobactam, spiramycin, and oseltamivir, due to the epidemic context, and caspofungin.

Bronchoscopy with broncho-alveolar lavage (BAL) was performed. Bacterial, viral, fungal (with search for *Pneumocystis jirovecii*) and acid-fast bacilli cultures were negative. Cytological analysis revealed hypercellularity (420/mm³ [normal 150–300/mm³]) with 67.5% lymphocytes [normal < 15%], 30% alveolar macrophages, 2.5% neutrophils, 0% eosinophils. The immunological tests found non-specific immunity with anti-nuclear antibodies (1/400 [normal: negative]).

The clinical condition deteriorated despite intravenous antibiotics, appropriate ventilation and prone position sessions, and BAL lymphocytosis led us to start intravenous corticosteroid treatment on day 3 of the patient's arrival in intensive care at a dose of 2 mg/kg/day for 72 h, then 1 mg/kg/day. Clinical and radiological features improved dramatically, and the patient was extubated on day 8.

The first High Resolution Computed Tomography (HRCT) could not be performed until one week after beginning steroids because of the severity of the ARDS. It showed diffuse ground-glass opacities with multiple and peripheral nodular parenchymal consolidation.

Extensive workup of the patient's clinical condition and radiological features supported a diagnosis of lenalidomide-induced organizing pneumonia, and lenalidomide was stopped. Subsequently, the patient was rapidly weaned off oxygen and returned home a few weeks later. A second HRCT performed three weeks later showed the favorable outcome with steroids (Fig. 2).

Discussion

The clinical presentation, radiological patterns and lymphocytosis in bronchoalveolar fluid support the diagnosis of organizing pneumonia with ARDS. All cultures of infectious samples were

negative, the time between the last transfusion and the respiratory deterioration (one day) was too long to suggest transfusion-related acute lung injury, and no immunologic etiology was found. The development of pulmonary symptoms during treatment with lenalidomide, the absence of other causes of pneumonia, and the dramatic improvement after drug withdrawal and systemic corticoid treatment, without relapse at the end of corticotherapy, strongly support the diagnosis of lenalidomide-induced pneumonia. No other drug was taken by the patient.

To our knowledge, no pulmonary toxicity was revealed during the main clinical trials of lenalidomide in multiple myeloma,^{17,18} except severe cough and dyspnea.¹⁷ However, in a non-comparative phase II clinical trial with lenalidomide in association with dexamethasone, 3% of the 34 patients had moderate pneumonitis, and 6% severe pneumonitis.¹⁹ Three other cases of pneumonitis and one case of eosinophilic pneumonia have been reported during other clinical trials in multiple myeloma.^{4,6,8}

More recently, a few other case reports or case series of pulmonary toxicity secondary to lenalidomide have been published.^{3,5,9–16} The presentation was subacute or acute, mimicking non-specific interstitial pneumonitis,^{8,12–15} associated with rash in two cases,¹² hypersensitivity pneumonitis,^{3,5,9,10} organizing pneumonia,⁷ diffuse alveolar hemorrhage,¹¹ and only one ARDS.¹⁶ The unusual aspect of our case is the severity of the clinical presentation with severe ARDS, and the late onset of this complication in relation to the introduction of lenalidomide. All but one of the previously published cases of pneumonitis were moderate, requiring oxygenation but no ventilation, and our patient is the second reported case of pneumonitis with ARDS requiring mechanical ventilation.¹⁶ The second unusual feature of our patient is the length of time (7 months) between the introduction of lenalidomide and the onset of symptoms. The pulmonary symptoms in the previously published cases appeared within a few days or weeks after lenalidomide was started,^{3,7,9–16} and occasionally between 7 and 24 months.¹² Outcome was always favorable after lenalidomide was stopped, and in most cases antibiotics and corticosteroids were prescribed. However, recurrence of pneumonitis was observed in three cases with standard,¹⁶ or reduced doses of lenalidomide,^{3,14} but not in two other cases at the standard dose in association with corticosteroids.¹²

Lenalidomide-induced pulmonary toxicity seems to be rare. Some authors have suggested that frequent prescription of

Download English Version:

<https://daneshyari.com/en/article/2651787>

Download Persian Version:

<https://daneshyari.com/article/2651787>

[Daneshyari.com](https://daneshyari.com)