

TECHNICAL NOTE / *Musculoskeletal imaging*

# Axial traction in magnetic resonance arthrography of the wrist: How to do?



T. Kirchgesner<sup>a,\*</sup>, L. Pesquer<sup>b</sup>, A. Larbi<sup>a</sup>, P. Meyer<sup>b</sup>,  
M.-H. Moreau-Durieux<sup>b</sup>, A. Silvestre<sup>b</sup>,  
B. Dallaudière<sup>a,b,c</sup>

<sup>a</sup> Service de Radiologie, Département d'imagerie musculo-squelettique, Cliniques Universitaires Saint-Luc, avenue Hippocrate 10, 1200 Bruxelles, Belgium

<sup>b</sup> Centre d'imagerie ostéoarticulaire, Clinique du Sport, Bordeaux Mérignac, 2, rue Georges-Negrevergne, 33700 Mérignac, France

<sup>c</sup> Université Paris Diderot, 5, rue Thomas-Mann, 75205 Paris, France

## KEYWORDS

MR;  
Arthrography;  
Wrist;  
Axial;  
Traction

Magnetic resonance (MR) arthrography is an efficient technique to study both intrinsic and extrinsic ligaments as well as the triangular fibrocartilage complex (TFCC) of the wrist [1,2]. While multidetector computed tomography (MDCT) arthrography is superior in cortical bone and articular cartilage analysis because of its higher spatial resolution, MR arthrography is better to assess medullar bone and soft tissues such as ligaments and tendons because of its higher contrast resolution [1]. MR arthrography is especially accurate for detection of non-transfixing TFCC rupture with a sensitivity and specificity of 85 and 76% compared with standard MR imaging (sensitivity and specificity of 17 and 79%) [3,4]. Stress maneuvers inspired by arthroscopic techniques have previously been developed for shoulder, hip and knee and even metatarsophalangeal MR arthrography [5–8]. Guntern et al. studied 12 wrist MR arthrographies with and without traction and demonstrated a significant increase in joint space width at the radiocarpal and lunocapitate spaces resulting in better coverage of the articular cartilage by the contrast material with axial traction [5]. Cerny et al. investigated 20 MR arthrographies of the wrist and conclude that axial traction may enhance both detection and characterization of scapholunate and lunotriquetral ligament tears by widening the articular space and increasing the amount of contrast within [6].

## Technical method and discussion

The procedure begins with arthrography to opacify the mediocarpal, radiocarpal and distal radioulnar joints under fluoroscopic guidance with one to three separate

\* Corresponding author.

E-mail address: [Thomas.Kirchgesner@gmail.com](mailto:Thomas.Kirchgesner@gmail.com) (T. Kirchgesner).

puncture(s) depending on the presence of communications. The operator first injects with a 23-gauge needle in a sterile manner a few drops of iodinated contrast medium (Hexabrix® 320 mg – Guerbet, France) in the joint to assure the intra-articular position, then diluted Gadolinium-based medium (Artirem® – Guerbet, France). Arthrographic blend can be commercially packaged or manually prepared: 0.1 mL of Gadolinium-based medium for intravenous injection diluted in 10 mL of saline solution with 5 mL of iodinated contrast agent and 5 mL of 1% Lidocaine is the safest and best mixture [9].

It is important to blow off all air trapped in the needle which may complicate interpretation. Joint capacity is small so that injection of an excessive quantity of iodinated contrast leads to insufficient quantity of intra-articular Gadolinium-based agent and must then be avoided. Finally, excessive injected contrast volume brings diffusion in soft tissue, which may alter analysis of extra-capsular structures. MR should be performed during the first 30 minutes following injection to limit contrast resorption.

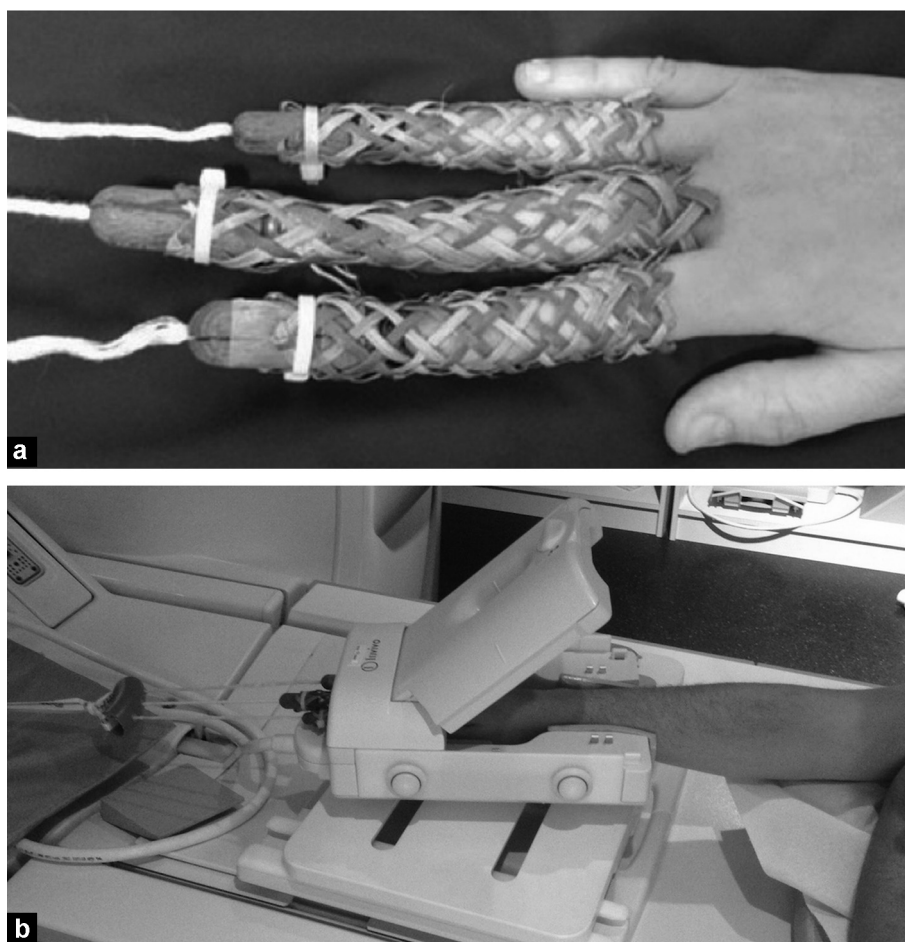
The patient is placed in the “Superman” position, prone with arm extension over the head and wrist in slight pronation, which is well tolerated. The contralateral arm can be placed above the head or at side of patient. MR should be

performed using a dedicated wrist coil such as an 8-channel high-resolution wrist coil.

The easiest method to conduct axial traction is to use Chinese finger traps with a pulley system and weights. Weight and number of digits trapped are variable: Guntern et al. used a 3 kg weight with 2 digits (second and fourth) while Cerny et al. used 4 kg weight with 3 digits (second to fourth) [5,6]. Leventhal et al. even put up weight to 10 kg distributed equally across all 5 digits [10]. In our center, we use a 3 kg weight and 3 digits trapped with very good tolerance by patients (Fig. 1).

It is essential to perform manual axial distraction of the wrist joint before placing the weight, which will allow continuous traction during the exam and maintains constant articular spaces distraction. Without prior manual distraction axial traction is useless. It is also important to explain the procedure to the patient to get relaxation and improve cooperation (Fig. 2).

MR protocol is variable. Based on our experience, we propose the following protocol [11]: axial and sagittal T1SE, coronal T1SE with fat saturation, axial or coronal DP with fat saturation and finally 3D acquisition in T1- and T2-weighted scans. T1-weighted-images are performed with and without fat saturation because Gadolinium and fat have identical



**Figure 1.** a: Chinese finger traps; b: patient arm placed in Superman position with a specific coil and continuous wrist distraction maintained by the traction mechanism (3 kg).

Download English Version:

<https://daneshyari.com/en/article/2732772>

Download Persian Version:

<https://daneshyari.com/article/2732772>

[Daneshyari.com](https://daneshyari.com)