

E-QUID: ANSWER / *Musculoskeletal imaging*

## Herniated disc extruded in the retroperitoneum<sup>☆</sup>



S. Djebbar<sup>a,\*</sup>, J. Manelfe<sup>b</sup>, P. Meyer<sup>c</sup>, P. Copin<sup>b</sup>,  
E. Desportes<sup>b</sup>, M. Gomes<sup>a</sup>, E. Souverain<sup>a</sup>, A. Nataf<sup>a</sup>,  
B. Dallaudiere<sup>b,c</sup>

<sup>a</sup> Service d'imagerie musculosquelettique, CHU de Lille, rue du Pr-Émile-Laine, 59037 Lille, France

<sup>b</sup> Hôpital Bichat – Claude-Bernard, 46, rue Henri-Huchard, 75018 Paris, France

<sup>c</sup> Clinique du sport, 2, rue Negrevergne, 33700 Mérignac, France

### Observation

A 57-year-old man consulted for repeated episodes of hyperalgetic left lumbar cruralgia, with sudden onset 3 weeks before without any specific antecedents.

The patient was afebrile. The clinical examination detected a spinal syndrome with left bending sign. The imaging of the lumbar spine included a CT scan without injection (Fig. 1a and b) and an MRI without and with injection of gadolinium (Fig. 2a, b, c and d).

<sup>☆</sup> Here is the answer to the case Left lumbar cruralgia in a 57-year-old man previously published. As a reminder we publish again the entire case with the response following.

\* Corresponding author.

E-mail address: [sahlyadjebbar@yahoo.fr](mailto:sahlyadjebbar@yahoo.fr) (S. Djebbar).

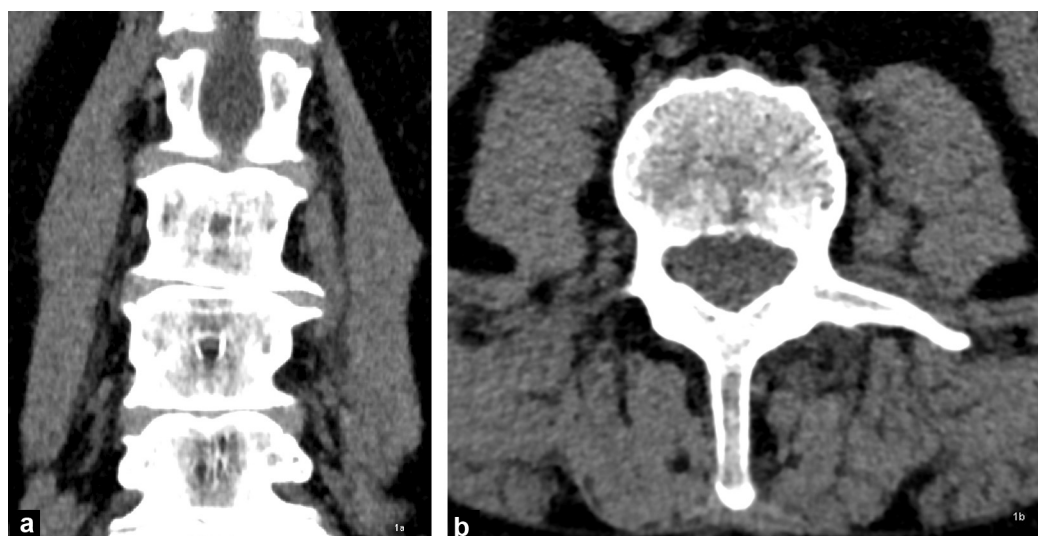


Figure 1. CT scan of the lumbar spine without injection.

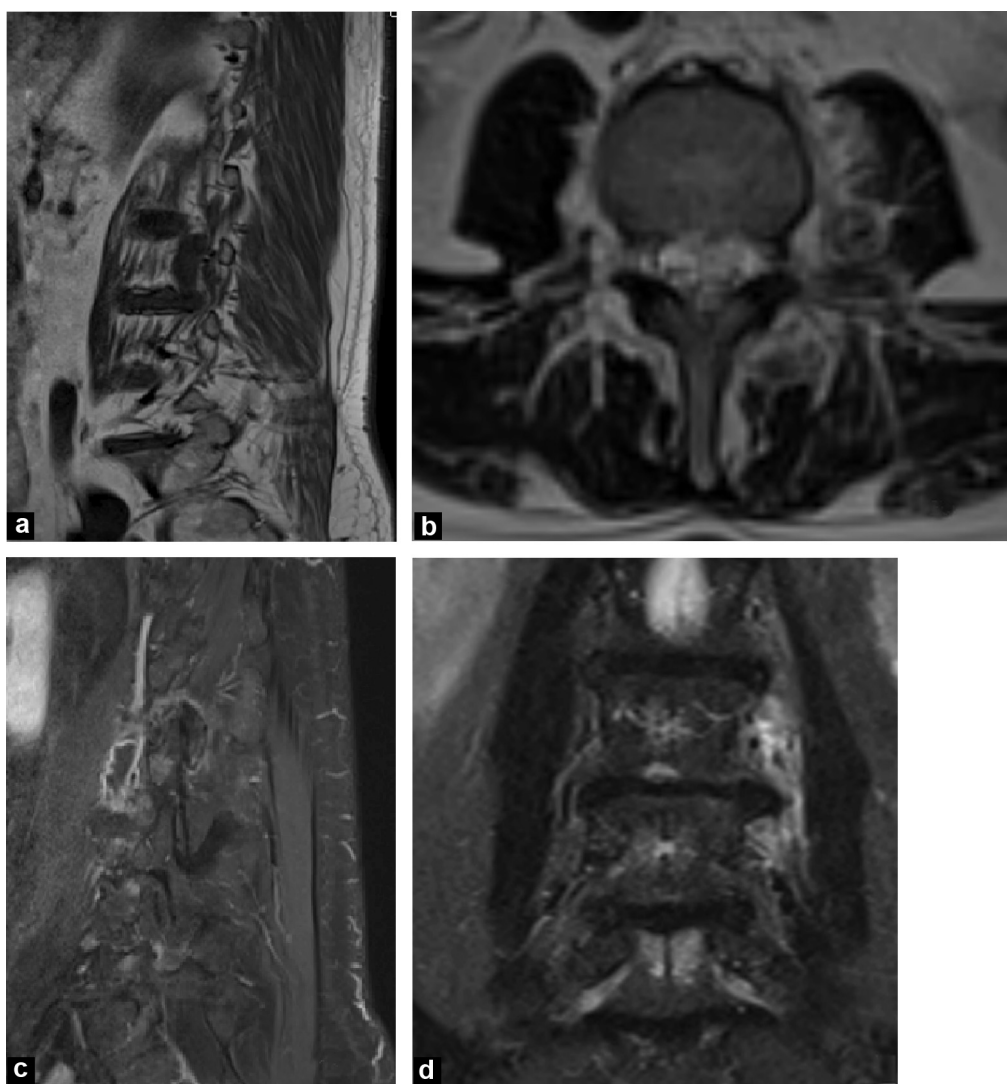


Figure 2. MRI without and with injection of gadolinium.

Download English Version:

<https://daneshyari.com/en/article/2732935>

Download Persian Version:

<https://daneshyari.com/article/2732935>

[Daneshyari.com](https://daneshyari.com)