



Summary

Different anatomical co-factors contribute to the course of a patellar instability. The trochlear groove stabilizes the patella as the most important static stabilizer. Therefore, a trochlear dysplasia is the most important bony abnormality impeding stability. Other rotational issues, i.e. deviations in the mechanical axis, rotational malalignment, patella alta, aggravate an instability.

Also, soft tissue alterations, such as medial patella-femoral ligament (MPFL) ruptures, postero-lateral insufficiency or a general hyperlaxity should not be ignored in treating patients with patellar problems.

Keywords

Patella dislocation – knee – trochlear dysplasia – medial patella-femoral ligament (MPFL) – mechanical axis – rotational malalignment – patella alta – postero-lateral insufficiency – hyperlaxity – risk factors

C. Camathias

Anatomische Co-Faktoren der Patellainstabilität bei Kindern und Jugendlichen

Zusammenfassung

Verschiedene Co-Faktoren beeinflussen den Verlauf einer Patellainstabilität.

Die Trochlea nimmt dabei den Platz als wichtigsten statischen Stabilisator ein. Eine Trochleadysplasie ist daher der wichtigste Faktor, der die Stabilität beeinträchtigt. Abweichungen der mechanischen Achse, ein Malalignment der Knochenrotation oder eine Patella alta können die Instabilität zusätzlich verschlimmern.

Weichteil-Affektionen wie die Ruptur des medialen patello-femorales Ligamentes (MPFL), postero-laterale Insuffizienzen oder eine generelle Hyperlaxität sollten in der Behandlung von Patienten mit Patella-Problemen einfließen.

Schlüsselwörter

Patella Luxation – Knie – Trochleadysplasie – mediales patello-femorales Ligament (MPFL) – mechanische Achse – rotations Malalignment – Patella alta – postero-laterale Insuffizienz – Hyperlaxität – Risiko-Faktoren

REVIEW/SPECIAL ISSUE

Anatomical co-factors in patellar instability in children and adolescents

Carlo Camathias^{a,b}

^aPaediatric Orthopaedic Department, University Children's Hospital Basle (UKBB), Basel, Switzerland

^bDepartment of Orthopedic Surgery, Boston Children's Hospital, Harvard Medical School, Boston, MA

Eingegangen/submitted: 02.06.2015; akzeptiert/accepted: 30.06.2015

Online verfügbar seit/Available online: 29.07.2015

Introduction

Patellar instability is a complex disorder of the knee extensor mechanism. It occurs in approximately 43 children per 100,000. [18] After a first event, as many as 15 - 44% experience another dislocation. [12,14] The earlier the patella dislocates during growth, the more probable is a recurrent course. More than 100 different options are known to treat a patellar instability. The presence of growth plates precludes several osteotomies, which could lead to sequelae. However, different anatomical co-factors can impede a successful treatment. These co-factors are not substantially different to them in adults. Nonetheless, they are challenged additionally by growth. The goal of this paper is to summarize the anatomical co-factors that can lead to or aggravate a patellar instability.

Trochlear dysplasia

The trochlear groove is the main patellar stabilizer, in which the patella glides during flexion of the knee. [22] It guides and stabilizes the patella during the entire range

of motion. [1] The bony structure, as well as the overlying cartilage, define its shape. [25] In case of a dysplastic trochlea, this form is considered to be flat or even convex. Déjour distinguishes between four main types, grouped according to its severity from A to D. [6] Most patients (>80%) with a recurrent patellar instability have developed a dysplasia [6] and the remaining soft tissues, i.e. the medial patella-femoral ligament (MPFL), have to absorb the dislocating forces. [22] As a flat trochlea allows the patella to be lateralized, it is possible, but not proven, that this condition elongates the MPFL over time and finally leads to a dislocation. A trochleaplasty can correct a trochlear dysplasia. However, in children and adolescents, a trochleaplasty is not to be considered. The physis is located at the entrance of the trochlear groove. A trochleaplasty would harm the growth plate.

Patella alta

A patella alta is defined as a more proximally positioned patella, i. e. a high-riding patella. Different authors emphasize the import role of this condition in causing patellar

instability. [3,15] In case of a longer patellar tendon, the patella enters slightly delayed and not centered in the trochlear groove.

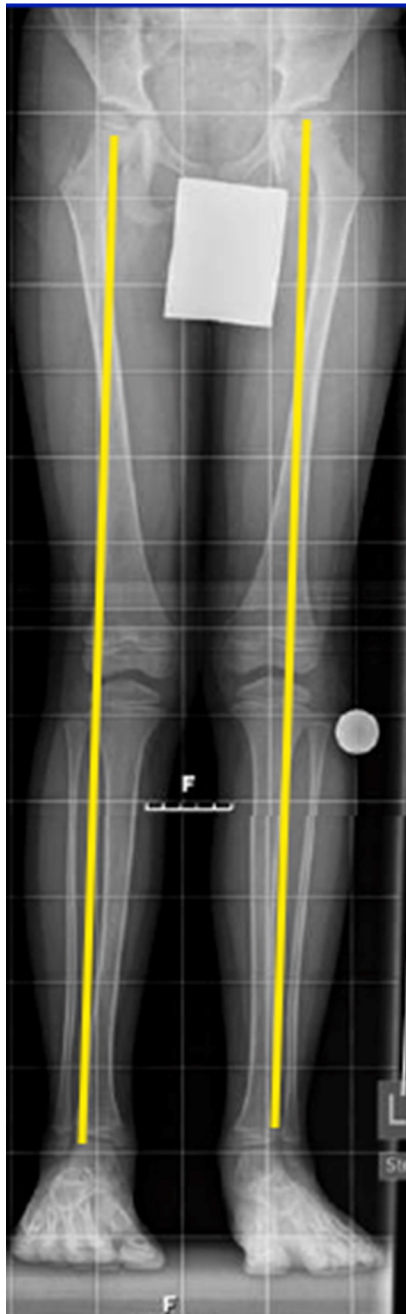


Figure 1
Mechanical axis of the leg.
 Case of 7 year old boy with a recurrent patellar dislocation on the right side. The mechanical axis deviates to lateral on the right side on the whole leg x-ray.

Contact forces change in patella alta with lower forces during initial flexion (35°-70°) and increased forces in deep flexion (>70°).[17] This mechanism could be an additional reason for a less stable patella during initial flexion. Treating a patella alta can be challenging. Due to open physes, distal osteotomies at the tuberosity are not suggested in childhood and soft tissue procedures are not effective.

Mechanical axis of the leg

Likewise in adults, the risk of a patellar instability increases with more valgus in the mechanical axis (Figure 1). The patella is then positioned more laterally to the axis. The knee capsule can be distended due to a valgus knee and as a result, patella stability may worsen additionally. Different to adults, the valgus changes over time. In children, the valgus is frequently accentuated, sometimes over 10 degrees, which is still physiological. Until puberty, a normal valgus should be evolved, comparable to them in adults. [31] Also, children with a patellar instability will improve their valgus. However, if it is still increasing, a valgus should be addressed

surgically before the growth plates have matured. With a tension band technique (Eight-plate) growth can be guided easily. It is advised to be cautious with the medial patella-femoral ligament (MPFL) when placing such a plate over the physes (see MPFL). [2]

Antetorsion of Femur

An increased antetorsion of the femur is associated with patella-femoral disorders. [30] (Figure 2) High antetorsion angles increase pressure on the lateral part of the trochlea, increase tilting of the patella and promote subluxation of the patella. [9] At the same time, the MPFL is tensioned. These phenomena are more pronounced in early flexion. [20] Comparable to the valgus; also the antetorsion of the femur is subject to change over time. The antetorsion is practically always increased during childhood, but resolves with age. Usually, values between 10° to 25° remain at the end of growth. [10,11] In treating a patello-femoral instability, the remaining high values of antetorsion after growth should be included in the therapy plan and be corrected with a rotational osteotomy.

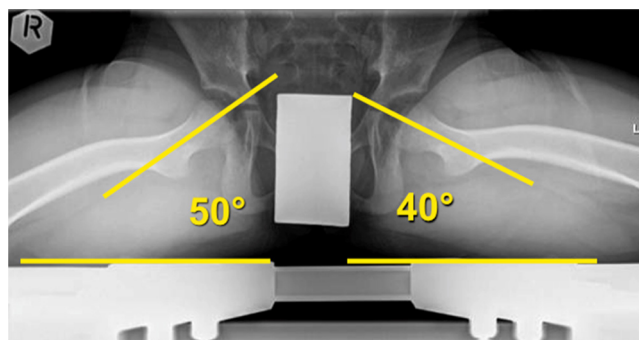


Figure 2
Antetorsion of femur.
 Same boy as in Figure 1. On the affected right side an increased antetorsion of the femur can be noted. The radiological technique to measure the torsion is described by Dunn.[8].

Download English Version:

<https://daneshyari.com/en/article/2740267>

Download Persian Version:

<https://daneshyari.com/article/2740267>

[Daneshyari.com](https://daneshyari.com)