

Central venous pressure and pulmonary artery pressure monitoring

Michael Gilbert

Abstract

Central venous pressure and pulmonary artery pressure are used as measures of cardiovascular filling. While pressure–volume relationships are not constant, trends in central venous pressure give an indication of increasing or decreasing right ventricular filling, while pulmonary artery pressure gives an indirect indication of left ventricular filling pressure. Cardiac output can be estimated by use of thermodilution.

Keywords Atrium; cardiac output; central venous; filling; hypovolaemia; pressure; pulmonary artery

Royal College of Anaesthetists CPD matrix: 1A03

Using pressure as an indicator of cardiovascular performance

The term **haemodynamics** describes the state of the circulation using measures which indicate its ability to generate blood flow and pressure, to ensure blood supply, and hence, oxygen delivery to the organ systems. Starling described the sequential triad of: **pre-load**, indicating the ‘fullness’ of the circulation; **contractility**, indicating the strength of ventricular myocardial contraction in ejection of the stroke volume into the great arteries; and **afterload**, which indicates the vascular resistance to blood flow, generated by vascular tone and blood viscosity.¹ When managing patients with haemodynamic compromise or instability, clinicians have to distinguish between these factors, to establish whether to treat their patients with intravenous fluids, positive inotropic agents or drugs which cause vasodilatation or vasoconstriction.

Central venous pressure

Central venous pressure (CVP), the pressure within the intrathoracic venae cavae, is measured by the insertion of a catheter via the internal jugular or subclavian veins (Figure 1). This is an invasive procedure, requiring maintenance of strict asepsis and high levels of skill. The procedure carries significant a risk of complication, with a recent review finding 5–19% of patients suffering mechanical complications, 5–26% of patients suffering catheter-related infection and 2–26% of patients suffering thrombotic complications (Box 1).²

CVP is normally equal to the right atrial pressure, unless there is obstruction of the venae cavae. The value used in clinical practice is the pressure recorded at the **base of the c-wave**, at the **end of expiration**, while the subject is **supine** (Figure 2). This

Michael Gilbert MB ChB FRCA is a Consultant Cardiothoracic Anaesthetist at Morriston Hospital, Swansea, UK. Conflicts of interest: none.

Learning objectives

After reading this article, you should be able to:

- describe the functional anatomy of the great veins, cardiac chambers and pulmonary arteries
- explain the physiological significance of venous filling pressures, and their use as trends in management of haemodynamics
- outline the sources of error in pressure measurement, and the risks associated with invasive monitoring

represents the pressure in the atrium immediately before the start of ventricular systole.³ In reality, vital signs monitors display the mean of the highest and lowest values of measured pressure, which may be slightly different to the ideal value. Normal values vary with the context of measurement, because right atrial

Risks associated with invasive haemodynamic monitoring

Mechanical complications

- **Blood vessel injury during vein cannulation**, including laceration of the internal carotid artery, subclavian artery or aortic arch, causing: local haematoma, haemothorax, cardiac tamponade, cerebral ischaemia, or upper limb ischaemia
- **Dysrhythmias**, most commonly premature atrial or ventricular complexes
- **Nerve injury during vein cannulation**, including cervical plexus and brachial plexus, recurrent laryngeal nerve, and phrenic nerve, causing: acute neck pain and/or paraesthesia, chronic pain, upper limb weakness, anaesthesia or paraesthesia, hoarseness or hemidiaphragm dysfunction
- **Pneumothorax** secondary to pleural puncture
- **Chamber perforation by guidewire**, including right atrium and right ventricle, causing: cardiac tamponade or haemothorax
- **Tricuspid or pulmonary valve injury**, usually occurring when an inflated pulmonary artery catheter (PAC) balloon is withdrawn through the valve
- **Pulmonary artery rupture**, occurring when a PAC balloon is inflated in a small calibre vessel or when an inflated balloon is left inflated, migrating to a small calibre vessel
- **Pulmonary infarction**, occurring when an occluding PAC balloon is left inflated for a prolonged period

Infective complications

- **Infection**, secondary to breaching the integrity of the skin at the cannulation site, including: localized sepsis at the cannulation site, or bloodstream infection

Thrombotic complications

- **Local thrombosis**, in internal jugular or subclavian vein, which may be complicated by pulmonary embolism
- **Late venous stenosis**, which is particularly prevalent when the subclavian vein is used

Box 1

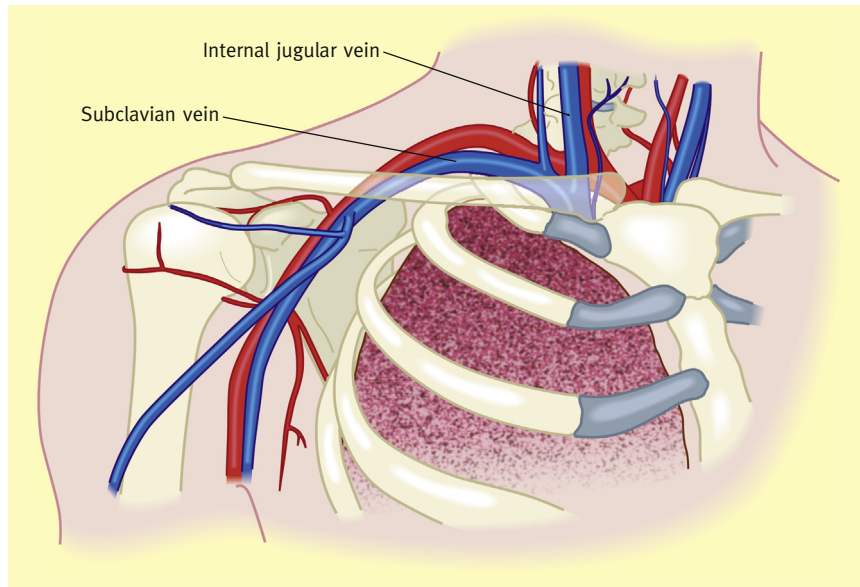


Figure 1 The upper thorax, showing the relational anatomy of the right internal jugular and subclavian veins.

pressure is not constant, but varies with the cardiac cycle, with breathing, and on change of position between upright and recumbent.

Factors decreasing right atrial pressure

Opening of the tricuspid valve: in early diastole, as pressure in the right ventricle drops below right atrial pressure, the tricuspid valve opens, and early diastolic flow across the tricuspid valve starts. The sudden decrease in atrial volume causes a drop in right atrial pressure, known as the **y-descent** (Figure 2).

Tricuspid annular plane systolic excursion: as the right ventricular myocardium contracts to eject blood into the pulmonary artery, it shortens longitudinally as well as concentrically, causing the annular plane of the tricuspid valve to move towards the apex of the right ventricle. This causes slight stretching of the right atrium, with a consequent decrease in right atrial pressure, known as the **x-descent** (Figure 2).⁴

Inspiration: as intra-thoracic pressure falls on inspiration during spontaneous breathing, a transmural pressure gradient across the right atrial wall produces a transient decrease in right atrial

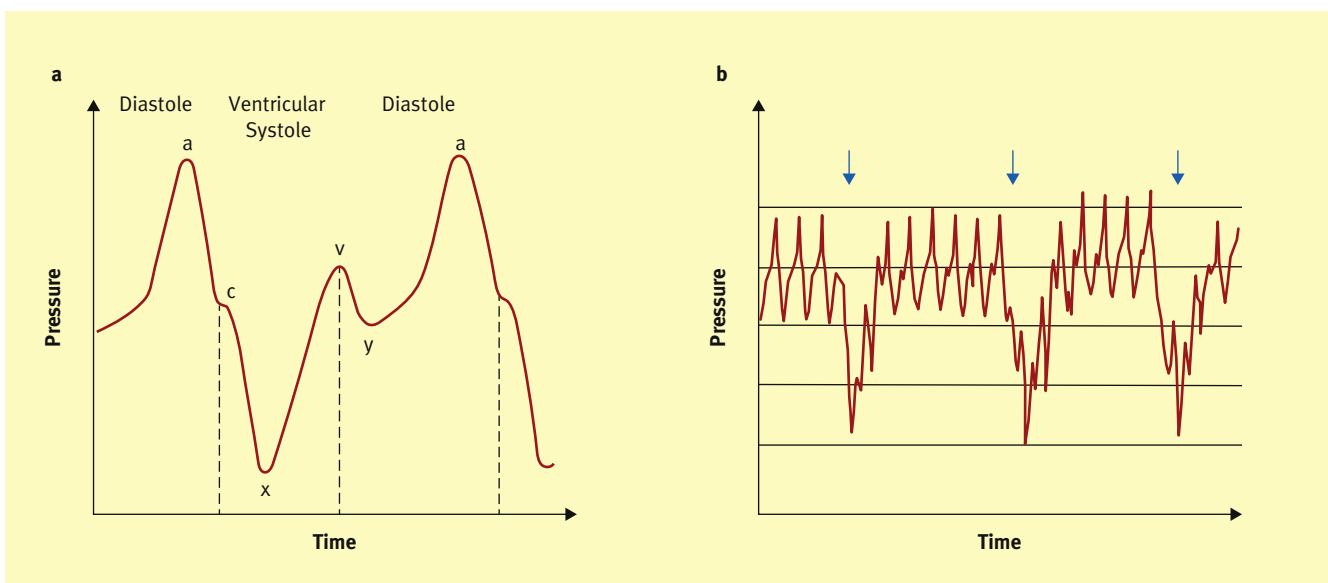


Figure 2 (a) The central venous waveform, showing the effects on right atrial pressure of atrial systole, a, early isovolumic ventricular contraction, c, tricuspid annular plane systolic excursion, x, diastolic ventricular filling, v, and opening of the tricuspid valve, y. (b) The central venous waveform, showing the decrease in right atrial pressure with inspiration (blue arrows).

Download English Version:

<https://daneshyari.com/en/article/2742290>

Download Persian Version:

<https://daneshyari.com/article/2742290>

[Daneshyari.com](https://daneshyari.com)