

The brain: functional divisions

Leo Donnelly

Abstract

The incompletely separated cerebral hemispheres consist of a thin outer folded cortex of grey matter containing organized neuronal cell bodies and interneurons. Some of the surface convolutions subservise particular sensory or motor functions. Incoming afferent and projected efferent fibres constitute the underlying white matter, which connects different parts of each hemisphere, the hemispheres to each other and (as the corona radiata) to subcortical nuclei, especially components of the deeply embedded diencephalon and the basal ganglia, and continuing between the latter as the internal capsule to and from the cerebellum and brainstem. Divisions of the diencephalon, the deeper part of the embryonic forebrain, include the epithalamus (pineal gland), the thalamus (connected extensively with the cortex), the subthalamus and the hypothalamus (involved in the autonomic nervous system, limbic system and neuro-endocrine system). The brainstem, consisting of the midbrain, pons and medulla, allows passage of many ascending and descending nerve fibre tracts between the brain and spinal cord, carrying sensory information from and allowing movement of the limbs and trunk. It is also the site of many of the cranial nerve nuclei, through which the brain innervates the head region. It houses the centres controlling vital aspects related to respiration, cardiovascular function and consciousness levels. The cerebellum also has a cortex of grey matter, tightly convoluted into folia, and containing layered neuronal cell bodies projecting laterally and, as underlying white matter, to a collection of deep nuclei. Fibres run to and from the cerebellar nuclei in a series of peduncles to the midbrain, pons and medulla, and allow the cerebellum to coordinate movement at an unconscious level.

Keywords basal ganglia; brain function; brainstem; cerebral hemispheres; physiology

Royal College of Anaesthetists CPD matrix: 1A01

The central nervous system (CNS) develops as a groove in the embryonic ectoderm, the edges of which fold over to enclose a neural tube during the fourth week of development. The closed forward or rostral end of this tube differentially expands into three primary vesicles and, by the seventh week of development, five secondary vesicles (Table 1). By convention, the midbrain, pons and medulla are known collectively as the brainstem. There is also an early delineation between dorsal and ventral cell groupings (the alar and basal plates, respectively) in the developing spinal cord and neighbouring (caudal) parts of the brain. Neurons developing in the alar plate have mainly sensory functions; those in the basal plate are mainly motor.

Leo Donnelly PhD is Associate Professor (Senior Lecturer) in Anatomy at Peninsula College of Medicine and Dentistry, Universities of Exeter and Plymouth, UK. Conflicts of interest: none declared.

Learning objectives

After reading this article you should have:

- a knowledge of the main divisions of the brain (telencephalon, diencephalon, brainstem and cerebellum), and the main pathways between these structures
- knowledge of the main functions of these regions, with particular reference to the perception of sensory information (including pain), the control of movement and regulation of autonomic functions
- a basic understanding of the histology of the brain tissues

Cerebral hemispheres

The human brain is dominated by the telencephalon, which expands to cover the diencephalon as the cerebral hemispheres. Their outer mantle of cortical grey matter (rich in neuronal cell bodies) varies between 1.5 and 4.5 mm in thickness, and develops an increased surface area by virtue of folds (gyri) separated by grooves (sulci), in the walls of which about 70% of the cortex is hidden. The cortex tends to be thicker on the crest of a gyrus than in the depths of a sulcus. It is technically very difficult to count the enormous number of cortical neuronal cell bodies, and estimates vary between 2.6×10^9 and 1.6×10^{10} . They project into and receive connections from the interior of the hemisphere, and many of these fibres are sheathed in fatty, insulating myelin, conferring a paler coloration (the white matter). Embedded within the white matter are the basal ganglia (caudate nucleus, putamen, globus pallidus, etc.) and the fibres pass around a system of ventricles containing cerebrospinal fluid. The cortex also contains 5.0×10^{11} ancillary neuroglial cells of various types, and dense capillary beds.

Microscopically, the cytoarchitecture of the cortex is found to have both a laminar and a columnar organization. Phylogenetically old parts of the cortex – the paleocortex of the uncus (concerned with olfaction and some limbic areas) and the archicortex of the hippocampus (concerned with memory) – have three or more laminae, while in the neocortex, which covers the remaining 90% of the brain, six cellular laminae (numbered from the outside in) can usually be discerned (Figure 1), especially in association areas. The three principal neuronal cell morphologies found in these layers are pyramidal, spiny stellate and smooth stellate cells.

The large pyramidal cells vary in height from 20 (in laminae II and III) to 60 μm (in lamina V), but also include the giant cells of Betz (80–100 μm) in the primary motor cortex. Their cell bodies are conical in shape with a single apical dendrite, which usually extends to lamina I, and several basal dendrites that extend laterally within the same lamina as the cell body. These dendrites branch freely and are decorated with spines. The axons of all pyramidal cells give rise to recurrent branches before leaving the cortex, which may excite neighbouring pyramidal cells (all pyramidal cells are excitatory, using glutamate or the closely-related aspartate as a neurotransmitter).

Spiny stellate cells also have spiny dendrites and are usually excitatory. Their cell bodies are restricted to lamina IV and receive most of the afferent input from the thalamus and from

Primary and secondary vesicles of the developing CNS

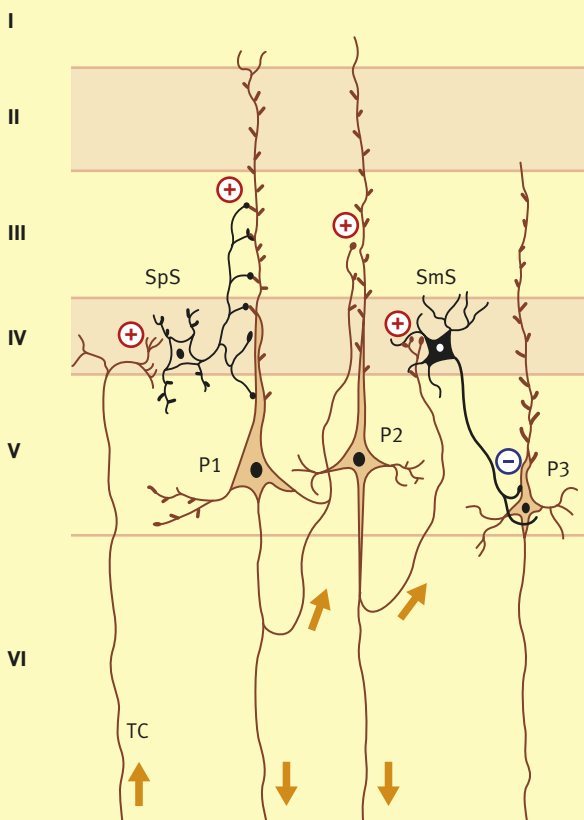
Primary vesicles	Secondary vesicles	Derivative(s)
Prosencephalon (forebrain)	Telencephalon Diencephalon	Cerebral hemispheres Thalamus (etc.)
Mesencephalon (midbrain)	Mesencephalon	Midbrain
Rhombencephalon (hindbrain)	Metencephalon Myelencephalon	Pons, cerebellum Medulla oblongata

Table 1

other areas of the cortex, and form glutamatergic synapses on pyramidal cells. Smooth stellate cells have dendrites lacking spines and their cell bodies are also restricted to lamina IV, where they receive some of the recurrent collateral branches of pyramidal cells and form inhibitory γ -aminobutyric acid (GABA) ergic synapses on other pyramidal cells.

Cells of the cortex are also arranged in 200–500 μm diameter, modality-specific columns, extending radially through all laminae. Such columns, also known as modules, are composed of about 100

Laminar arrangement of neocortex



A thalamocortical afferent (TC), three pyramidal cells (P1–3), and a spiny (SpS) and a smooth (SmS) stellate cell are shown

Figure 1

mini-columns (radial chains of neurons) and are the functional units of the cortex; they may be activated by specific afferents, whether thalamocortical, association or commissural (see below). Neocortical modules are established during fetal development, but establish synaptic connections postnatally and in response to external sensory stimuli (the so-called early critical period).

The cortical gyri and sulci are somewhat variable, even between the hemispheres, but some are constant enough to serve as anatomical landmarks. The sulci indent the surface of the hemispheres and are distinct from the much deeper longitudinal and lateral fissures. The hemispheres are separated by the longitudinal fissure, which accommodates a crescentic indentation of the dura mater – the falx cerebri – until it reaches the corpus callosum. Each hemisphere is also divided into four superficial lobes by the lateral fissure, the relatively constant and deep central sulcus, and two imaginary lines: an extrapolation of the lateral fissure until it meets a line extending from the parieto-occipital sulcus as it emerges from the medial surface onto the superior margin of the hemisphere (about 4 cm from the occipital pole), to the preoccipital notch on the inferior margin of the hemisphere. The lobes are named with regard to the bones of the skull that they more-or-less underlie: frontal, parietal, occipital and temporal. In addition, the lips (opercula) of the lateral fissure can be retracted to expose a fifth lobe, the insula, which remains bound to the underlying corpus striatum during development. The lateral fissure is formed by expansion of the surrounding cortex during development.

Frontal lobe: this lobe occupies the volume anterior to the central sulcus and, on the medial surface of the brain, an imaginary line drawn between the superior end of the central sulcus and the corpus callosum. Anterior to the central sulcus is the often incomplete precentral sulcus, delineating the precentral gyrus (Brodmann's area 4 – see below) which correlates functionally with the primary motor cortex. Within this portion of the cortex, afferent fibres project in a somatotopic fashion (often depicted as a distorted and inverted 'motor homunculus' – the head area occurring just above the lateral fissure and the lower limb on the medial surface of the hemisphere). The area of premotor cortex devoted to a particular part of the body is proportional to the number of neuronal cell bodies and efferent fibres associated with the body part, and therefore the degree of precision involved in its movement. Stimulation of a point on the primary motor cortex results in contraction of particular muscle groups on the contralateral side of the body.

The German anatomist Korbinian Brodmann published a cytoarchitectural map of 52 numbered areas in 1909, which has been superseded by functional studies. There remains, however, remarkably good correspondence between his areas and functional maps, and his numbering system is still in common use for descriptive purposes (Figure 2).

The premotor cortex occupies an area immediately anterior to and six times larger than the primary motor cortex, corresponding to that part of Brodmann's area 6 on the lateral surface of the frontal lobe. It receives input from other parts of the frontal lobe as well as a rich sensory input from Brodmann's area 7 of the parietal lobe. It is especially active in response to visual or somatic sensory cues (e.g. reaching for an object in full view, or identifying an object by touch alone). The premotor cortex is

Download English Version:

<https://daneshyari.com/en/article/2742382>

Download Persian Version:

<https://daneshyari.com/article/2742382>

[Daneshyari.com](https://daneshyari.com)