



Egyptian Society of Anesthesiologists
Egyptian Journal of Anaesthesia

www.elsevier.com/locate/egja
www.sciencedirect.com



Case report

Anesthetic management of a patient with bronchopleural fistula following blunt trauma chest: A brief report



Naveen Yadav ^{a,*}, Ajay Kumar ^a, Gyaninder Pal Singh ^b, Ira Balakrishnan ^a,
Richa Aggarwal ^b, Hemanshu Prabhakar ^b

^a Department of Anaesthesiology, All India Institute of Medical Sciences, India

^b Department of Neuroanaesthesiology, All India Institute of Medical Sciences, India

Received 14 March 2013; revised 27 September 2013; accepted 20 October 2013

Available online 19 November 2013

KEYWORDS

Bronchopleural fistula;
Double lumen tube

Abstract Blunt trauma to the chest resulting in rupture of a major bronchus is rare. These injuries are often fatal because of respiratory distress; difficulties in establishing an airway, and the high frequency of associated multiple organ injuries. We report the anesthetic and intensive care management of a patient with bronchopleural fistula following blunt chest injury and post-thoracotomy stump leak. This case was unique because of shearing of right main bronchus close to carina, such injuries are not only difficult to repair but also, double lumen tube was kept for more than 48 h to prevent reopening of the suture. Successful management of the case is described with brief review of the literature.

© 2013 Production and hosting by Elsevier B.V. on behalf of Egyptian Society of Anesthesiologists.
Open access under [CC BY-NC-ND license](#).

1. Introduction

Blunt chest trauma leading to rupture of a main bronchus is a rare entity with a high prehospital mortality [1]. Isolated bronchial tear without associated injury is rare. The incidence of bronchial rupture is low (0.03–2.5%) even in those with severe trauma and are on the rise with increasing number of road traffic accidents [2]. Patients with bronchial rupture reaching hospital alive have a 90% chance of survival and half of such patients may have no other injury. Here, we report the successful management of 19 days old near complete trans-section of right main bronchus with bronchopleural fistula with collapse of right lung. The site of injury was such that double lumen tube (DLT) was kept in postoperative for 48 h so that injury to the suture line could be prevented. There have been no

* Corresponding author. Address: Room No. 316, JPNATC, All India Institute of Medical Sciences, New Delhi 29, India. Tel.: +91 9868398614; fax: +91 26588641.

E-mail address: naveen.dv2@gmail.com (N. Yadav).

Peer review under responsibility of Egyptian Society of Anesthesiologists.



Production and hosting by Elsevier

reported cases where DLT has been used for such long time in tracheobronchial injuries because of the site of injury and associated inflammation.

2. Case report

A 15-year-old male, weighing 49 kg was brought to our emergency department of JPN Apex trauma centre of All India Institute of Medical Sciences, 19 days after an injury to the right side of his chest by the steering wheel of a tractor. Patient had complaints of pain over the right side of chest and breathlessness soon after the injury. He had no upper airway obstruction and there was no other associated injury. He was initially treated at a peripheral hospital, where intercostal drainage (ICD) was placed. He was then referred to a centre of specialized facilities, where on fiberoptic bronchoscopy near complete transection of right main bronchus with bronchopleural fistula was diagnosed. The right lung was collapsed. After further investigation and treatment, he was referred to our tertiary centre for further management.

The patient was conscious and co-operative with stable heart rate and blood pressure (pulse rate = 92 beats/min, BP = 120/76 mmHg). Respiratory rate was 19 breaths per minute and peripheral oxygen saturation was 92–97% on room air. On auscultation, air entry was absent on the right side of the chest. There was collection of 250 ml of straw colored fluid in the right ICD. Chest compression test was negative. There were no other associated injuries. Arterial blood gas (ABG) values on room air were within normal limits (pH = 7.46, PCO_2 = 37, PO_2 = 70, HCO_3^- = 26.8, BE = 2.5). Chest radiograph and Computed Tomography (CT) Scan showed right sided pneumothorax with collapsed lung, absent bronchopulmonary markings with ICD in situ (Fig. 1).

Patient was planned for elective thoracotomy under general anesthesia because of massive air leak through bronchopleural fistula. In the operating room, routine monitors were attached and an epidural catheter was placed at T12-L1 level in the sitting position. Epidural infusion of bupivacaine was started. Routine anesthesia induction with fentanyl, propofol and rocuronium was done. Trachea was intubated using 32 Fr left-sided DLT. The position of the tube was confirmed by fiberoptic bronchoscopy (Fujifilm outer diameter 2.8 mm). Anesthesia was maintained with isoflurane in a mixture of oxygen and nitrous oxide (1:2), fentanyl and vecuronium. Patient was positioned in left lateral position and ICD was removed. Thoracotomy was done using a J-shaped incision in the 5th intercostals space. Intraoperative, decision for pneumonec-tomy was taken as there was severe contusion and collapse of right lung and the margin of the transected right main bronchus was sloughed and unrepairable. Pulmonary vein and artery were clamped and tied separately and right bronchus was cut and sutured. The absence of leak at suture site was confirmed by applying positive pressure ventilation up to 40 cm H_2O . A new ICD was placed in the 6th intercostal space and wound closed in layers. Intraoperative course was uneventful. At the end of surgery, patient was shifted to intensive care unit (ICU). Elective ventilation with DLT in situ was planned in the postoperative period. Any plan to change the DLT with single lumen tube could have resulted in injury and reopening of the repaired stump. At the same time, the po-

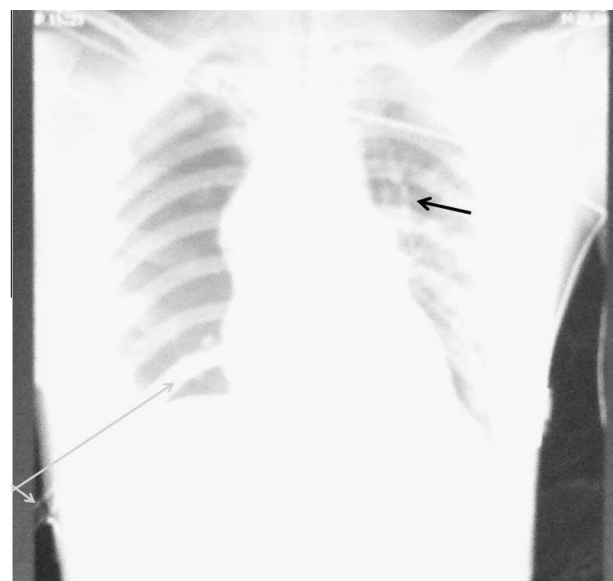


Figure 1 CX Ray showing right side pneumothorax with collapse of right lung. Broncho-pulmonary markings are present only in the left lung field (white arrow) not seen on the right side. Grey arrow shows the ICD in situ on the right side.

sitive pressure ventilation through single lumen tracheal tube could have opened the suture line. In the ICU, patient received sedation and analgesia with midazolam and fentanyl along with epidural analgesia. Patient was mechanically ventilated using pressure controlled mode (PCV) with following ventilatory settings: Peak inspiratory pressure of 20 cm H_2O , Respiratory rate 20 breaths/min, I:E ratio 1:2 and positive end expiratory pressure (PEEP) of 3 cm H_2O .

Four hours later in the ICU, the stump leaked due to malposition of the DLT, (Fig. 2) leading to difficulty in ventilation. The tube was repositioned with fiberoptic bronchoscope in ICU and the patient re-operated to repair the site of leak. Right thorax was opened through the same incision and major air leak was detected from right main bronchus, which was then secured. After the surgery, patient was again shifted to ICU with DLT in situ and this time patient was kept paralyzed with vecuronium infusion at 3 mg/h for next 48 h.

After two days, DLT was changed with 6 mm portex endotracheal tube using fiberoptic bronchoscope with due care not to injure the stump. The patient was electively ventilated for the next one day. On the third postoperative day, patient was weaned off the ventilator and later tracheally extubated. Further course in the hospital was uneventful and patient was discharged home on 14th day.

3. Discussion

Bronchial rupture usually results from high-speed motor vehicle accident, and it can also be caused by crushing or twisting injuries or a fall from a height. In a review of 265 patients with tracheobronchial injury by Kiser et al., motor vehicle accidents were found to be the most common (59%) cause of injury [3]. Bronchial rupture in children secondary to blunt trauma occurs most commonly in the adolescent age group and is more

Download English Version:

<https://daneshyari.com/en/article/2756328>

Download Persian Version:

<https://daneshyari.com/article/2756328>

[Daneshyari.com](https://daneshyari.com)