


Available online at www.sciencedirect.com

ScienceDirect

journal homepage: www.elsevier.com/locate/ijnt

Case Report

An unusual penetrating transorbital craniocerebral injury

O.P. Gupta^{a,*}, K. Roy^b, S. Ghosh^c, P. Tripathy^d^a Resident, Department of Neurosurgery, N.R.S. Medical College, Kolkata, West Bengal, India^b Assistant Professor, Department of Neurosurgery, N.R.S. Medical College, Kolkata, West Bengal, India^c Professor, Department of Neurosurgery, N.R.S. Medical College, Kolkata, West Bengal, India^d Professor and Head, Department of Neurosurgery, N.R.S. Medical College, Kolkata, West Bengal, India

ARTICLE INFO

Article history:

Received 14 November 2013

Accepted 2 December 2013

Available online xxx

Keywords:

Penetrating

Transorbital

Craniocerebral injury

Pressure regulator valve injury

ABSTRACT

Penetrating injury of skull and brain are relatively uncommon injuries representing about 0.4% of all head injuries. We are reporting a case of penetrating transorbital craniocerebral injury due to domestic appliance. A 47 year middle aged female sustained penetrating orbitocerebral injury when malfunctioned pressure cooker exploded during cooking. The CT scan shows the metallic foreign body inside the left orbit resembling pressure regulator valve of pressure cooker with fracture of orbital wall and basifrontal contusion. Patient was operated. Removal of the foreign body with evisceration of left eye was done. Postoperative complication dealt successfully and patient recovers fully.

In literature transorbital craniocerebral injury with variety of unusual object are reported like bicycle brakes, chop stick, metal bar, hunting arrow, ceramic stone but due to pressure regulator valve of malfunctioned domestic appliance is not reported so far and this may be first case of such a rare type of mode of injury.

Copyright © 2013, Neurotrauma Society of India. All rights reserved.

1. Introduction

Accidental penetrating injuries of brain are relatively uncommon mode of injury. Here we are presenting a case of transorbital craniocerebral penetrating head injury and its postoperative complication due to pressure regulator valve of a pressure cooker that struck through left orbit when pressure cooker explodes during cooking. We have not found such type of mode of injury in literature so far. The pertinent literature is reviewed and management is discussed.

2. Case report

A 47 year old lady sustained penetrating head injuries while cooking due to explosion of malfunctioned pressure cooker. On examination the patient is in altered sensorium with GCS score 13/15 and there is lacerated wound over left forehead and along with penetrating injury of left eye. The left eye ball was damaged with complete loss of vision and right eye was normal.

Digital X-ray of skull (Fig. 1) shows metallic foreign body looks like pressure cooker regulator valve of pressure cooker

* Corresponding author.

E-mail addresses: gupta.dromprakash@gmail.com, jkumar0411@gmail.com (O.P. Gupta).

0973-0508/\$ – see front matter Copyright © 2013, Neurotrauma Society of India. All rights reserved.

<http://dx.doi.org/10.1016/j.ijnt.2013.12.001>

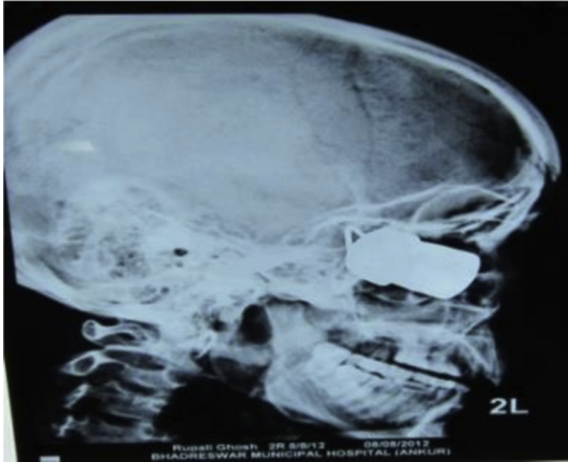

Fig. 1 – Skull showing metallic foreign body inside left orbit.

(Fig. 2) inside the left orbit with fracture of frontal bone including left orbital roof.

The CT scan of brain (Fig. 3a–d) shows metallic foreign body inside left orbit with basifrontal contusion with pneumocephalus and there is fracture of left orbital wall and frontal sinus.

She was operated by multidisciplinary approach, evisceration of left eye with removal of foreign body was done. Postoperative period was uneventful and patient has been discharged home.

After one month of discharge she came to hospital with complaints of multiple episodes of convulsion for last 10 days associated with intermittent high grade fever, headache, vomiting and progressive behavioral changes. On examination GCS was 14/15, febrile, no nuchal rigidity, and hemogram of the patient shows total count 15,000/mm³, neutrophil count 80%, ESR was raised, blood culture was negative, C-reactive protein level was raised.

The MRI of brain (Fig. 4a, b) shows about 4 × 3 × 4 cm of size, ring enhancing lesion at left basifrontal region with perilesional edema and mass effect suggestive of intraparenchymal abscess. Total excision of abscess was done. Postoperative period are uneventful and patients improved symptomatically with no neurological deficit.



Fig. 2 – Pressure cooker with pressure regulating valve on the top.

3. Discussion

Penetrating injury of the skull and brain are relatively uncommon injury, representing about 0.4% of all head injury.¹ The bony calvaria of adult provide effective barrier and protects the brain against penetrating injury.² Orbitocranial injuries caused by high-speed projectile foreign bodies are quite unusual events and can be the result of numerous unintentional events with variety of objects including bicycle brake,³ chop stick,⁴ metal bar,⁵ hunting arrow,⁶ ceramic stone.⁷

In review of literature we have not found penetrating transorbital craniocerebral injury due to pressure regulator valve of a malfunctioned pressure cooker so far.

The pathophysiological consequences of penetrating head injury depend upon kinetic energy and trajectory of object through brain. High energy ballistic like gun shot injury causes permanent cavitation with surrounding ischemic ring and hemorrhage⁸ and we believe that in our case it was like high velocity type of injury that occurs after explosion of pressure cooker.

When there is a suspicion of transorbital penetration, the clinical examination must be supplemented by orbital and cerebral CT scan with both axial and coronal sections of the orbit with three dimensional reconstruction to defines the entry site, trajectory of the foreign body, fragments inside the brain, involvement of paranasal sinuses, orbits, skull base, mastoid, intracranial bleed, brain edema and pneumocephalus. Involvement of paranasal sinuses and mastoid air cells are susceptible to leakage of cerebrospinal fluid and deep intracranial infection.⁹

The initial treatment of penetrating head injury includes aims to immediately save the life by control of persistent bleeding and intracranial hypertension. Surgical management includes debridement of devitalized brain tissue, removal of foreign body, bone fragments, watertight closure of duramater, repair of skull base and closure of scalp.¹⁰ In complex orbitofaciocranial injuries with exposed air sinuses a multidisciplinary approach is necessary to prevent postoperative infection¹¹ by preserving the integrity of basal dura in the region of orbit, mastoid air cells, and air sinuses. In our case after resuscitation of patients we have done evisceration of damaged eye, hemostasis of wound and retrieval of foreign body to save the life of the patient.

Currently surgical management of these lesions tend towards minimizing the degree of debridement, preserving as much as possible of cerebral tissue, and removing the bone fragment and foreign body if easily accessible. In the presented case though there was fracture of orbital roof no bony fragment was found inside the brain.

Infectious complication following penetrating head injury is well known entity. The incidence of traumatic brain abscess in civilian population range from 2.5% to 10.9% of total brain abscess.¹² Meningitis, abscess or empyema can appear days, weeks, or month after the trauma.¹³

They usually occur due to retained bone fragment or contamination of initially uninfected injury sites with bacteria from skin, clothes, environment and CSF leak. In post traumatic brain abscess excision of abscess is useful in patients

Download English Version:

<https://daneshyari.com/en/article/2757125>

Download Persian Version:

<https://daneshyari.com/article/2757125>

[Daneshyari.com](https://daneshyari.com)