

# Lung Ultrasonography and Pediatric Cardiac Surgery: First Experience With a New Tool for Postoperative Lung Complications

Vincenzo Vitale, MD, Zaccaria Ricci, MD, and Paola Cogo, MD, PhD

Pediatric Cardiac Intensive Care Unit, Bambino Gesù Hospital, Rome, Italy

Lung ultrasonography is a diagnostic tool increasingly used in critical care. Few data are available for the pediatric population. We describe our experience with lung ultrasonography for 5 pediatric patients with common post-cardiac surgery lung complications (pleural effusion, pneumothorax, atelectasis, pneumonia). Ultrasonography was useful also for lung recruitment. Such data were confirmed by chest radiographs or by computed tomography, or both.

Lung ultrasonography can be considered as a useful, real-time, bedside tool to detect specific lung diseases, reliably implementing radiographic images and potentially decreasing the total number of radiographs in critically ill children with congenital heart diseases.

(Ann Thorac Surg 2014;97:e121–4)

© 2014 by The Society of Thoracic Surgeons

Lung ultrasonography (LUS) is a diagnostic tool increasingly used in critical care, emergency medicine, and trauma surgery [1]. Few data are available concerning the pediatric and neonatal population [2]. So far, no reports have been published about the use of LUS in the pediatric cardiac intensive care unit.

## Technique

In the last year, LUS has been introduced in our institution as a diagnostic tool, in addition to chest radiograph examinations. In the present report, we retrospectively describe 5 pediatric cardiac patients who had postoperative lung complications. The LUS was performed in all patients with the NanoMaxx ultrasound system (SonoSite, Bothell, WA), using a linear probe 6 to 13 Mhz. Right and left lung apex and right and left lung bases were examined by ultrasonography, avoiding drainage insertion points and sternal wound to prevent the risk of surgical wound infection. The study sonologist was a pediatric cardiac intensivist trained in chest ultrasonography. A chest radiograph was always considered necessary to confirm the ultrasound findings in this pilot series of examined patients in the postoperative phase. Institutional Review Board approval was granted, and informed consent was waived owing to the retrospective nature of the case descriptions.

The first patient was a 2-year-old girl, weighing 20 kg, who had dyspnea associated with right lung hypophonesis on postoperative day 2 after Fontan operation. Signs of pleural effusion were identified by ultrasonography, and chest radiograph showed total right lung

opacity (Fig 1, case 1). A chest tube was positioned, and the pleural effusion was promptly resolved.

The second patient was a 30-day-old infant, weighing 3.2 kg, affected by pulmonary atresia with intact ventricular septum who underwent outflow patch and Blalock-Taussig shunt operation, who showed on postoperative day 1 clinical signs of left pneumothorax. The LUS clearly showed signs of pneumothorax: abolition of lung sliding, stratosphere sign, lung point, and absence of B lines. Chest radiograph confirmed lung collapse. A chest tube was placed, and clinical signs of pneumothorax disappeared (Fig 1, case 2).

A 15-day-old neonate, weighing 2.5 kg, affected by aortic arch hypoplasia, left ventricle hypoplasia, ventricular septal defect, and parachute mitral valve, underwent Norwood operation. During his postoperative course, the neonate had right lung pneumonia: ultrasonography showed a typical right lung shredded pattern, as a sign of pneumonia (Fig 1, case 3). Chest radiograph showed diffuse infiltrations; a bronchoalveolar lavage was performed, and *Escherichia coli* colonies grew. Antibiotic therapy was prescribed, and the pneumonia resolved.

A 5-month-old male infant, weighing 4.5 kg, affected by heterotaxia, complete atrioventricular canal with hypoplastic left ventricle, and aortic atresia who had undergone a hybrid palliation (pulmonary arteries banding and ductus arteriosus stenting) at birth, was newly admitted to our pediatric cardiac intensive care unit after 4 months for severe congestive heart failure and respiratory failure. The chest radiograph at admission and a subsequent computed tomography scan showed cardiomegaly with severe compression of the right bronchus and complete right lung atelectasis (Fig 2, case 4 before operation). Ultrasonography of the right pulmonary apex was performed and confirmed right lung atelectasis with pulsatility of the right atrium on pulmonary parenchyma: lung pulse. A right aortic arch reconstruction, atrioventricular valve plasty, and Blalock-Taussig shunt were performed to improve cardiac

Accepted for publication Jan 17, 2014.

Address correspondence to Dr Vitale, Pediatric Cardiac Intensive Care Unit, Bambino Gesù Hospital, Piazza S. Onofrio 5, Rome 00165, Italy; e-mail: [vincenzo.vitale@opbg.net](mailto:vincenzo.vitale@opbg.net).

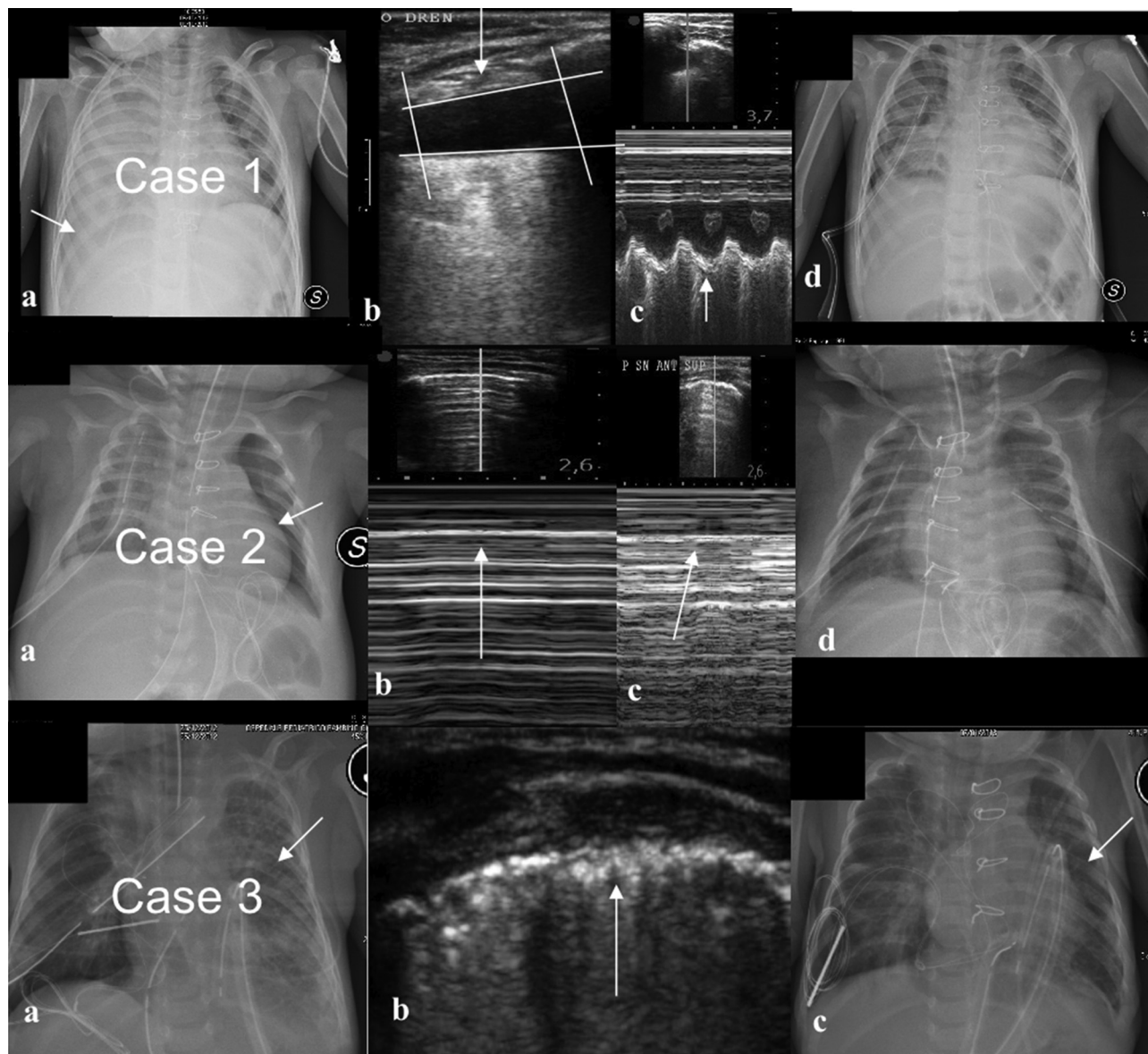


Fig 1. Case 1: (a) pleural effusion as seen on chest radiograph; (b) the quad sign; (c) the sinusoid sign by M-mode; and (d) chest radiograph after pleural drainage. Case 2: (a) pneumothorax as seen on chest radiograph; (b) in M-mode, arrows show the stratosphere sign (collapsed lung); (c) the lung point that highlights the passage from normal lung (seashore sign) to collapsed lung (stratosphere sign); and (d) chest radiograph after pleural drainage. Case 3: (a) the lung consolidation clearly shown by the radiograph; (b) the shredded pattern by lung ultrasonography; and (c) chest radiograph that shows lung after antibiotic therapy.

performance and to reduce bronchus compression. Despite this peculiar and complex anatomic pattern, LUS was able to show the resolution of right pulmonary atelectasis. Chest radiographs and a computed tomography scan confirmed these data thereafter (Fig 2, case 4 after operation).

The fifth patient was a 4-year-old girl, weighing 20 kg. She was affected by congenital aortic sinotubular junction stenosis and underwent an aortoplasty operation. On postoperative day 1, after extubation, a chest radiograph revealed right atelectasis and right pleural effusion (Fig 2, case 5a). Diuretic therapy was increased and noninvasive ventilation applied. The LUS showed absence of lung parenchyma on the right costodiaphragmatic sinus

(Fig 2, case 5b). When lung recruitment was achieved by noninvasive ventilation, ultrasonography allowed tracking the reeration of lung parenchyma (Fig 2, case 5 right lung reeration). We utilized LUS to monitor the right lung condition, and after 12 hours, a chest radiograph confirmed that the right atelectasis and pleural effusion had completely resolved (Fig 2, case 5c).

## Comment

Lung ultrasonography is based on a standardized method and reproducible signs that have been recently described in critically ill newborns [3]. To our knowledge, this is the

Download English Version:

<https://daneshyari.com/en/article/2873582>

Download Persian Version:

<https://daneshyari.com/article/2873582>

[Daneshyari.com](https://daneshyari.com)